A 16-year-old boy is brought to the emergency department after an eye injury during a baseball game. He was batting for his high school team when the opposing pitcher made a wild throw and the baseball hit him in the right eye. The patient has since been having diplopia that worsens when he looks up. On physical examination, he has mild periorbital ecchymosis, enophthalmos, and limited vertical movement of the right eye. Visual acuity and left eye examination are normal. CT scan of the head reveals an orbital floor fracture. Which of the following additional findings is most likely to be seen in this patient?

A. Absent right corneal reflex

B. Bruising over the mastoid process

C. Impaired olfaction

D. Inability to puff out right cheek

E. Reduced sensation over right upper lip

Submit

1 2 3 4 5 6 7 8 9 10 11 12 13 14 15 16 17 18 19 20 21 22 23 24 25 26 27 28 29 30 31

A 16-year-old boy is brought to the emergency department after an eye injury during a baseball game. He was batting for his high school team when the opposing pitcher made a wild throw and the baseball hit him in the right eye. The patient has since been having diplopia that worsens when he looks up. On physical examination, he has mild periorbital ecchymosis, enophthalmos, and limited vertical movement of the right eye. Visual acuity and left eye examination are normal. CT scan of the head reveals an orbital floor fracture. Which of the following additional findings is most likely to be seen in this patient?

A. Absent right corneal reflex (27%)

B. Bruising over the mastoid process (10%)

C. Impaired olfaction (11%)

D. Inability to puff out right cheek (9%)

✓ E. Reduced sensation over right upper lip (41%)

Omitted
Correct answer
E

41%
Answered correctly

02 secs
Time Spent

06/02/2020
Last Updated

Explanation



1
2
3
4
5
6
7
8
9
10
11
12
13
14
15
16
17
18
19
20
21
22
23
24
25
26
27
28
29
30
31

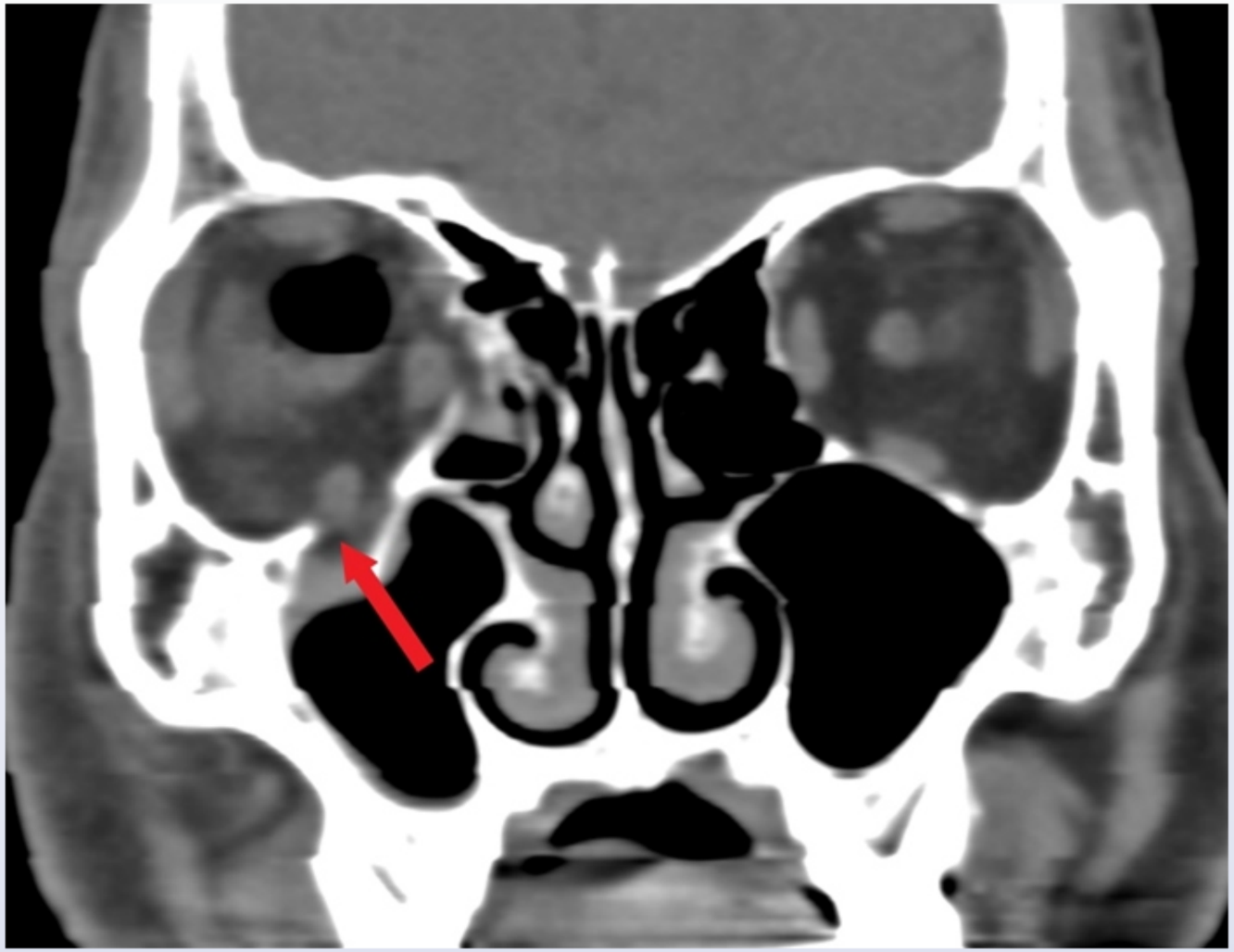

Fractures to the **orbital floor**, which is composed of the zygomatic bone and maxilla, most commonly result from direct frontal trauma to the orbit due to assault, motor vehicle crashes, or sports injuries. The **infraorbital nerve** (continuation of the maxillary nerve) runs along the orbital surface of the maxilla in the infraorbital groove before traversing the infraorbital canal and exiting the skull via the infraorbital foramen (just below the orbit). Damage can result in numbness and paresthesia of the **upper cheek, upper lip**, and **upper gingiva**. In addition, displacement of the

Fractures to the **orbital floor**, which is composed of the zygomatic bone and maxilla, most commonly result from direct frontal trauma to the orbit due to assault, motor vehicle crashes, or sports injuries. The **infraorbital nerve** (continuation of the maxillary nerve) runs along the orbital surface of the maxilla in the infraorbital groove before traversing the infraorbital canal and exiting the skull via the infraorbital foramen (just below the orbit). Damage can result in numbness and paresthesia of the **upper cheek, upper lip**, and **upper gingiva**. In addition, displacement of the orbital contents through the floor may cause enophthalmos, and entrapment of the inferior rectus muscle (as seen in above CT) can impair vertical gaze.

(Choice A) The corneal reflex involves cranial nerves V_1 (sensory) and VII (motor) and processing in the pons. It can be impaired by trauma to the superior orbital fissure because cranial nerves III, IV, V, and VI pass through this structure.

(Choice B) Hematomas over the mastoid process (Battle sign), along with periorbital ecchymosis and clear otorrhea, are signs of basilar skull fractures.

(Choice C) Nasal fractures or high force trauma to the midface can result in loss of smell if the olfactory nerves are torn from the cribriform plate in the ethmoid bone.

(Choice D) The facial nerve (cranial nerve VII) controls the motor function of the face and can be impaired in fractures of the temporal bone after lateral head trauma or zygomatic orbit fractures.

Educational objective:
Fractures to the orbital floor commonly result from direct frontal trauma to the orbit. The infraorbital nerve runs along the orbital floor in a groove in the maxilla before exiting the skull just inferior to the orbit. Damage can result in paresthesia of the upper cheek, upper lip, and upper gingiva. In addition, the inferior rectus muscle can also become entrapped, limiting vertical gaze.

References

- Orbital fractures: a review.
- Pediatric orbital fractures.

Anatomy	Nervous System	Orbital fracture
Subject	System	Topic

Copyright © UWorld. All rights reserved.

Fractures to the **orbital floor**, which is composed of the zygomatic bone and maxilla, most commonly result from direct frontal trauma to the orbit due to assault, motor vehicle crashes, or sports injuries. The **infraorbital nerve** (continuation of the maxillary nerve) runs along the orbital surface of the maxilla in the infraorbital groove before traversing the infraorbital canal and exiting the skull via the infraorbital foramen (just below the orbit). Damage can result in numbness and paresthesia of the **upper cheek, upper lip**, and **upper gingiva**. In addition, displacement of the orbital contents through the floor may cause enophthalmos, and entrapment of the inferior rectus muscle (as seen in above CT) can impair vertical gaze.

(Choice A) The corneal reflex involves cranial nerves V_1 (sensory) and VII (motor) and processing in the pons. It can be impaired by trauma to the superior orbital fissure because cranial nerves III, IV, V, and VI pass through this structure.

(Choice B) Hematomas over the mastoid process (Battle sign), along with periorbital ecchymosis and clear otorrhea, are signs of basilar skull fractures.

(Choice C) Nasal fractures or high force trauma to the midface can result in loss of smell if the olfactory nerves are torn from the cribriform plate in the ethmoid bone.

(Choice D) The facial nerve (cranial nerve VII) controls the motor function of the face and can be impaired in fractures of the temporal bone after lateral head trauma or zygomatic orbit fractures.

Educational objective:
Fractures to the orbital floor commonly result from direct frontal trauma to the orbit. The infraorbital nerve runs along the orbital floor in a groove in the maxilla before exiting the skull just inferior to the orbit. Damage can result in paresthesia of the upper cheek, upper lip, and upper gingiva. In addition, the inferior rectus muscle can also become entrapped, limiting vertical gaze.

References

- Orbital fractures: a review.
- Pediatric orbital fractures.

Anatomy	Nervous System	Orbital fracture
Subject	System	Topic

Copyright © UWorld. All rights reserved.

Fractures to the **orbital floor**, which is composed of the zygomatic bone and maxilla, most commonly result from direct frontal trauma to the orbit

Exhibit Display

Mastoid or periauricular hematomas (Battle sign)

Zoom In | Zoom Out | Reset | Add To New Card | Existing Card

Copyright © UWorld. All rights reserved.

Fractures to the **orbital floor**, which is composed of the zygomatic bone and maxilla, most commonly result from direct frontal trauma to the orbit

Exhibit Display

Foramina of the cranial base

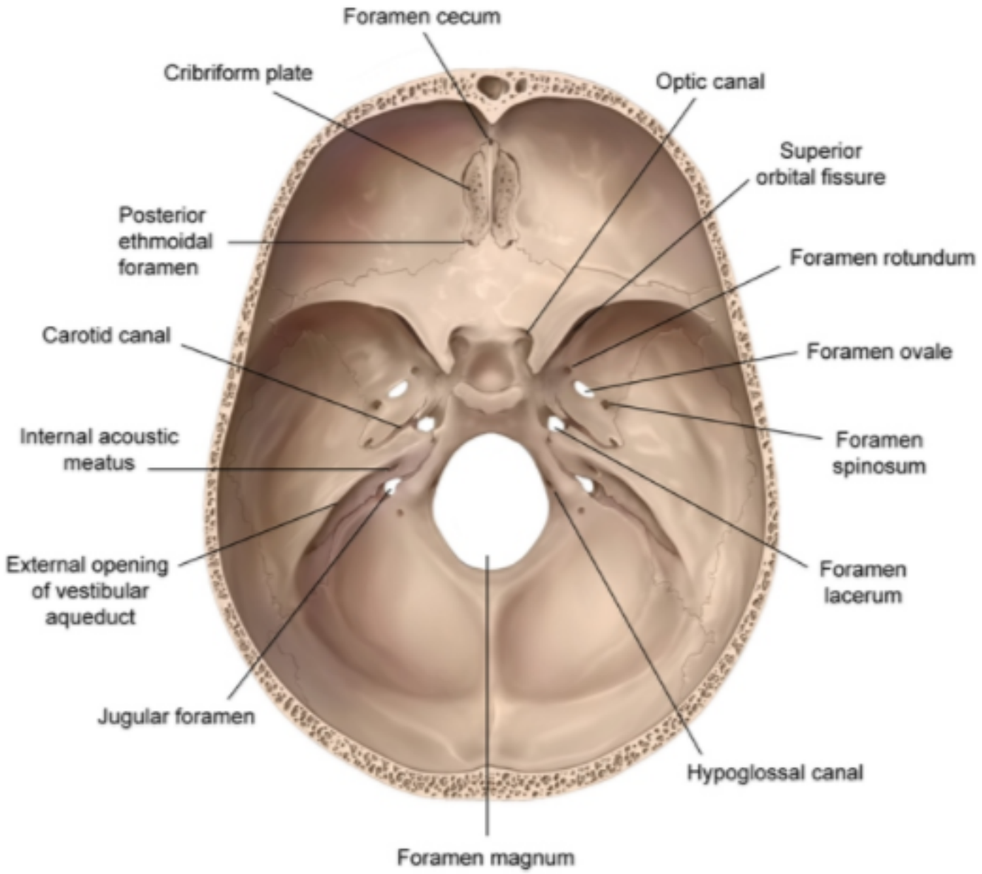

©UWorld

Zoom In | Zoom Out | Reset | Add To New Card | Existing Card

Copyright © UWorld. All rights reserved.

A 26-year-old previously healthy man is brought to the emergency department following a motorbike accident. He is found to have a maxillofacial injury. His condition is stabilized, and surgical repair is performed. While recovering, the patient develops difficulty chewing food. On examination, the jaw deviates to the right side when the patient is instructed to open his mouth. The nerve that has been injured in this patient exits the skull through which of the following foramina?

- A. Foramen lacerum
- B. Foramen ovale
- C. Foramen rotundum
- D. Foramen spinosum
- E. Jugular foramen

Submit

A 26-year-old previously healthy man is brought to the emergency department following a motorbike accident. He is found to have a maxillofacial injury. His condition is stabilized, and surgical repair is performed. While recovering, the patient develops difficulty chewing food. On examination, the jaw deviates to the right side when the patient is instructed to open his mouth. The nerve that has been injured in this patient exits the skull through which of the following foramina?

- A. Foramen lacerum (2%)
- ✓ B. Foramen ovale (62%)
- C. Foramen rotundum (21%)
- D. Foramen spinosum (8%)
- E. Jugular foramen (5%)

Omitted
Correct answer
B

62%
Answered correctly

02 secs
Time Spent

04/04/2020
Last Updated

Explanation

	Skull foramen	Traversing structures
Anterior cranial fossa	Cribriform plate	CN I olfactory bundles

	Skull foramen	Traversing structures
Anterior cranial fossa	Cribriform plate	CN I olfactory bundles
Middle cranial fossa	Optic canal	CN II, ophthalmic artery, central retinal vein
	Superior orbital fissure	CN III, IV, V_1, VI, ophthalmic vein, sympathetic fibers
	Foramen rotundum	CN V_2 (maxillary)
	Foramen ovale	CN V_3 (mandibular)
	Foramen spinosum	Middle meningeal artery & vein
Posterior cranial fossa	Internal acoustic meatus	CN VII, VIII
	Jugular foramen	CN IX, X, XI, jugular vein
	Hypoglossal canal	CN XII
	Foramen magnum	Spinal roots of CN XI, brain stem, vertebral arteries

CN = cranial nerve.

©UWorld

This patient has symptoms consistent with injury of the **third division of the trigeminal nerve** (cranial nerve [CN] V3, mandibular nerve), which provides sensory innervation to the face and motor innervation to the muscles of mastication. These include the 3 muscles that close the jaw (masseter, medial pterygoid, temporalis) and the single muscle that opens the jaw (lateral pterygoid).

Unilateral injury to CN V3 will result in unopposed action of the **contralateral** pterygoid muscles; because of the plane of action of these muscles, this leads to deviation of the mandible **toward** the paralyzed side on opening the mouth. Bilateral paralysis would cause mandibular drop and lack of jaw movement. CN V3 exits the skull through the foramen ovale, which also contains the lesser petrosal nerve, the accessory meningeal artery, and the emissary veins.

The **second division** of the trigeminal nerve (CN V2, maxillary nerve) exits the skull via the **foramen rotundum (Choice C)**. The foramen spinosum contains the middle meningeal artery, middle meningeal vein, and the meningeal (recurrent) branch of CN V3, which supplies the dura and contains sympathetic fibers **(Choice D)**. The **first branch** of the trigeminal nerve (CN V1, ophthalmic nerve) passes through the **superior orbital fissure**.

(Choice A) The foramen lacerum contains only a few small vessels (meningeal branch of ascending pharyngeal artery, emissary veins) and is otherwise occluded by fibrous tissue and cartilage. The internal carotid artery passes along its superior surface but does not traverse it.

(Choice E) The jugular foramen contains CNs IX, X, and XI; the inferior petrosal and sigmoid sinuses; and the posterior meningeal artery.

Educational objective:
The third (mandibular) branch of the trigeminal nerve exits the skull through the foramen ovale and innervates the muscles of mastication, including the masseter, the medial and lateral pterygoids, and the temporalis muscles.

Anatomy	Nervous System	Trigeminal nerve
Subject	System	Topic

Copyright © UWorld. All rights reserved.

1
2
3
4
5
6
7
8
9
10
11
12
13
14
15
16
17
18
19
20
21
22
23
24
25
26
27
28
29
30
31

Exhibit Display

Foramina of the cranial base

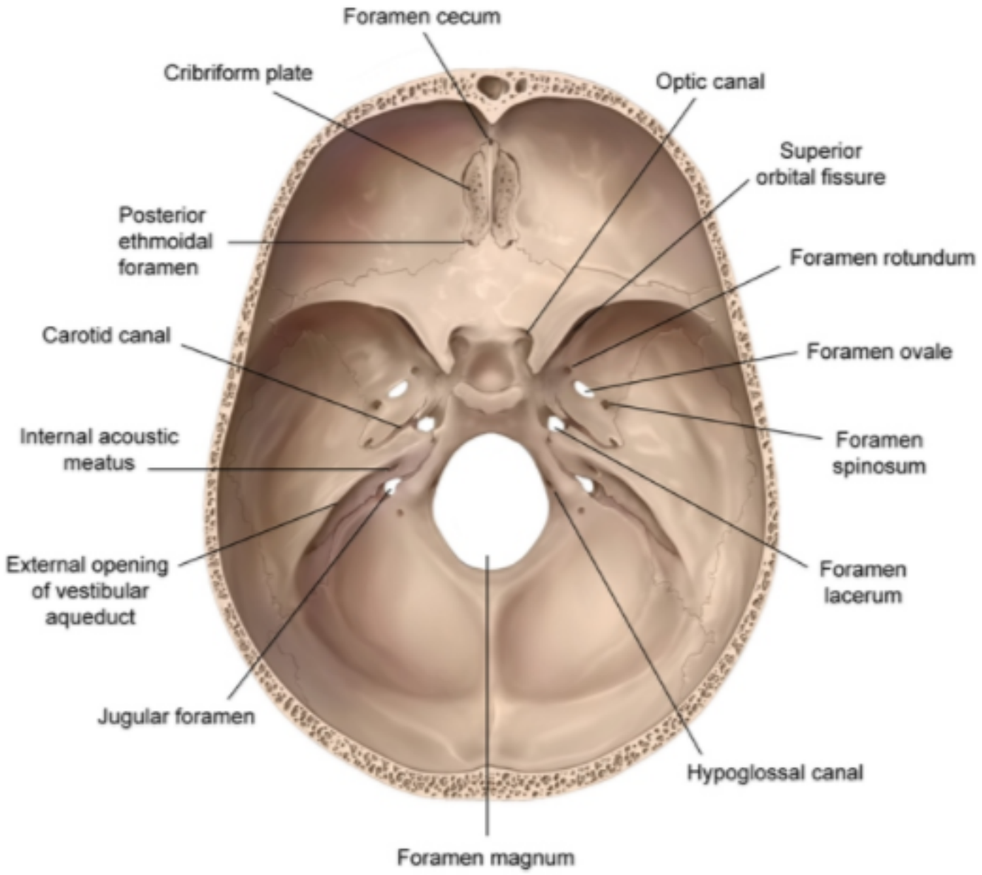

©UWorld

Zoom In | Zoom Out | Reset | Add To New Card | Existing Card

A 30-year-old man comes to the emergency department with severe headache and neck pain following a motor vehicle collision. The patient has no blurry or double vision, dizziness, slurred speech, numbness, or weakness. Neuroimaging is unremarkable except for evidence of a right transverse foramina fracture at the level of C2. The patient is placed in a cervical collar and admitted for further evaluation. While in the hospital, he suddenly develops dizziness, right facial numbness, and hoarseness. Temperature is 36.7 C (98 F), blood pressure is 160/90 mm Hg, pulse is 80/min, and respirations are 12/min. Neurologic examination shows partial ptosis and miosis of the right eye, as well as nystagmus. Hearing is intact bilaterally. There is reduced sensation to pain and temperature on the right side of the face and the left side of the body. The patient is ataxic and displays past-pointing with his right hand on finger-to-nose testing. Vascular imaging will most likely reveal an acute dissection in which of the following arteries?

- A. Basilar
- B. Common carotid
- C. Internal carotid
- D. Middle cerebral
- E. Posterior cerebral
- F. Vertebral

Submit

A 30-year-old man comes to the emergency department with severe headache and neck pain following a motor vehicle collision. The patient has no blurry or double vision, dizziness, slurred speech, numbness, or weakness. Neuroimaging is unremarkable except for evidence of a right transverse foramina fracture at the level of C2. The patient is placed in a cervical collar and admitted for further evaluation. While in the hospital, he suddenly develops dizziness, right facial numbness, and hoarseness. Temperature is 36.7 C (98 F), blood pressure is 160/90 mm Hg, pulse is 80/min, and respirations are 12/min. Neurologic examination shows partial ptosis and miosis of the right eye, as well as nystagmus. Hearing is intact bilaterally. There is reduced sensation to pain and temperature on the right side of the face and the left side of the body. The patient is ataxic and displays past-pointing with his right hand on finger-to-nose testing. Vascular imaging will most likely reveal an acute dissection in which of the following arteries?

- A. Basilar (17%)
- B. Common carotid (1%)
- C. Internal carotid (8%)
- D. Middle cerebral (7%)
- E. Posterior cerebral (14%)
- ✓ F. Vertebral (49%)

Omitted
Correct answer
F

49%
Answered correctly

02 secs
Time Spent

02/19/2020
Last Updated

Explanation

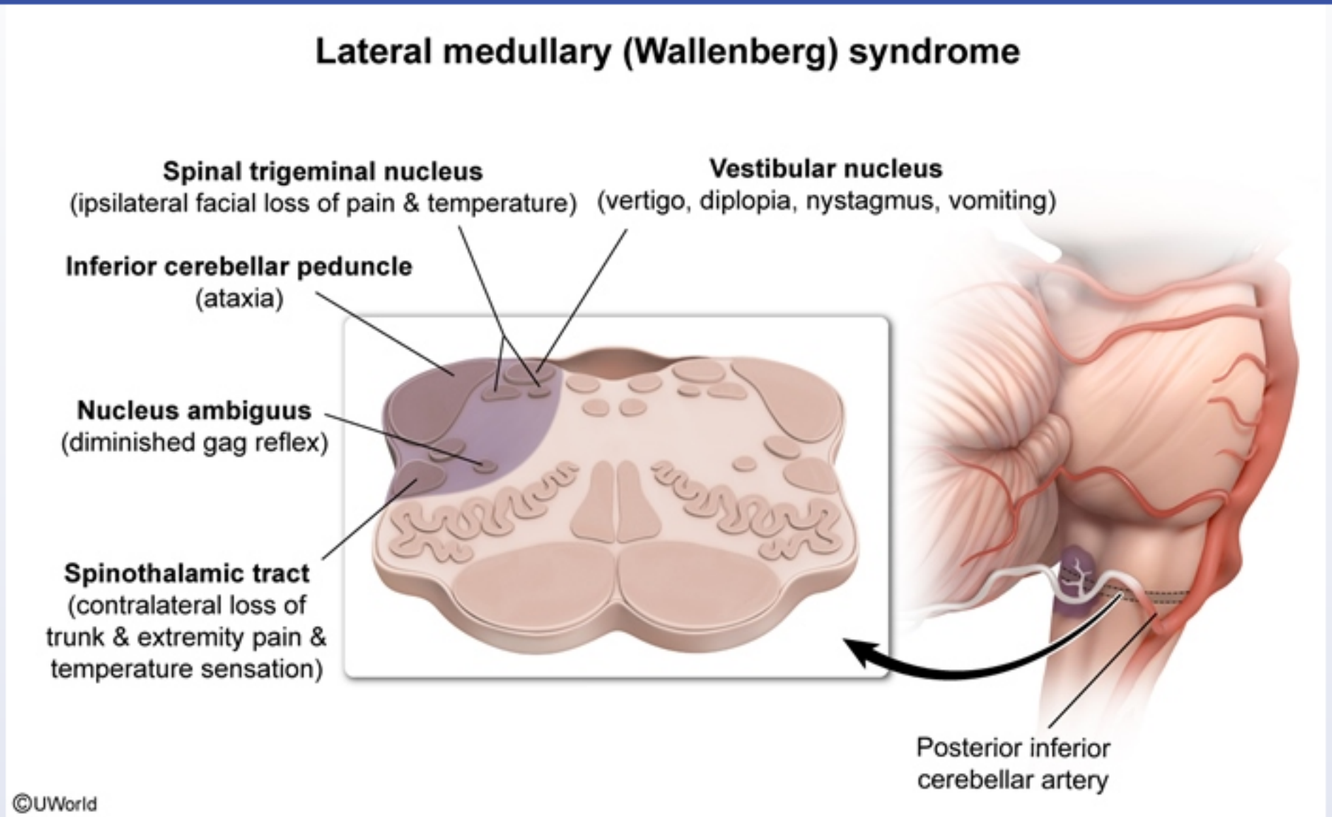

This patient's neurologic findings are consistent with acute ischemia involving the right **posterior inferior cerebellar artery** (PICA), which arises from the vertebral artery. Occlusion of the PICA results in **lateral medullary (Wallenberg) syndrome**. Characteristic features include vertigo/nystagmus, ipsilateral cerebellar signs (eg, ataxia), loss of pain/temperature sensation in the ipsilateral face and contralateral body, and bulbar weakness (eg, dysphagia, dysphonia). Patients may also develop ipsilateral Horner syndrome (ie, miosis, ptosis, anhidrosis) due to damage of sympathetic fibers innervating the head.

Traumatic vascular dissection is a relatively common cause of ischemic stroke in the young, with most cases affecting the extracranial vessels (eg, carotid and vertebral arteries). The vertebral arteries course through the transverse foramina in the neck before entering the skull at the foramen magnum and therefore can be easily injured by **cervical spinal trauma**. Progressive dissection can ascend intracranially to involve the

This patient's neurologic findings are consistent with acute ischemia involving the right **posterior inferior cerebellar artery** (PICA), which arises from the vertebral artery. Occlusion of the PICA results in **lateral medullary (Wallenberg) syndrome**. Characteristic features include vertigo/nystagmus, ipsilateral cerebellar signs (eg, ataxia), loss of pain/temperature sensation in the ipsilateral face and contralateral body, and bulbar weakness (eg, dysphagia, dysphonia). Patients may also develop ipsilateral Horner syndrome (ie, miosis, ptosis, anhidrosis) due to damage of sympathetic fibers innervating the head.

Traumatic vascular dissection is a relatively common cause of ischemic stroke in the young, with most cases affecting the extracranial vessels (eg, carotid and vertebral arteries). The vertebral arteries course through the transverse foramina in the neck before entering the skull at the foramen magnum and therefore can be easily injured by **cervical spinal trauma**. Progressive dissection can ascend intracranially to involve the section of the vertebral artery where the PICA branches off, leading to delayed development of lateral medullary syndrome (as in this patient with a normal initial examination).

(Choice A) Anterior inferior cerebellar artery (AICA) occlusion (ie, lateral pontine syndrome) due to basilar artery dissection could cause many of this patient's symptoms (eg, ataxia, nystagmus, vertigo, loss of facial sensation). However, traumatic dissection of the basilar artery is rare, and patients with AICA occlusion usually also have hearing loss and facial paralysis.

(Choices B and C) Common and internal carotid artery dissections can occur with cervical spinal injuries. However, carotid artery occlusion typically causes profound neurologic deficits (eg, contralateral homonymous hemianopsia, hemiparesis, hemisensory loss) due to hemispheric cerebral infarction.

(Choices D and E) Traumatic dissections involving the intracranial arteries are rare. These vessels are typically occluded by atherothrombosis or cardioembolism in older adults with cardiovascular risk factors. Middle cerebral artery occlusion causes contralateral hemiparesis and hemisensory loss (face and arm > leg), conjugate gaze deviation, contralateral homonymous hemianopsia, and aphasia if the dominant (usually left) hemisphere is involved. Posterior cerebral artery occlusion causes contralateral, homonymous hemianopsia with macular sparing because the macula is also supplied by the middle cerebral artery.

Educational objective:
Cervical spine trauma can cause dissection of the vertebral artery, resulting in ischemic manifestations due to occlusion of the vertebral artery and/or its branches. Posterior inferior cerebellar artery occlusion causes lateral medullary (Wallenberg) syndrome, characterized by vertigo/nystagmus, ipsilateral cerebellar signs, loss of pain/temperature sensation in the ipsilateral face and contralateral body, bulbar weakness, and ipsilateral Horner syndrome.

This patient's neurologic findings are consistent with acute ischemia involving the right **posterior inferior cerebellar artery** (PICA), which arises

Exhibit Display

Vertebrobasilar system

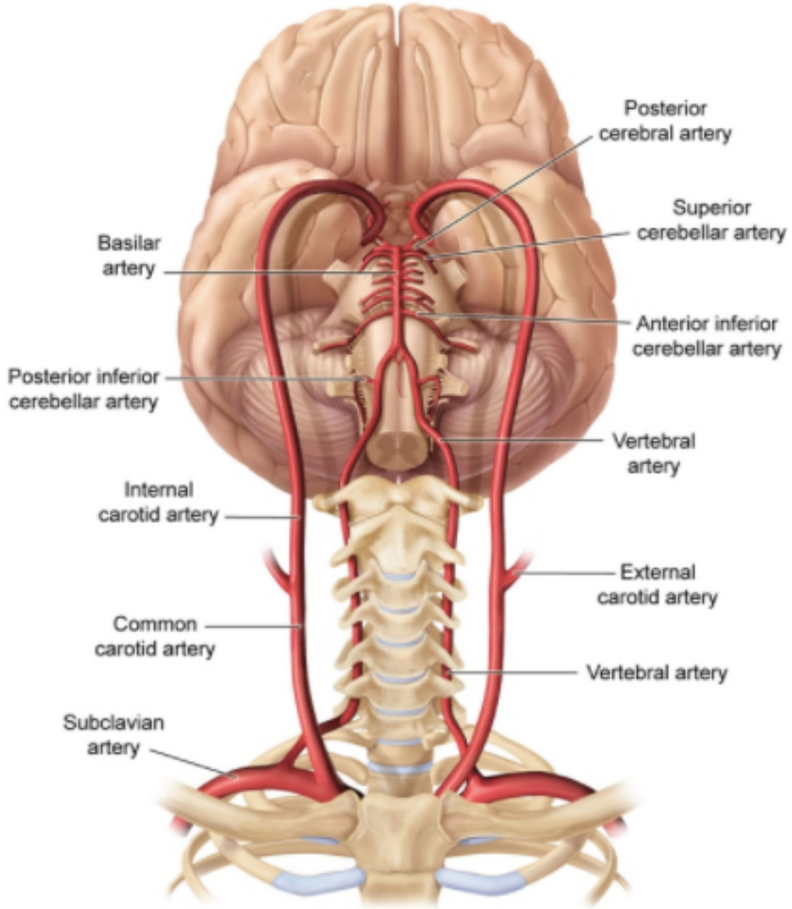

©UWorld

Zoom In | Zoom Out | Reset | Add To New Card | Existing Card

and insilateral Horner syndrome

This patient's neurologic findings are consistent with acute ischemia involving the right **posterior inferior cerebellar artery** (PICA), which arises

Exhibit Display

Vertebrobasilar system

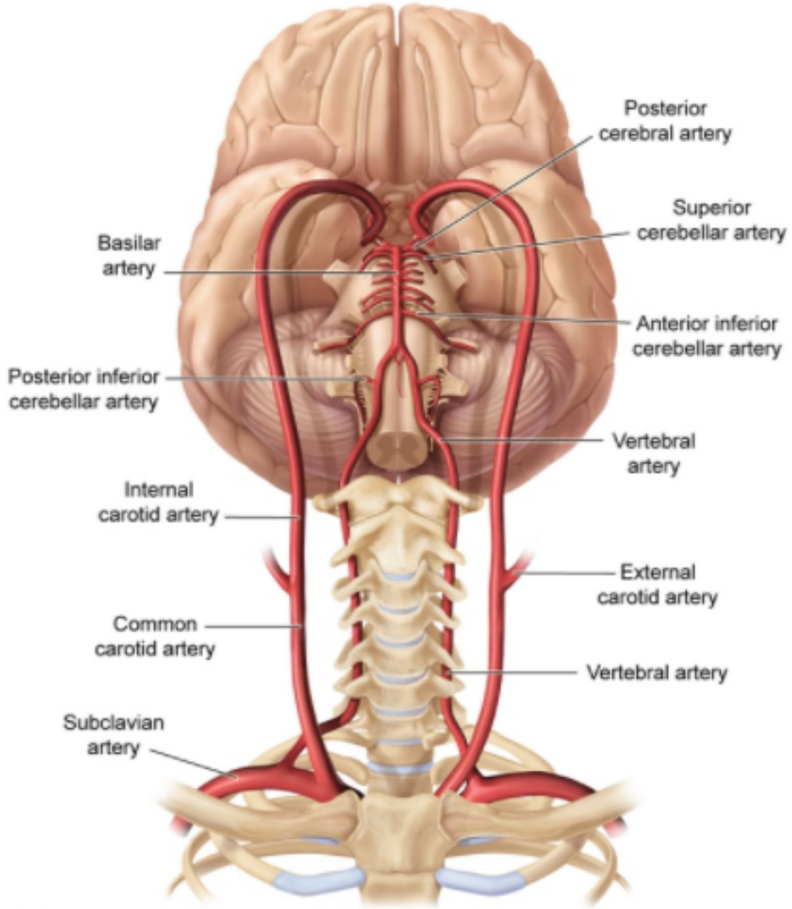

©UWorld

Zoom In | Zoom Out | Reset | Add To New Card | Existing Card

and insilateral Horner syndrome

This patient's neurologic findings are consistent with acute ischemia involving the right **posterior inferior cerebellar artery** (PICA), which arises

Exhibit Display

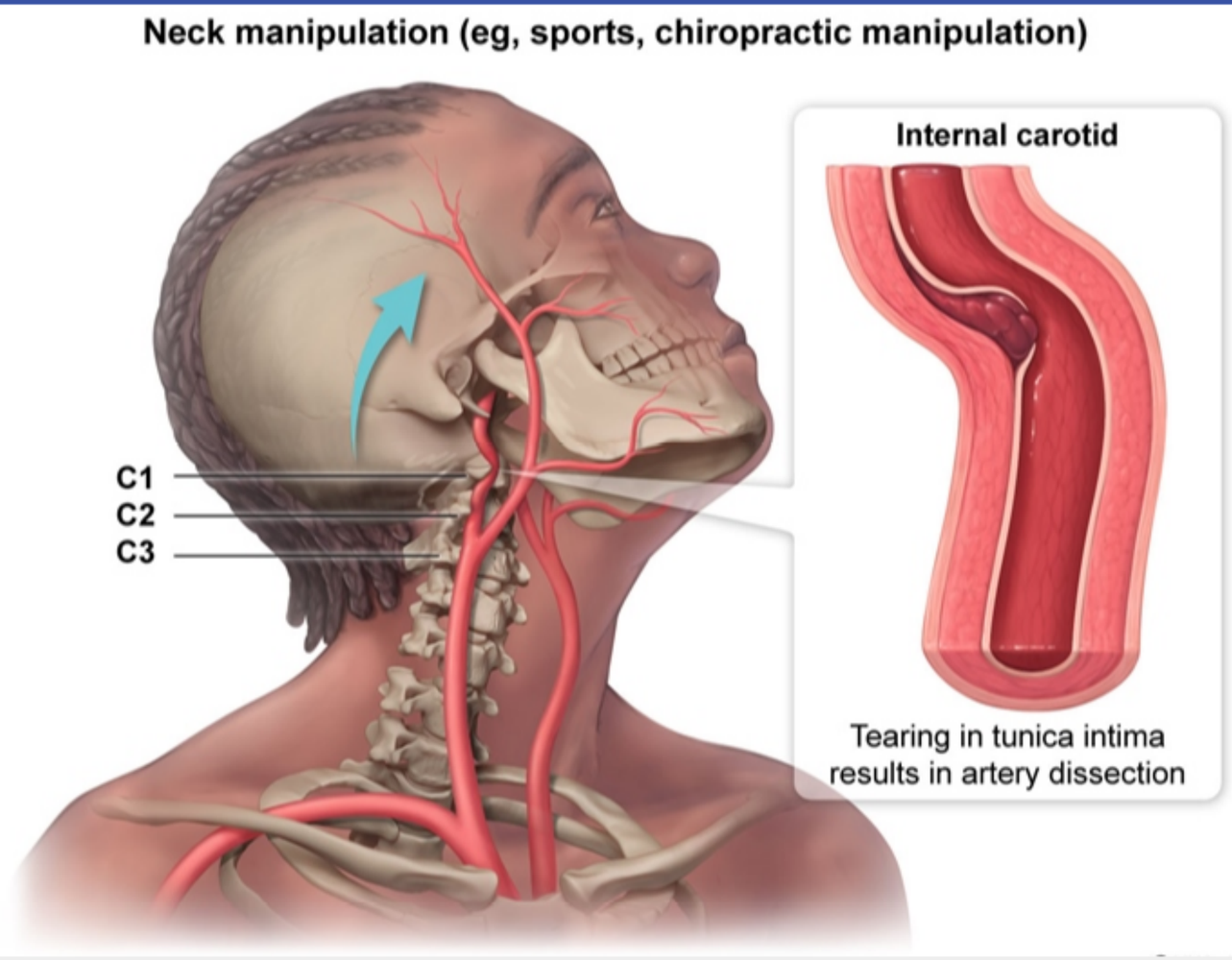

Zoom In | Zoom Out | Reset | Add To New Card | Existing Card

and ipsilateral Horner syndrome

section of the vertebral artery where the PICA branches off, leading to delayed development of lateral medullary syndrome (as in this patient with a normal initial examination).

(Choice A) Anterior inferior cerebellar artery (AICA) occlusion (ie, lateral pontine syndrome) due to basilar artery dissection could cause many of this patient's symptoms (eg, ataxia, nystagmus, vertigo, loss of facial sensation). However, traumatic dissection of the basilar artery is rare, and patients with AICA occlusion usually also have hearing loss and facial paralysis.

(Choices B and C) Common and internal carotid artery dissections can occur with cervical spinal injuries. However, carotid artery occlusion typically causes profound neurologic deficits (eg, contralateral homonymous hemianopsia, hemiparesis, hemisensory loss) due to hemispheric cerebral infarction.

(Choices D and E) Traumatic dissections involving the intracranial arteries are rare. These vessels are typically occluded by atherothrombosis or cardioembolism in older adults with cardiovascular risk factors. Middle cerebral artery occlusion causes contralateral hemiparesis and hemisensory loss (face and arm > leg), conjugate gaze deviation, contralateral homonymous hemianopsia, and aphasia if the dominant (usually left) hemisphere is involved. Posterior cerebral artery occlusion causes contralateral, homonymous hemianopsia with macular sparing because the macula is also supplied by the middle cerebral artery.

Educational objective:
Cervical spine trauma can cause dissection of the vertebral artery, resulting in ischemic manifestations due to occlusion of the vertebral artery and/or its branches. Posterior inferior cerebellar artery occlusion causes lateral medullary (Wallenberg) syndrome, characterized by vertigo/nystagmus, ipsilateral cerebellar signs, loss of pain/temperature sensation in the ipsilateral face and contralateral body, bulbar weakness, and ipsilateral Horner syndrome.

References

- Extracranial carotid and vertebral artery dissection: a review.

Anatomy	Nervous System	Ischemic stroke
Subject	System	Topic

Copyright © UWorld. All rights reserved.

1
2
3
4
5
6
7
8
9
10
11
12
13
14
15
16
17
18
19
20
21
22
23
24
25
26
27
28
29
30
31

A 55-year-old right-handed man comes to the emergency department due to persistent right arm tingling and numbness for the past several hours. The patient has no headache, muscle weakness, slurred speech, or difficulty ambulating. He has a history of hypertension, paroxysmal atrial fibrillation, and ischemic stroke without residual symptoms. Anticoagulation was discontinued 2 months ago after he developed a gastrointestinal hemorrhage. Blood pressure is 150/90 mm Hg, and pulse is 92/min and regular. While the patient is being evaluated, his right arm paresthesia spreads to the entire right side of the body and he develops right-sided convulsions, followed by a bilateral tonic-clonic seizure. Which of the structures in the left cerebral hemisphere is the most likely site of origin of this patient's seizure?

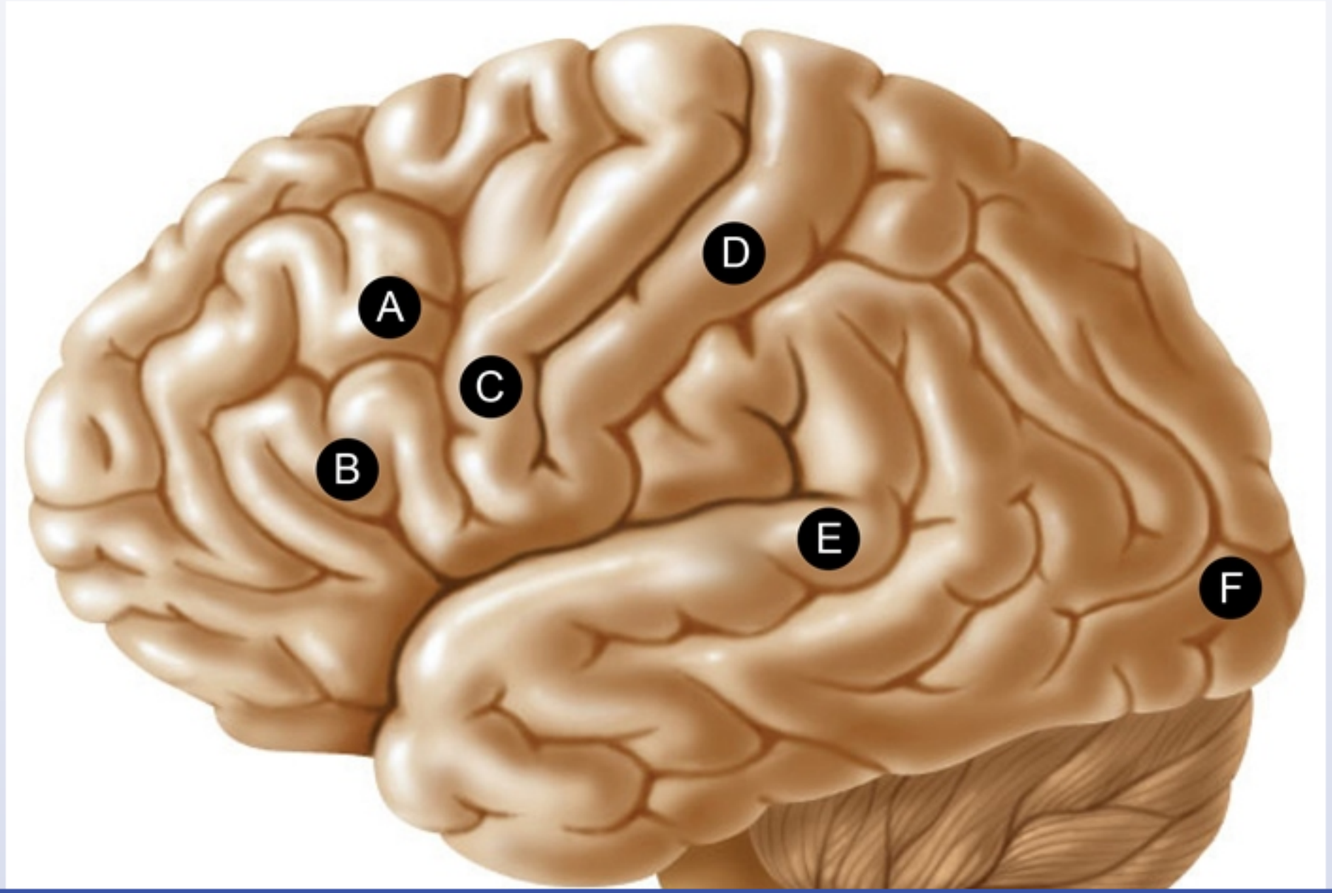

1
2
3
4
5
6
7
8
9
10
11
12
13
14
15
16
17
18
19
20
21
22
23
24
25
26
27
28
29
30
31

A. A

B. B

C. C

D. D

E. E

F. F

Submit

1
2
3
4
5
6
7
8
9
10
11
12
13
14
15
16
17
18
19
20
21
22
23
24
25
26
27
28
29
30
31

A. A (2%)
B. B (1%)
C. C (27%)
✓ D. D (60%)
E. E (7%)
F. F (0%)

Omitted
Correct answer

60%
Answered correctly

05 secs
Time Spent

05/30/2020
Last Updated

1
2
3
4
5
6
7
8
9
10
11
12
13
14
15
16
17
18
19
20
21
22
23
24
25
26
27
28
29
30
31

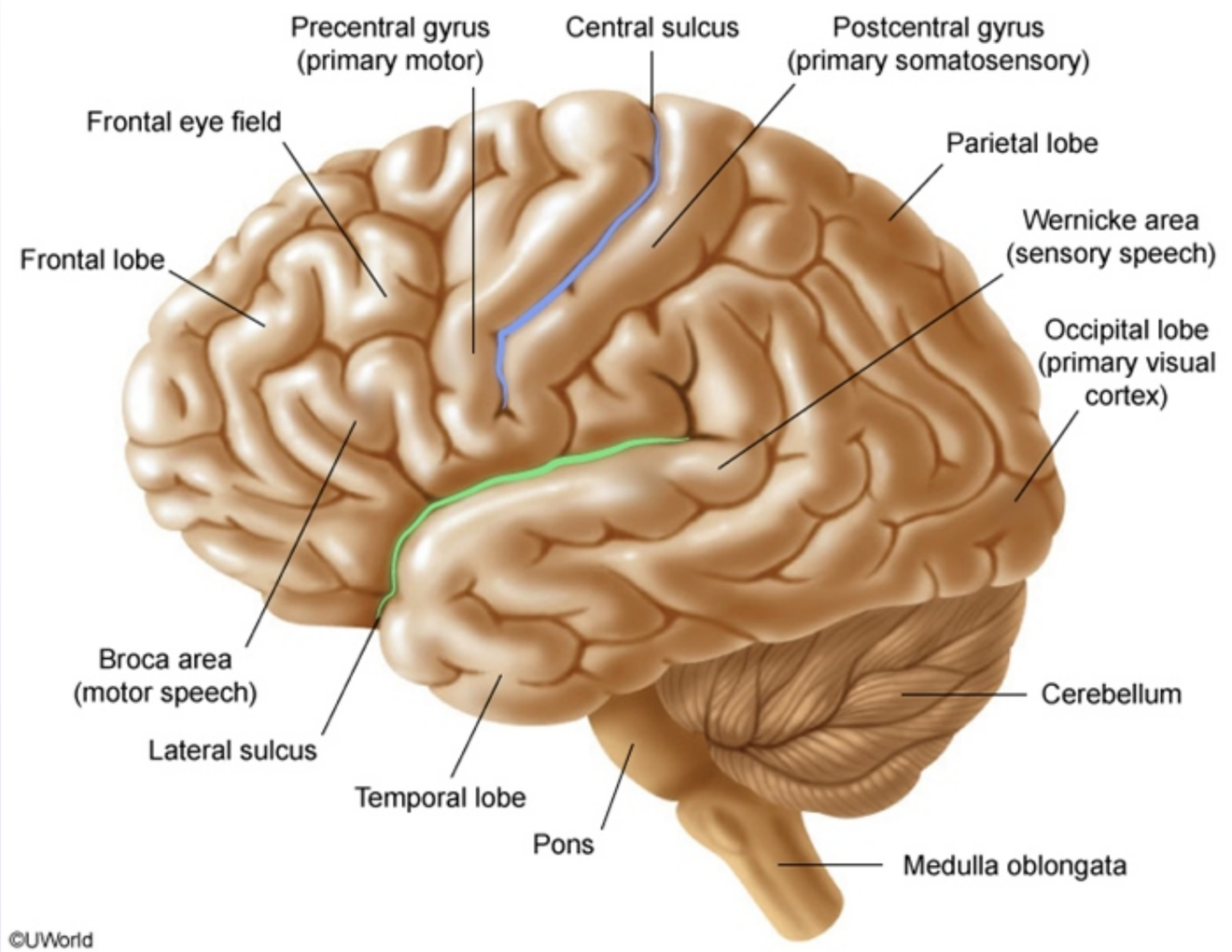

This patient with a history of paroxysmal atrial fibrillation was taken off anticoagulation following a gastrointestinal bleed and is likely suffering from a recurrent **embolic stroke** complicated by seizure. Stroke is one of the most common causes of **seizure**, which occurs due to the release of excitotoxic neurotransmitters in the ischemic brain region.

This patient with a history of paroxysmal atrial fibrillation was taken off anticoagulation following a gastrointestinal bleed and is likely suffering from a recurrent **embolic stroke** complicated by seizure. Stroke is one of the most common causes of **seizure**, which occurs due to the release of excitotoxic neurotransmitters in the ischemic brain region.

Initial manifestations of a seizure vary based on which brain region is affected by the underlying pathology. The primary somatosensory cortex is responsible for processing all somatic sensory input from the contralateral side of the body; therefore, a seizure in this area of the cortex would result in contralateral sensory disturbances. This patient's **initial right arm numbness and paresthesia** was likely caused by a **focal onset seizure** originating in the left primary somatosensory cortex (**postcentral gyrus**).

The patient subsequently developed right-sided convulsions due to spread of the seizure along the lateral brain convexity to the primary motor strip (precentral gyrus) **(Choice C)**. Shortly after, the seizure activity spread to both cerebral hemispheres, resulting in tonic-clonic convulsions.

(Choice A) The frontal eye field is the region of the cerebral cortex that controls horizontal eye movement. Activation of the left frontal eye field during a seizure would cause the eyes to deviate horizontally to the right. After the seizure, the patient's eyes may temporarily deviate to the left due to postictal neuroinhibition.

(Choice B) The motor speech (Broca) area is located in the posterior inferior frontal gyrus of the dominant (usually left) hemisphere and is responsible for controlling expressive speech/language. A seizure involving this area of the brain would likely result in uncontrolled vocalization or expressive aphasia.

(Choice E) The sensory speech (Wernicke) area is located in the posterior superior temporal gyrus of the dominant hemisphere and is responsible for language comprehension. A seizure in this area of the temporal lobe would likely result in fluent aphasia with impaired comprehension or auditory auras.

(Choice F) The primary visual cortex in the occipital lobe is responsible for processing visual information from the contralateral homonymous visual fields. A seizure originating from the left primary visual cortex would likely result in visual hallucinations affecting the right homonymous visual fields.

Educational objective:
The primary somatosensory cortex (postcentral gyrus) is responsible for processing all somatic sensory input from the contralateral side of the body. A focal onset seizure originating in this region of the cerebral cortex often results in contralateral sensory disturbance (eg, numbness,

The patient subsequently developed right-sided convulsions due to spread of the seizure along the lateral brain convexity to the primary motor strip (precentral gyrus) **(Choice C)**. Shortly after, the seizure activity spread to both cerebral hemispheres, resulting in tonic-clonic convulsions.

(Choice A) The frontal eye field is the region of the cerebral cortex that controls horizontal eye movement. Activation of the left frontal eye field during a seizure would cause the eyes to deviate horizontally to the right. After the seizure, the patient's eyes may temporarily deviate to the left due to postictal neuroinhibition.

(Choice B) The motor speech (Broca) area is located in the posterior inferior frontal gyrus of the dominant (usually left) hemisphere and is responsible for controlling expressive speech/language. A seizure involving this area of the brain would likely result in uncontrolled vocalization or expressive aphasia.

(Choice E) The sensory speech (Wernicke) area is located in the posterior superior temporal gyrus of the dominant hemisphere and is responsible for language comprehension. A seizure in this area of the temporal lobe would likely result in fluent aphasia with impaired comprehension or auditory auras.

(Choice F) The primary visual cortex in the occipital lobe is responsible for processing visual information from the contralateral homonymous visual fields. A seizure originating from the left primary visual cortex would likely result in visual hallucinations affecting the right homonymous visual fields.

Educational objective:
The primary somatosensory cortex (postcentral gyrus) is responsible for processing all somatic sensory input from the contralateral side of the body. A focal onset seizure originating in this region of the cerebral cortex often results in contralateral sensory disturbance (eg, numbness, paresthesia).

References

- Symptoms in focal sensory seizures. Clinical and electroencephalographic features.

Anatomy	Nervous System	Seizures
Subject	System	Topic

Copyright © UWorld. All rights reserved.

1
2
3
4
5
6
7
8
9
10
11
12
13
14
15
16
17
18
19
20
21
22
23
24
25
26
27
28
29
30
31

A 20-year-old man is evaluated in the clinic for right arm weakness and numbness. He is a competitive baseball pitcher and says that he played a lot more innings than usual last week because his team made the playoffs. Since then, the patient has had difficulty using the right arm, particularly when lifting objects. He has no known history of head, neck, or upper extremity trauma. On physical examination, there is diminished strength on right elbow flexion and an absent biceps reflex. This patient is most likely to have sensory loss over which of the following areas?

A. Lateral forearm

B. Medial forearm

C. Posterior arm

D. Posterior forearm

E. Thenar eminence

Submit

A 20-year-old man is evaluated in the clinic for right arm weakness and numbness. He is a competitive baseball pitcher and says that he played a lot more innings than usual last week because his team made the playoffs. Since then, the patient has had difficulty using the right arm, particularly when lifting objects. He has no known history of head, neck, or upper extremity trauma. On physical examination, there is diminished strength on right elbow flexion and an absent biceps reflex. This patient is most likely to have sensory loss over which of the following areas?

- ✓ A. Lateral forearm (57%)
- B. Medial forearm (22%)
- C. Posterior arm (8%)
- D. Posterior forearm (4%)
- E. Thenar eminence (6%)

Omitted
Correct answer
A

57%
Answered correctly

02 secs
Time Spent

04/13/2020
Last Updated

Explanation

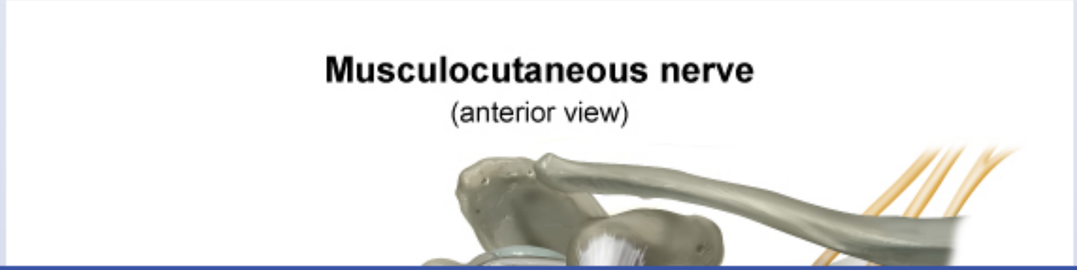

1
2
3
4
5
6
7
8
9
10
11
12
13
14
15
16
17
18
19
20
21
22
23
24
25
26
27
28
29
30
31

Musculocutaneous nerve

(anterior view)

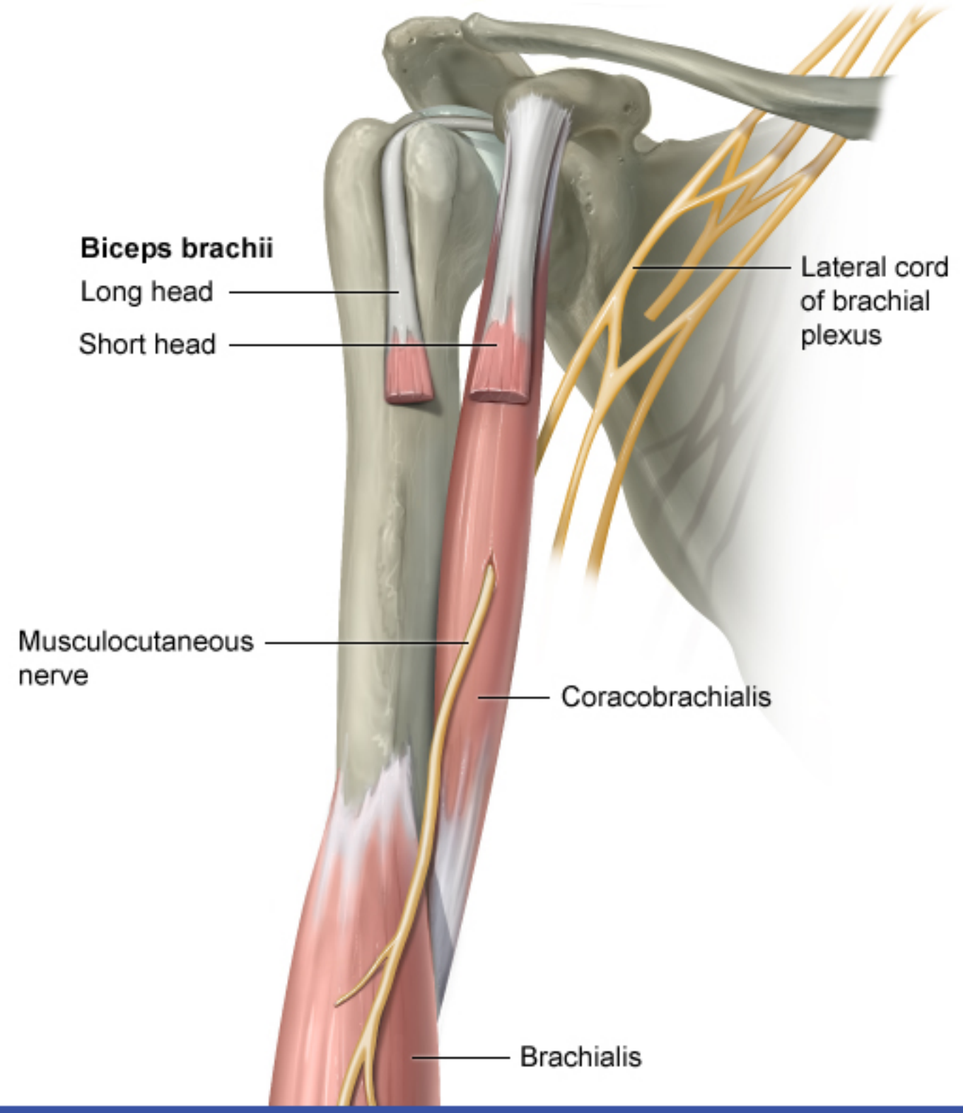

1
2
3
4
5
6
7
8
9
10
11
12
13
14
15
16
17
18
19
20
21
22
23
24
25
26
27
28
29
30
31

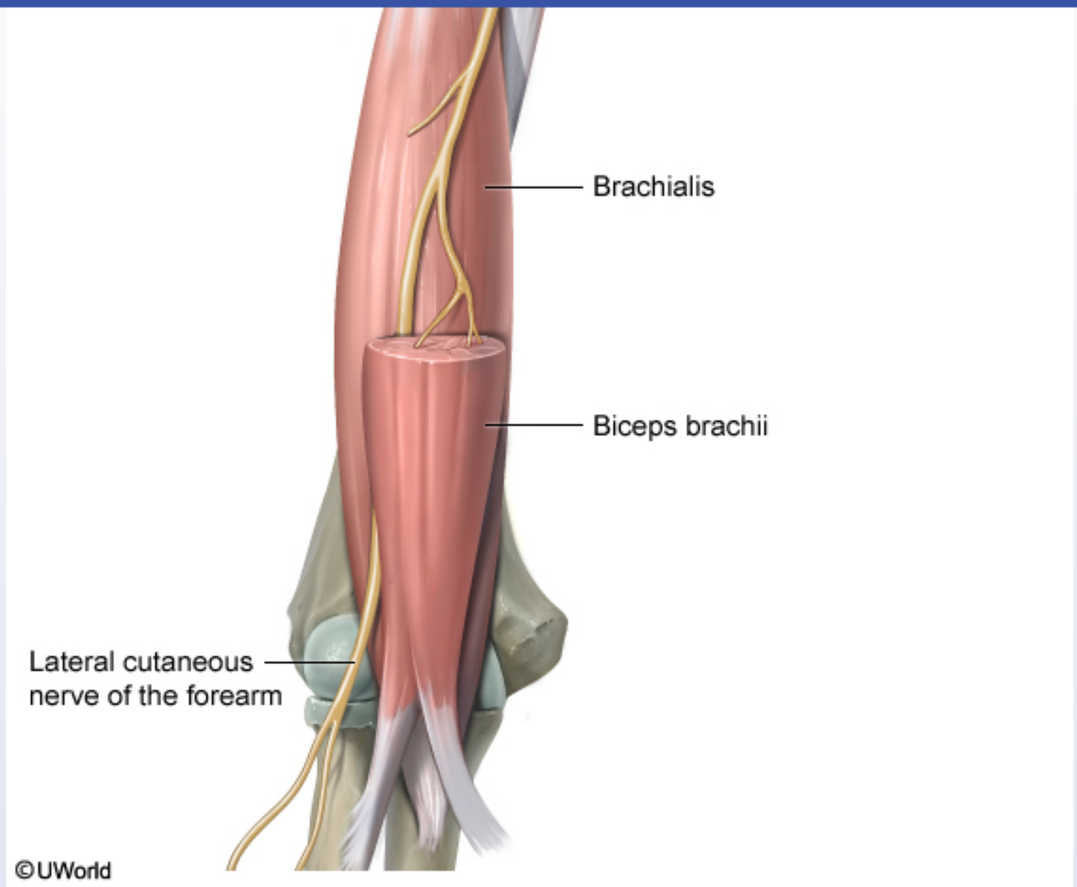

This patient likely has musculocutaneous nerve injury, which most commonly occurs in the setting of trauma (eg, shoulder dislocation) and strenuous upper extremity activity (eg, baseball pitching). The musculocutaneous nerve is derived from the C5-C7 spinal nerve roots and arises from the lateral cord of the brachial plexus. It innervates the major **forearm flexors** (eg, biceps brachii, brachialis) and coracobrachialis (flexes and adducts the arm). After innervating these muscles, the remaining fibers become the lateral cutaneous nerve of the forearm and provide sensory innervation to the skin of the **lateral forearm**.

(Choice B) The medial forearm receives sensory innervation from a branch of the medial cord of the brachial plexus (medial cutaneous nerve of the forearm).

©UWorld

This patient likely has musculocutaneous nerve injury, which most commonly occurs in the setting of trauma (eg, shoulder dislocation) and strenuous upper extremity activity (eg, baseball pitching). The musculocutaneous nerve is derived from the C5-C7 spinal nerve roots and arises from the lateral cord of the brachial plexus. It innervates the major **forearm flexors** (eg, biceps brachii, brachialis) and coracobrachialis (flexes and adducts the arm). After innervating these muscles, the remaining fibers become the lateral cutaneous nerve of the forearm and provide sensory innervation to the skin of the **lateral forearm**.

(Choice B) The medial forearm receives sensory innervation from a branch of the medial cord of the brachial plexus (medial cutaneous nerve of the forearm).

(Choices C and D) The posterior arm and forearm receive sensory innervation from the posterior cutaneous branches of the radial nerve.

(Choice E) The thenar eminence receives sensory innervation from the palmar cutaneous branch of the median nerve, which arises proximal to the carpal tunnel.

Educational objective:
The musculocutaneous nerve innervates the major forearm flexors (eg, biceps brachii, brachialis) and coracobrachialis (flexes and adducts the arm) and provides sensory innervation to the lateral forearm. It is derived from the upper trunk of the brachial plexus (C5-C7) and can be injured by trauma or strenuous upper extremity exercise.

References

- Peripheral nerve entrapment and injury in the upper extremity.
- Musculocutaneous neuropathy: case report and discussion.
- Musculocutaneous nerve injury in major league baseball pitchers: a report of 2 cases.

Anatomy	Nervous System	Brachial plexus
Subject	System	Topic

Copyright © UWorld. All rights reserved.

©UWorld

Exhibit Display

Important nerves in the arm

Nerve	Motor function	Region of sensory loss with neuropathy
Musculocutaneous nerve	Flexion of arm at elbow, supination of forearm	

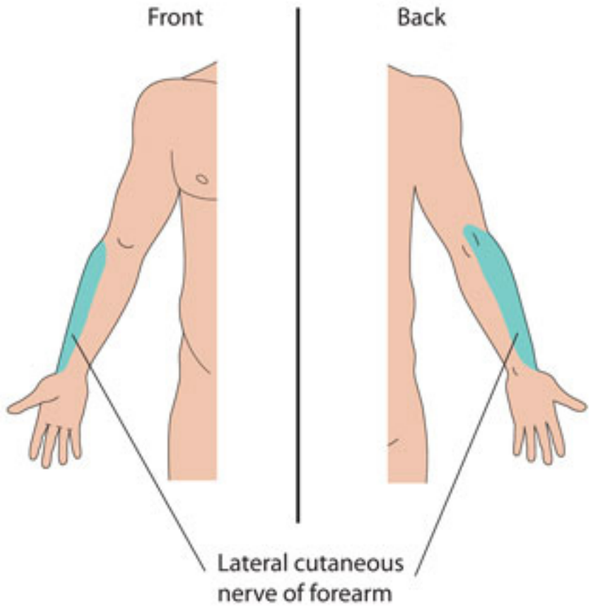

USMLEWorld, LLC © 2011

Zoom In | Zoom Out | Reset | Add To New Card | Existing Card

©UWorld

Exhibit Display

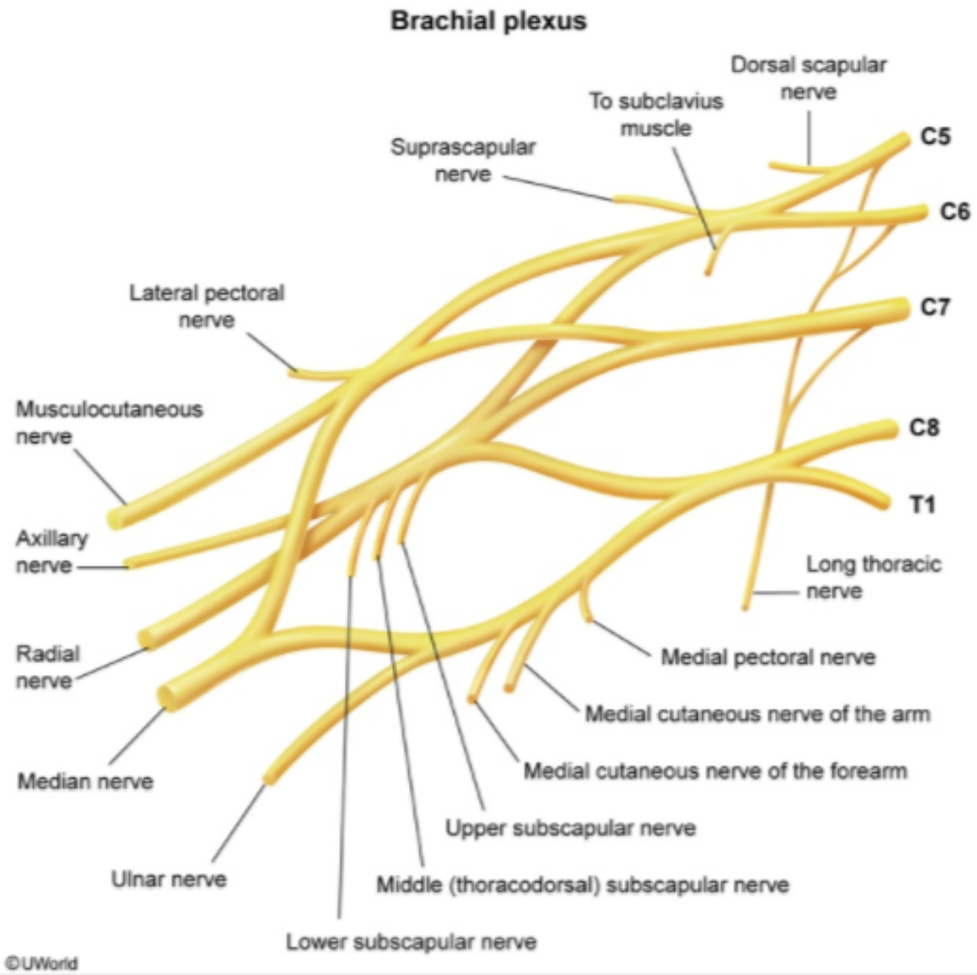

Zoom In | Zoom Out | Reset | Add To New Card | Existing Card

©UWorld

Exhibit Display

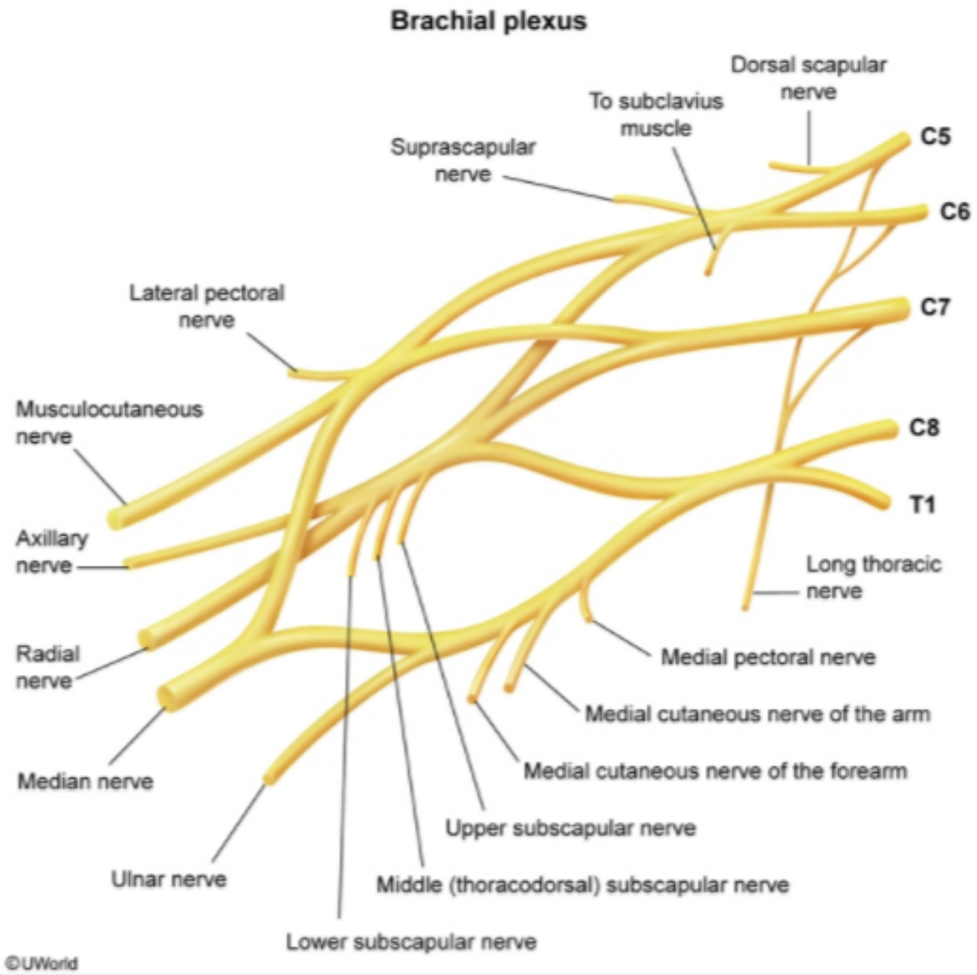

Zoom In | Zoom Out | Reset | Add To New Card | Existing Card

1
2
3
4
5
6
7
8
9
10
11
12
13
14
15
16
17
18
19
20
21
22
23
24
25
26
27
28
29
30
31

A 62-year-old man comes to the office with right arm clumsiness. Physical examination reveals motor weakness involving the right arm and leg. The patient's speech is slurred, and there is drooping of the right lower face. On passive flexion of the right arm, there is initial resistance followed by a sudden release of tension as flexion is continued. A lesion affecting which of the following brain structures is most likely responsible for this patient's condition?

Displayed with permission from Springer Healthcare Ltd.
©Copyright 1995, 2004 by Current Medicine

A. A
B. B
C. C

1
2
3
4
5
6
7
8
9
10
11
12
13
14
15
16
17
18
19
20
21
22
23
24
25
26
27
28
29
30
31

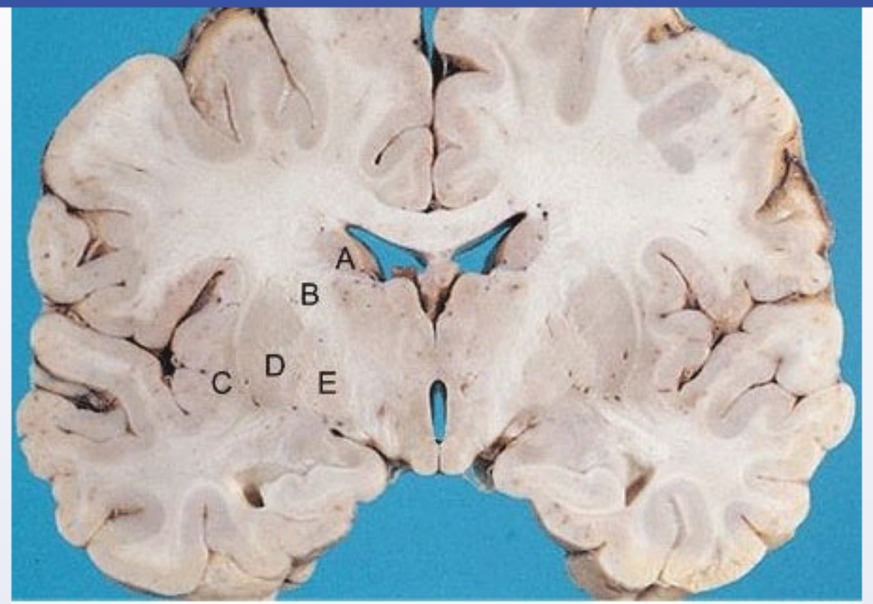

Displayed with permission from Springer Healthcare Ltd.
©Copyright 1995, 2004 by Current Medicine

A. A

B. B

C. C

D. D

E. E

Submit

1
2
3
4
5
6
7
8
9
10
11
12
13
14
15
16
17
18
19
20
21
22
23
24
25
26
27
28
29
30
31

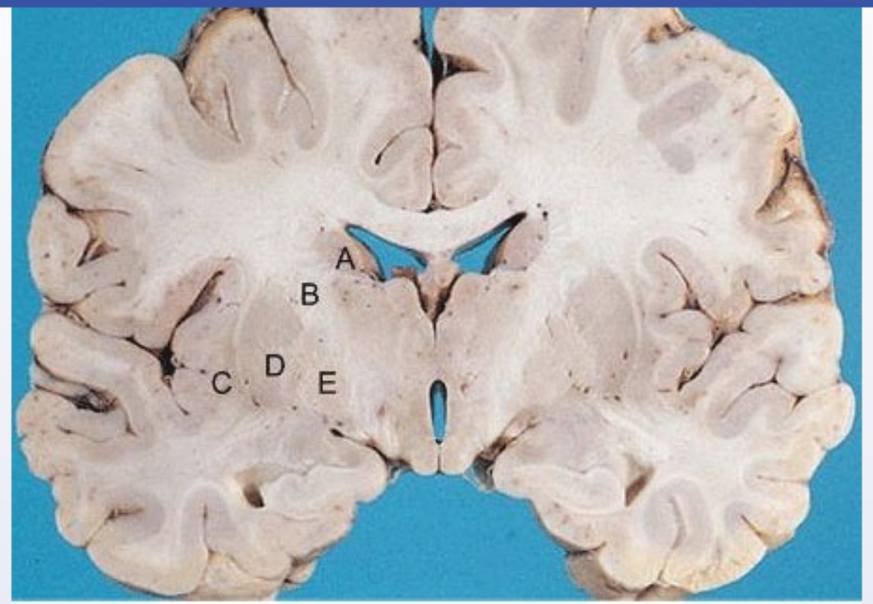

Displayed with permission from Springer Healthcare Ltd.
©Copyright 1995, 2004 by Current Medicine

A. A (7%)
✓ B. B (60%)
C. C (7%)
D. D (12%)
E. E (11%)

Omitted
Correct answer

60%
Answered correctly

06 secs
Time Spent

03/22/2020
Last Updated

1
2
3
4
5
6
7
8
9
10
11
12
13
14
15
16
17
18
19
20
21
22
23
24
25
26
27
28
29
30
31

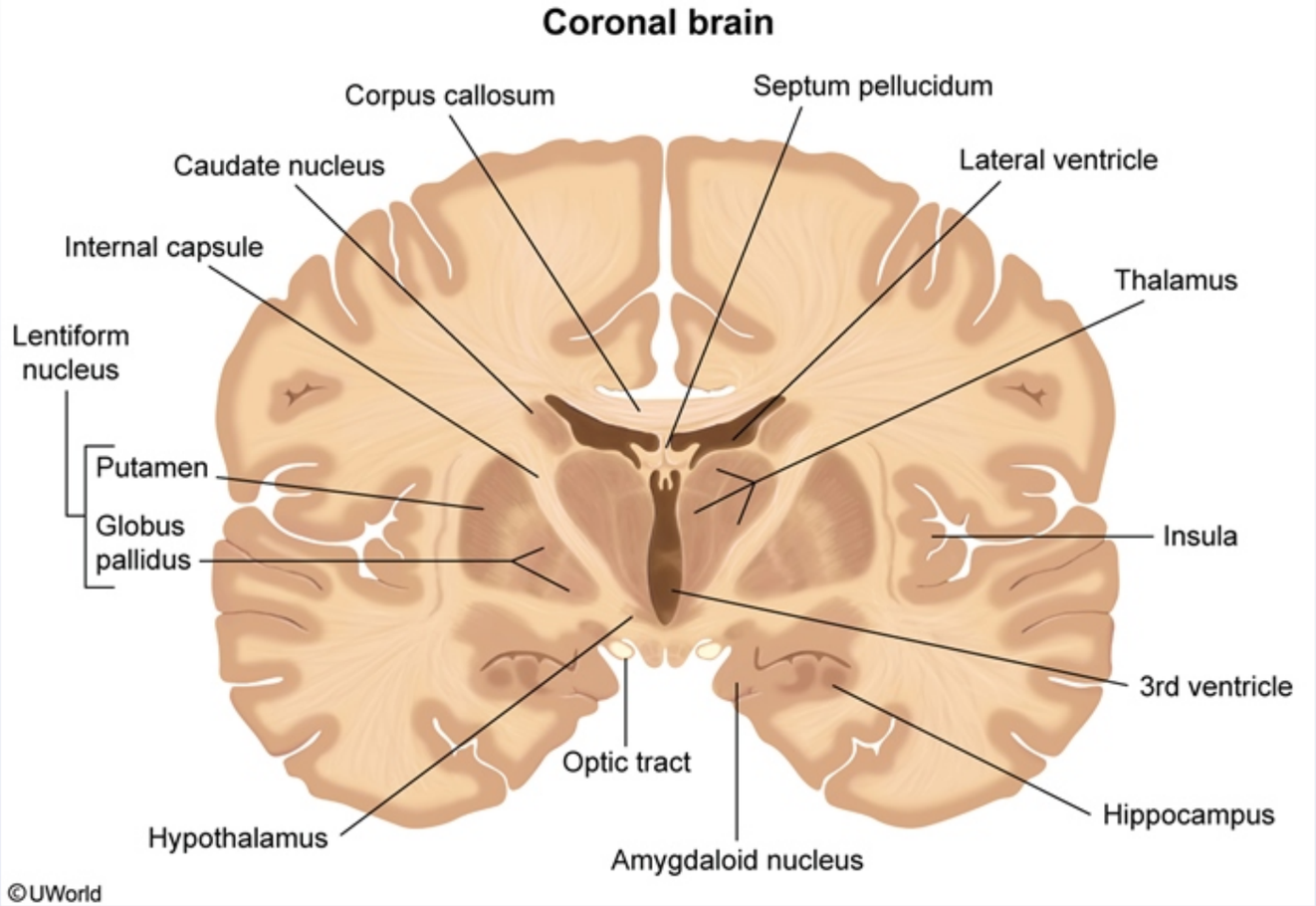

This patient has **clasp-knife spasticity**, which is characterized by initial resistance to passive flexion followed by a sudden release of resistance. This form of spasticity is seen with **upper motor neuron lesions** and results from a lack of upper motor neuron inhibition on the spinal stretch reflex arc. With passive arm flexion, the extensor muscles are activated by the **disinhibited stretch reflex**, causing initial resistance that can be overcome with continued flexion.

Upper motor neuron lesions can affect any part of the **pyramidal motor system** (eg, corticobulbar/corticospinal tracts), which runs from the precentral gyrus (primary motor cortex) through the internal capsule to the brainstem and spinal cord. Patients with an **internal capsule stroke**

This patient has **clasp-knife spasticity**, which is characterized by initial resistance to passive flexion followed by a sudden release of resistance. This form of spasticity is seen with **upper motor neuron lesions** and results from a lack of upper motor neuron inhibition on the spinal stretch reflex arc. With passive arm flexion, the extensor muscles are activated by the **disinhibited stretch reflex**, causing initial resistance that can be overcome with continued flexion.

Upper motor neuron lesions can affect any part of the **pyramidal motor system** (eg, corticobulbar/corticospinal tracts), which runs from the precentral gyrus (primary motor cortex) through the internal capsule to the brainstem and spinal cord. Patients with an **internal capsule stroke** can have both sensory and motor deficits, but most commonly have pure **motor weakness** affecting the **contralateral arm**, **leg**, **and lower face** as well as clasp-knife spasticity, hyperreflexia, and a positive Babinski sign.

(Choices A, D, and E) The caudate nucleus, putamen, and globus pallidus (ie, basal ganglia) are part of the extrapyramidal motor system, which regulates both voluntary and involuntary motor function (eg, posture, muscle tone, prevention of erratic movements). Lesions to these structures can result in motor dysfunction, including chorea (ie, random, jerky, uncontrollable movements), tremor, bradykinesia, or rigidity, as well as changes in cognition and behavior.

(Choice C) The insular cortex (insula) plays a role in consciousness and emotion (along with the limbic system), autonomic nervous system control, and awareness of visceral sensations.

Educational objective:
Upper motor neuron lesions (ie, internal capsule stroke) cause contralateral weakness with clasp-knife spastic rigidity, hyperreflexia, and a positive Babinski sign. These lesions damage the pyramidal motor system (eg, corticospinal tracts), which runs from the precentral gyrus (primary motor cortex) through the internal capsule to the brainstem and spinal cord.

References

- Pathology of lacunar ischemic stroke in humans--a systematic review.

Anatomy	Nervous System	Ischemic stroke
Subject	System	Topic

Copyright © UWorld. All rights reserved.

1
2
3
4
5
6
7
8
9
10
11
12
13
14
15
16
17
18
19
20
21
22
23
24
25
26
27
28
29
30
31

A 5-year-old boy has developed persistent food-seeking behavior over the past few months. His mother initially thought that the boy was undergoing a growth spurt, but despite how much she fed him he never seemed satisfied. He has gained more than 4.5 kg (10 lb). The patient has also started complaining of a headache and nausea in the morning. His physical examination is significant for BMI of 32 kg/m^2. Temperature is 37.2 C (99 F), blood pressure is 100/70 mm Hg, pulse is 92/min, and respirations are 16/min. His pediatrician becomes concerned about possible central nervous system involvement. This patient's food-seeking behavior could be explained by a lesion causing impairment of which hypothalamic nucleus?

A. Anterior
B. Lateral
C. Posterior
D. Suprachiasmatic
E. Supraoptic
F. Ventromedial

Submit

A 5-year-old boy has developed persistent food-seeking behavior over the past few months. His mother initially thought that the boy was undergoing a growth spurt, but despite how much she fed him he never seemed satisfied. He has gained more than 4.5 kg (10 lb). The patient has also started complaining of a headache and nausea in the morning. His physical examination is significant for BMI of 32 kg/m^2. Temperature is 37.2 C (99 F), blood pressure is 100/70 mm Hg, pulse is 92/min, and respirations are 16/min. His pediatrician becomes concerned about possible central nervous system involvement. This patient's food-seeking behavior could be explained by a lesion causing impairment of which hypothalamic nucleus?

A. Anterior (5%)
B. Lateral (20%)
C. Posterior (3%)
D. Suprachiasmatic (2%)
E. Supraoptic (1%)
✓ F. Ventromedial (66%)

Omitted
Correct answer
F

66%
Answered correctly

01 sec
Time Spent

04/07/2020
Last Updated

Explanation

Major functions of hypothalamic nuclei	
Ventromedial	Mediates satiety; destruction leads to hyperphagia

Major functions of hypothalamic nuclei	
Ventromedial	Mediates satiety; destruction leads to hyperphagia
Lateral	Mediates hunger; destruction leads to anorexia
Anterior	Mediates heat dissipation; destruction leads to hyperthermia
Posterior	Mediates heat conservation; destruction leads to hypothermia
Arcuate	Secretion of dopamine (inhibits prolactin), GHRH
Medial preoptic	Secretion of GnRH, regulates sexual behavior
Paraventricular	Secretion of oxytocin, CRH, TRH & small amounts of ADH
Supraoptic	Secretion of ADH & small amounts of oxytocin
Suprachiasmatic	Circadian rhythm regulation & pineal gland function

ADH = antidiuretic hormone; CRH = corticotropin-releasing hormone; GHRH = growth hormone-releasing hormone; GnRH = gonadotropin-releasing hormone; TRH = thyrotropin-releasing hormone.

The **hypothalamus** is in the diencephalon at the base of the brain. It is a key region involved in **homeostasis**; including the regulation of temperature, appetite, emotion, growth, and circadian rhythm. The ventromedial and lateral nuclei are involved in the regulation of food intake.

The **ventromedial nucleus** is vital in monitoring blood glucose and **mediates satiety**. Lesions of this area of the hypothalamus (eg, trauma, infection, brain tumors) can result in **hyperphagia and obesity**. Conversely, the lateral nucleus signals hunger. Lesions can result in loss of appetite (eg, failure to thrive) **(Choice B)**.

(Choices A and C) The anterior and posterior nuclei are involved in temperature control through regulation of the autonomic nervous system. The anterior nucleus coordinates cooling via inhibition of adrenergic input, causing vasodilation and stimulation of cholinergic pathways (eg, sweating). Destruction of this nucleus can cause uncontrolled hyperthermia. Conversely, the posterior nucleus regulates heat conservation and

hormone; TRH = thyrotropin-releasing hormone.

The **hypothalamus** is in the diencephalon at the base of the brain. It is a key region involved in **homeostasis**; including the regulation of temperature, appetite, emotion, growth, and circadian rhythm. The ventromedial and lateral nuclei are involved in the regulation of food intake.

The **ventromedial nucleus** is vital in monitoring blood glucose and **mediates satiety**. Lesions of this area of the hypothalamus (eg, trauma, infection, brain tumors) can result in **hyperphagia and obesity**. Conversely, the lateral nucleus signals hunger. Lesions can result in loss of appetite (eg, failure to thrive) **(Choice B)**.

(Choices A and C) The anterior and posterior nuclei are involved in temperature control through regulation of the autonomic nervous system. The anterior nucleus coordinates cooling via inhibition of adrenergic input, causing vasodilation and stimulation of cholinergic pathways (eg, sweating). Destruction of this nucleus can cause uncontrolled hyperthermia. Conversely, the posterior nucleus regulates heat conservation and heat production via vasoconstriction and shivering. Destruction can lead to hypothermia.

(Choice D) The suprachiasmatic nucleus is located immediately above the optic chiasm and receives visual input directly from the retina. It helps regulate circadian rhythms by relaying light information to other hypothalamic nuclei and to the pineal gland.

(Choice E) The supraoptic and paraventricular nuclei project axons into the posterior pituitary gland (neurohypophysis), producing vasopressin (antidiuretic hormone) and oxytocin. Oxytocin is associated with uterine contractions and milk letdown; vasopressin regulates fluid balance via reabsorption of water from the kidneys.

Educational objective:
The hypothalamus is a key region responsible for homeostasis. The ventromedial nucleus mediates satiety; lesions of this area of the hypothalamus can result in hyperphagia and obesity.

References

- Role of ventromedial hypothalamus in high fat diet induced obesity in male rats: association with lipid profile, thyroid profile and insulin resistance.
- Metabolic mystery: aging, obesity, diabetes, and the ventromedial hypothalamus.

Anatomy Nervous System Brain tumors

A 68-year-old woman is evaluated for right lower extremity weakness while hospitalized. The patient was admitted after sustaining a right femoral neck fracture and underwent total hip arthroplasty. Her operative course was uncomplicated, but the patient experienced right leg weakness postoperatively. Since the surgery, she has had difficulty with physical therapy and reports numbness of the right leg. The patient's other medical conditions include hypertension, type 2 diabetes mellitus, a prior transient ischemic attack, and osteoarthritis. Right lower extremity examination shows weakness in dorsiflexion, plantar flexion, and knee flexion. Hip flexion and knee extension are normal. Sensation to light touch is decreased on the dorsum of the right foot and posterolateral aspect of the right calf. Ankle reflex is absent on the right. Which of the following is the most likely cause of this patient's current findings?

- A. Diabetic neuropathy
- B. L5 radiculopathy
- C. Lacunar stroke
- D. Peroneal nerve compression
- E. Sciatic nerve injury

Submit

A 68-year-old woman is evaluated for right lower extremity weakness while hospitalized. The patient was admitted after sustaining a right femoral neck fracture and underwent total hip arthroplasty. Her operative course was uncomplicated, but the patient experienced right leg weakness postoperatively. Since the surgery, she has had difficulty with physical therapy and reports numbness of the right leg. The patient's other medical conditions include hypertension, type 2 diabetes mellitus, a prior transient ischemic attack, and osteoarthritis. Right lower extremity examination shows weakness in dorsiflexion, plantar flexion, and knee flexion. Hip flexion and knee extension are normal. Sensation to light touch is decreased on the dorsum of the right foot and posterolateral aspect of the right calf. Ankle reflex is absent on the right. Which of the following is the most likely cause of this patient's current findings?

- A. Diabetic neuropathy (2%)
- B. L5 radiculopathy (12%)
- C. Lacunar stroke (1%)
- D. Peroneal nerve compression (24%)
- ✓ E. Sciatic nerve injury (58%)

Omitted
Correct answer
E

58%
Answered correctly

01 sec
Time Spent

04/27/2020
Last Updated

Explanation

Sciatic nerve

Posterior

1
2
3
4
5
6
7
8
9
10
11
12
13
14
15
16
17
18
19
20
21
22
23
24
25
26
27
28
29
30
31

Sciatic nerve

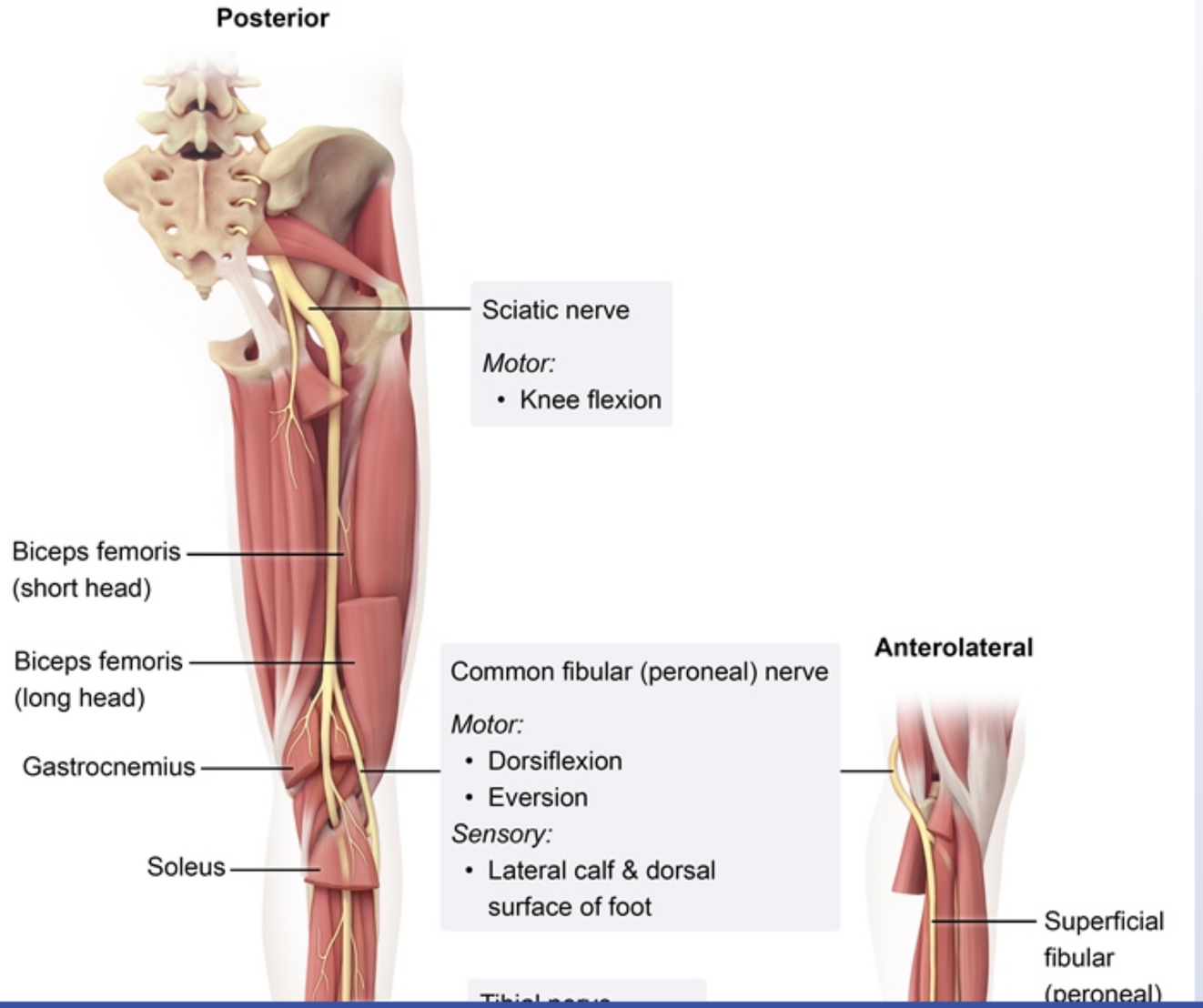

1
2
3
4
5
6
7
8
9
10
11
12
13
14
15
16
17
18
19
20
21
22
23
24
25
26
27
28
29
30
31

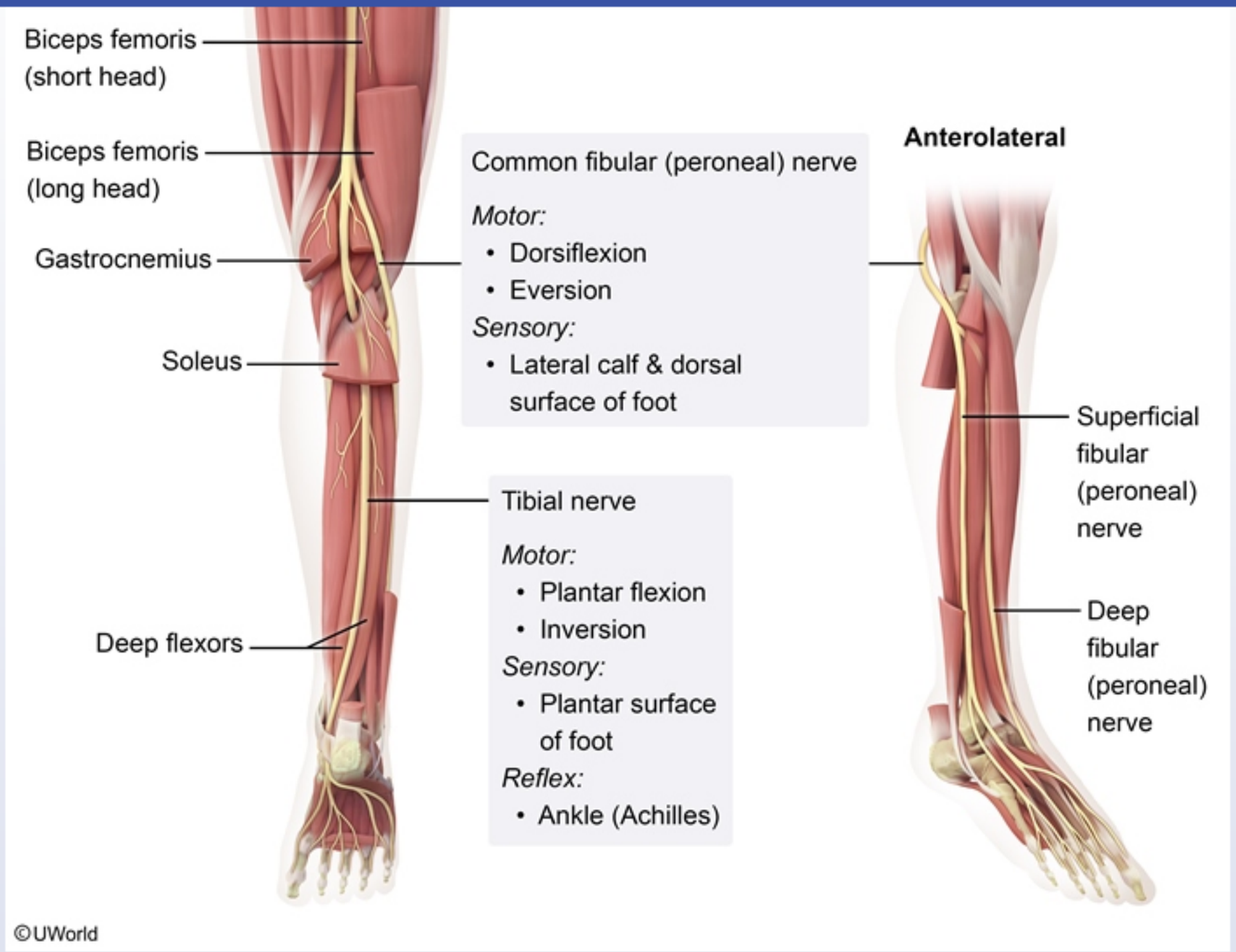

This patient underwent total **hip replacement** following a right **femoral neck fracture** and developed **right lower extremity neurological deficits** across the sciatic nerve (L4-S3) and its main branches:

- Sciatic nerve: weakness in knee flexion

©UWorld

This patient underwent total **hip replacement** following a right **femoral neck fracture** and developed **right lower extremity neurological deficits** across the sciatic nerve (L4-S3) and its main branches:

- Sciatic nerve: weakness in knee flexion
- Common peroneal nerve: weakness in dorsiflexion, numbness on dorsal foot and posterolateral calf
- Tibial nerve: weakness in plantar flexion and inversion, absent ankle reflex

These deficits are characteristic of a proximal **sciatic nerve injury**. The sciatic nerve is particularly susceptible to injury in patients with femoral head dislocation, hip fracture, and/or arthroplasty due to its **proximity to the hip joint** and femur. Injury to the nerve can be caused by direct mechanical trauma (caused by the surgery or initial fracture), compression of the nerve (due to hematoma or swelling), or local inflammation.

(Choice A) Diabetic neuropathy often manifests as peripheral sensory loss (eg, stocking-glove numbness). However, the deficits are typically bilateral and develop chronically with loss of distal sensory axons first, followed by motor deficits in advanced cases.

(Choice B) L5 radiculopathy is typically caused by disc herniation or degenerative vertebral changes and can result in unilateral lower extremity motor and sensory loss. However, patients typically have significant radicular back pain with a normal ankle reflex and lateral foot sensation (both derived from the S1 nerve root).

(Choice C) Lacunar strokes occur in deep brain arteries in patients with chronic hypertension and typically cause unilateral sensorimotor deficits without cortical signs (eg, aphasia, hemineglect). However, these lesions typically result in more complete hemiparesis/hemisensory loss (eg, affecting face, arm, and leg); sensorimotor deficits localized to the sciatic distribution are more suggestive of peripheral nerve damage.

(Choice D) Compression of the common peroneal nerve against the neck of the fibula can occur in the setting of prolonged immobilization (eg, surgery, bed rest) and cause weakness in foot dorsiflexion and eversion. However, this patient also has deficits involving the sciatic and tibial nerves, indicating a more proximal lesion.

Educational objective:
Sciatic neuropathy is a common complication of hip fracture and/or arthroplasty because of the proximity of the sciatic nerve to the hip joint. Injury to the sciatic nerve in the pelvis causes neurological deficits across the sciatic nerve (knee flexion), common peroneal nerve (dorsiflexion, numbness of the calf and dorsal foot), and tibial nerve (plantar flexion, ankle reflex).

- Tibial nerve: weakness in plantar flexion and inversion, absent ankle reflex

These deficits are characteristic of a proximal **sciatic nerve injury**. The sciatic nerve is particularly susceptible to injury in patients with femoral head dislocation, hip fracture, and/or arthroplasty due to its **proximity to the hip joint** and femur. Injury to the nerve can be caused by direct mechanical trauma (caused by the surgery or initial fracture), compression of the nerve (due to hematoma or swelling), or local inflammation.

(Choice A) Diabetic neuropathy often manifests as peripheral sensory loss (eg, stocking-glove numbness). However, the deficits are typically bilateral and develop chronically with loss of distal sensory axons first, followed by motor deficits in advanced cases.

(Choice B) L5 radiculopathy is typically caused by disc herniation or degenerative vertebral changes and can result in unilateral lower extremity motor and sensory loss. However, patients typically have significant radicular back pain with a normal ankle reflex and lateral foot sensation (both derived from the S1 nerve root).

(Choice C) Lacunar strokes occur in deep brain arteries in patients with chronic hypertension and typically cause unilateral sensorimotor deficits without cortical signs (eg, aphasia, hemineglect). However, these lesions typically result in more complete hemiparesis/hemisensory loss (eg, affecting face, arm, and leg); sensorimotor deficits localized to the sciatic distribution are more suggestive of peripheral nerve damage.

(Choice D) Compression of the common peroneal nerve against the neck of the fibula can occur in the setting of prolonged immobilization (eg, surgery, bed rest) and cause weakness in foot dorsiflexion and eversion. However, this patient also has deficits involving the sciatic and tibial nerves, indicating a more proximal lesion.

Educational objective:
Sciatic neuropathy is a common complication of hip fracture and/or arthroplasty because of the proximity of the sciatic nerve to the hip joint. Injury to the sciatic nerve in the pelvis causes neurological deficits across the sciatic nerve (knee flexion), common peroneal nerve (dorsiflexion, numbness of the calf and dorsal foot), and tibial nerve (plantar flexion, ankle reflex).

Anatomy	Nervous System	Sciatic neuropathy
Subject	System	Topic

Copyright © UWorld. All rights reserved.

1
2
3
4
5
6
7
8
9
10
11
12
13
14
15
16
17
18
19
20
21
22
23
24
25
26
27
28
29
30
31

Exhibit Display

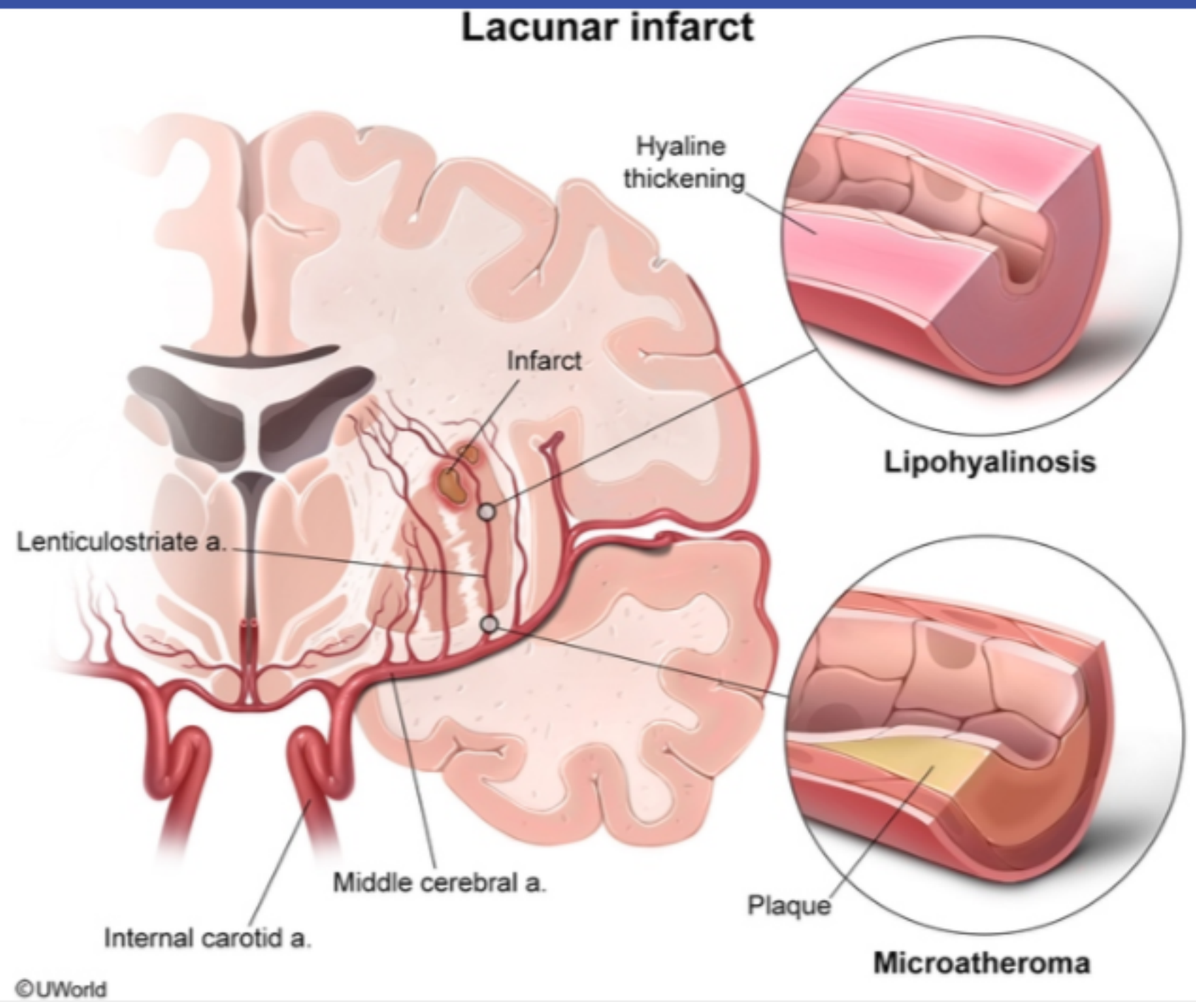

Zoom In | Zoom Out | Reset | Add To New Card | Existing Card

1
2
3
4
5
6
7
8
9
10
11
12
13
14
15
16
17
18
19
20
21
22
23
24
25
26
27
28
29
30
31

Exhibit Display

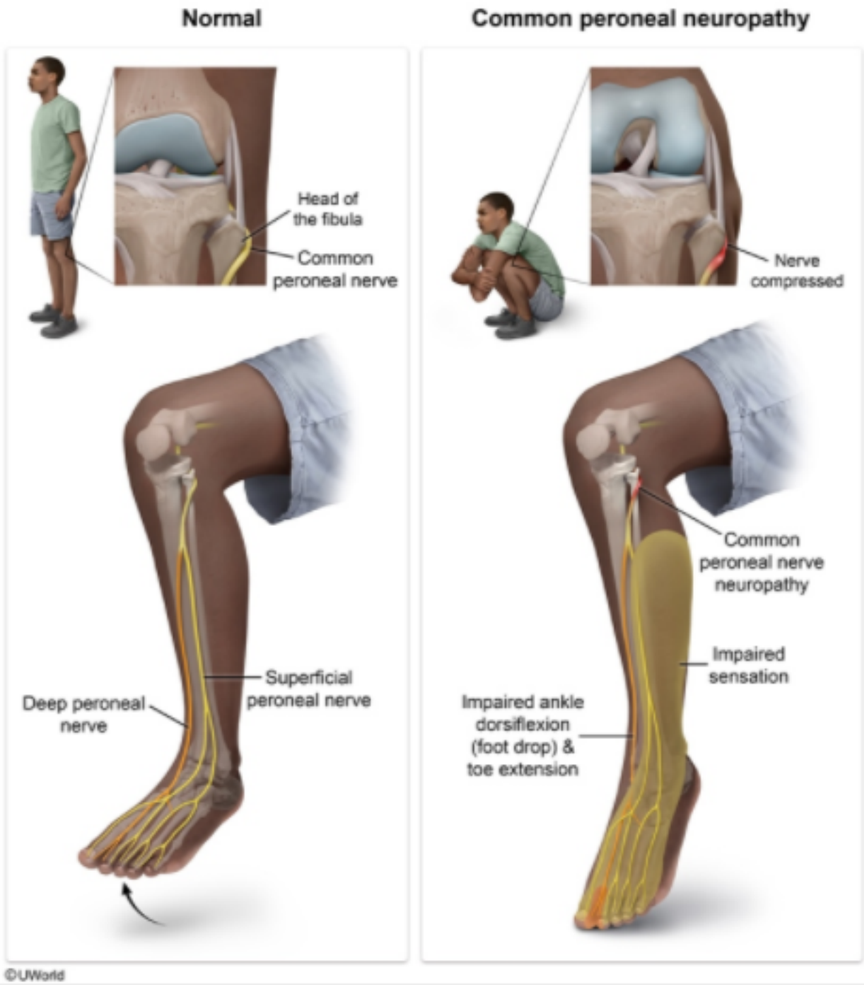

Zoom In | Zoom Out | Reset | Add To New Card | Existing Card

1
2
3
4
5
6
7
8
9
10
11
12
13
14
15
16
17
18
19
20
21
22
23
24
25
26
27
28
29
30
31

A 43-year-old woman comes to the office due to acute back pain after dragging a heavy box. The pain is located in her lower back and radiates down the right posterior thigh to the foot. The patient describes the pain as "shooting" and grades it 8/10 in intensity. She has no bowel or bladder symptoms. The patient has tried over-the-counter analgesics with limited symptomatic relief. Vital signs are within normal limits. On physical examination, straight leg raise testing is positive on the right. Right hip extension is weaker when compared to the left. Knee jerk reflexes are 2+ and bilaterally symmetric, but the right ankle jerk reflex is absent. Which of the following nerve roots is most likely affected in this patient?

A. L2
B. L3
C. L4
D. L5
E. S1

Submit

A 43-year-old woman comes to the office due to acute back pain after dragging a heavy box. The pain is located in her lower back and radiates down the right posterior thigh to the foot. The patient describes the pain as "shooting" and grades it 8/10 in intensity. She has no bowel or bladder symptoms. The patient has tried over-the-counter analgesics with limited symptomatic relief. Vital signs are within normal limits. On physical examination, straight leg raise testing is positive on the right. Right hip extension is weaker when compared to the left. Knee jerk reflexes are 2+ and bilaterally symmetric, but the right ankle jerk reflex is absent. Which of the following nerve roots is most likely affected in this patient?

- A. L2 (3%)
- B. L3 (2%)
- C. L4 (9%)
- D. L5 (13%)
- ✓ E. S1 (70%)

Omitted
Correct answer
E

70%
Answered correctly

02 secs
Time Spent

01/15/2020
Last Updated

Explanation

Features of lumbosacral radiculopathy			
Nerve Root	Reflex affected	Sensory loss*	Weakness
L2-L4**	• Patellar	• Anteromedial thigh	• Hip flexion (iliopsoas) • Hip adduction

1
2
3
4
5
6
7
8
9
10
11
12
13
14
15
16
17
18
19
20
21
22
23
24
25
26
27
28
29
30
31

Features of lumbosacral radiculopathy

Nerve Root	Reflex affected	Sensory loss*	Weakness
L2-L4**	• Patellar	• Anteromedial thigh • Medial shin	• Hip flexion (iliopsoas) • Hip adduction • Knee extension (quadriceps)
L5	• None	• Lateral shin • Dorsum of the foot	• Foot dorsiflexion & inversion (tibialis anterior) • Foot eversion (peroneus) • Toe extension (extensor hallucis and digitorum)
S1	• Achilles	• Posterior calf • Sole & lateral foot	• Hip extension (gluteus maximus) • Foot plantarflexion (gastrocnemius)
S2-S4**	• None	• Perineum	• Urinary or fecal incontinence • Sexual dysfunction

*Radicular pain typically has a similar distribution to sensory loss.

** Difficult to distinguish clinically.

This patient's presentation is consistent with **sciatica**, a nonspecific term for low back pain that radiates down the leg. This condition occurs due to compression of the lumbosacral nerve roots and is most commonly caused by vertebral disc herniation or spinal foraminal stenosis (eg, due to degenerative arthritis of the spine). Irritation of the nerve roots results in characteristic dermatomal and myotomal deficits (radiculopathy) depending on the level of involvement. Patients may have worsening of their radicular pain when the symptomatic leg is extended at the knee and the hip is passively flexed by the examiner (straight leg raise test).

The sciatic nerve is derived from the L4-S3 nerve roots and compression most often occurs at the level of L5 or S1. **S1 radiculopathy** is characterized by pain and sensory loss down the posterior thigh and calf to the lateral aspect of the foot. Patients may also have **weakness** on **thigh extension** (eg, due to denervation of the gluteus maximus), knee flexion (hamstrings), and foot plantarflexion (gastrocnemius) with an **absent ankle jerk reflex**. Conversely, compression of the L5 root results in pain/paresthesia radiating down the lateral thigh and calf to the dorsal

This patient's presentation is consistent with **sciatica**, a nonspecific term for low back pain that radiates down the leg. This condition occurs due to compression of the lumbosacral nerve roots and is most commonly caused by vertebral disc herniation or spinal foraminal stenosis (eg, due to degenerative arthritis of the spine). Irritation of the nerve roots results in characteristic dermatomal and myotomal deficits (radiculopathy) depending on the level of involvement. Patients may have worsening of their radicular pain when the symptomatic leg is extended at the knee and the hip is passively flexed by the examiner (straight leg raise test).

The sciatic nerve is derived from the L4-S3 nerve roots and compression most often occurs at the level of L5 or S1. **S1 radiculopathy** is characterized by pain and sensory loss down the posterior thigh and calf to the lateral aspect of the foot. Patients may also have **weakness** on **thigh extension** (eg, due to denervation of the gluteus maximus), knee flexion (hamstrings), and foot plantarflexion (gastrocnemius) with an **absent ankle jerk reflex**. Conversely, compression of the L5 root results in pain/paresthesia radiating down the lateral thigh and calf to the dorsal foot. Patients often have weakness on foot dorsiflexion and inversion (eg, due to denervation of the tibialis anterior), foot eversion (peroneus), and toe extension (extensor digitorum brevis) **(Choice D)**.

(Choices A and B) Patients with L2 or L3 radiculopathy typically have pain radiating down the anterior thigh with weakness on hip flexion (eg, due to denervation of the iliopsoas). Knee and ankle jerk reflexes usually remain intact.

(Choice C) L4 radiculopathy typically presents with pain/paresthesia radiating down the anterior thigh to the medial lower leg and foot. Patients can also have weakness on knee extension (eg, due to denervation of the quadriceps) with a diminished knee jerk reflex.

Educational objective:
Sciatica is a nonspecific term for low back pain that radiates down the leg due to compression of the lumbosacral nerve roots (eg, from vertebral disc herniation). The S1 nerve root is commonly involved, resulting in pain/sensory loss down the posterior thigh and calf to the lateral aspect of the foot. Patients may also have weakness on thigh extension, knee flexion, and foot plantarflexion with an absent ankle jerk reflex.

References

- Diagnosis and treatment of sciatica.
- Comparison of surgical and electrodiagnostic findings in single root lumbosacral radiculopathies.

Anatomy Nervous System Radiculopathy

1
2
3
4
5
6
7
8
9
10
11
12
13
14
15
16
17
18
19
20
21
22
23
24
25
26
27
28
29
30
31

A 66-year-old man develops transient, painless vision loss in the left eye. He has a history of hypertension, hyperlipidemia, and type 2 diabetes mellitus. Evaluation reveals significant stenosis of the left internal carotid artery due to atherosclerotic plaque. Carotid endarterectomy is performed. During the surgery, the left glossopharyngeal nerve is accidentally transected. Which of the following is most likely to be seen due to the nerve injury?

A. Deviation of the protruded tongue toward the left

B. Hoarseness due to left vocal cord dysfunction

C. Impaired taste sensation from the anterior two-thirds of the tongue

D. Loss of general sensation at the tonsillar lining

E. Reduced salivary secretion from the submandibular gland

Submit

A 66-year-old man develops transient, painless vision loss in the left eye. He has a history of hypertension, hyperlipidemia, and type 2 diabetes mellitus. Evaluation reveals significant stenosis of the left internal carotid artery due to atherosclerotic plaque. Carotid endarterectomy is performed. During the surgery, the left glossopharyngeal nerve is accidentally transected. Which of the following is most likely to be seen due to the nerve injury?

- A. Deviation of the protruded tongue toward the left (17%)
- B. Hoarseness due to left vocal cord dysfunction (9%)
- C. Impaired taste sensation from the anterior two-thirds of the tongue (6%)
- ✓ D. Loss of general sensation at the tonsillar lining (56%)
- E. Reduced salivary secretion from the submandibular gland (9%)

Omitted
Correct answer
D

56%
Answered correctly

01 sec
Time Spent

03/15/2020
Last Updated

Explanation

The **glossopharyngeal nerve**, or cranial nerve (CN) IX, originates in the medulla and exits the cranial cavity via the jugular foramen. This nerve has numerous functions, including:

- Somatic motor: Stylopharyngeus muscle only (elevates larynx during swallowing)
- Parasympathetic: Inferior salivatory nucleus → CN IX → otic ganglion → travels along auriculotemporal nerve (CN V) → parotid gland secretion
- General sensory: Tympanic membrane (inner surface), eustachian tube, posterior third of tongue, tonsillar region, upper pharynx (afferent

The **glossopharyngeal nerve**, or cranial nerve (CN) IX, originates in the medulla and exits the cranial cavity via the jugular foramen. This nerve has numerous functions, including:

- Somatic motor: Stylopharyngeus muscle only (elevates larynx during swallowing)
- Parasympathetic: Inferior salivatory nucleus → CN IX → otic ganglion → travels along auriculotemporal nerve (CN V) → parotid gland secretion
- General sensory: Tympanic membrane (inner surface), eustachian tube, posterior third of tongue, tonsillar region, upper pharynx (afferent portion of gag reflex), carotid body, and carotid sinus
- Special sensory (taste): Posterior third of tongue

Glossopharyngeal nerve lesions therefore result in loss of the **gag reflex** (afferent limb); loss of general sensation in the upper pharynx, posterior tongue, **tonsils**, and middle ear cavity; and loss of **taste** sensation on the **posterior** third of the tongue.

(Choice A) Protrusion of the tongue is mediated by motor efferent fibers carried by the hypoglossal nerve (CN XII).

(Choice B) The muscles of the larynx are innervated predominantly by the vagus nerve and its branches (particularly the recurrent laryngeal nerve).

(Choice C) Taste sensation from the anterior two-thirds of the tongue is mediated by the chorda tympani branch of the facial nerve (CN VII).

(Choice E) Salivary secretion from the submandibular and sublingual glands is mediated by parasympathetic fibers originating in the superior salivatory nucleus carried on the facial nerve (CN VII) via the chorda tympani and lingual nerves across the submandibular ganglion.

Educational objective:
Lesions of the glossopharyngeal nerve result in loss of the gag reflex (afferent limb); loss of sensation in the upper pharynx, posterior tongue, tonsils, and middle ear cavity; and loss of taste sensation on the posterior third of the tongue.

Anatomy	Nervous System	Cranial nerve palsy
Subject	System	Topic

Copyright © UWorld. All rights reserved.

1
2
3
4
5
6
7
8
9
10
11
12
13
14
15
16
17
18
19
20
21
22
23
24
25
26
27
28
29
30
31

A 15-year-old girl is brought to the hospital due to sudden onset of severe left leg pain. She was practicing for an upcoming gymnastics competition when she felt a popping sensation after landing from a jump and developed anterior left leg pain. Following the injury, the patient was unable to bear weight on the leg. Physical examination shows swelling of the left knee with focal tenderness just above the patella. She is unable to raise the left leg against gravity while in the supine position. Imaging confirms a complete tear of the quadriceps tendon, but no fractures are identified. Surgical repair is planned. Lidocaine injection near which of the following sites is most likely to provide adequate anesthesia for the procedure?

A. Adductor canal
B. Inguinal ligament
C. Ischial spine tip
D. Medial tibial condyle
E. Obturator canal

Submit

1
2
3
4
5
6
7
8
9
10
11
12
13
14
15
16
17
18
19
20
21
22
23
24
25
26
27
28
29
30
31

A 15-year-old girl is brought to the hospital due to sudden onset of severe left leg pain. She was practicing for an upcoming gymnastics competition when she felt a popping sensation after landing from a jump and developed anterior left leg pain. Following the injury, the patient was unable to bear weight on the leg. Physical examination shows swelling of the left knee with focal tenderness just above the patella. She is unable to raise the left leg against gravity while in the supine position. Imaging confirms a complete tear of the quadriceps tendon, but no fractures are identified. Surgical repair is planned. Lidocaine injection near which of the following sites is most likely to provide adequate anesthesia for the procedure?

- A. Adductor canal (11%)
- ✓ B. Inguinal ligament (53%)
- C. Ischial spine tip (9%)
- D. Medial tibial condyle (12%)
- E. Obturator canal (13%)

Omitted
Correct answer
B

53%
Answered correctly

02 secs
Time Spent

01/24/2020
Last Updated

Explanation

1
2
3
4
5
6
7
8
9
10
11
12
13
14
15
16
17
18
19
20
21
22
23
24
25
26
27
28
29
30
31

Femoral triangle

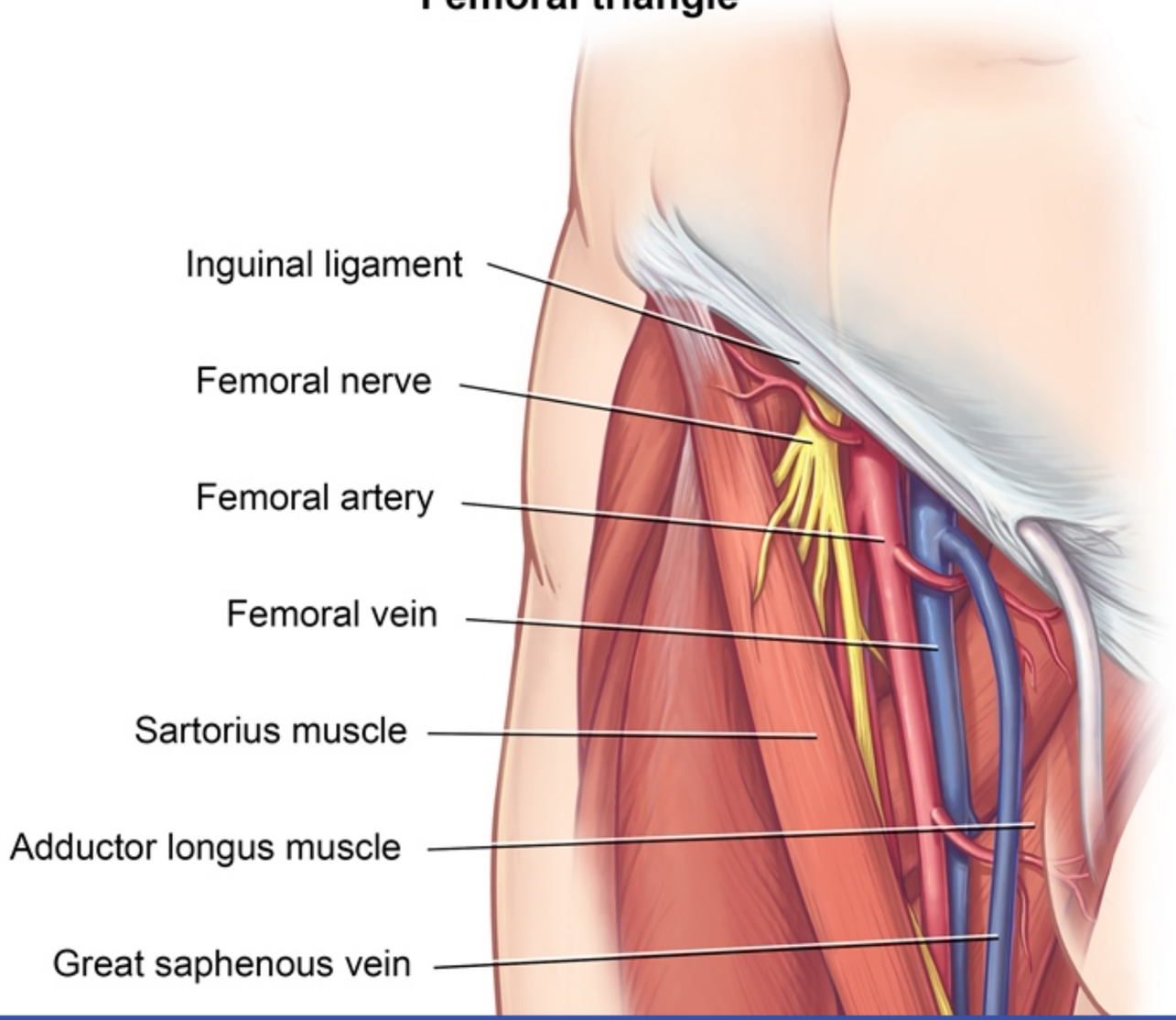

1
2
3
4
5
6
7
8
9
10
11
12
13
14
15
16
17
18
19
20
21
22
23
24
25
26
27
28
29
30
31

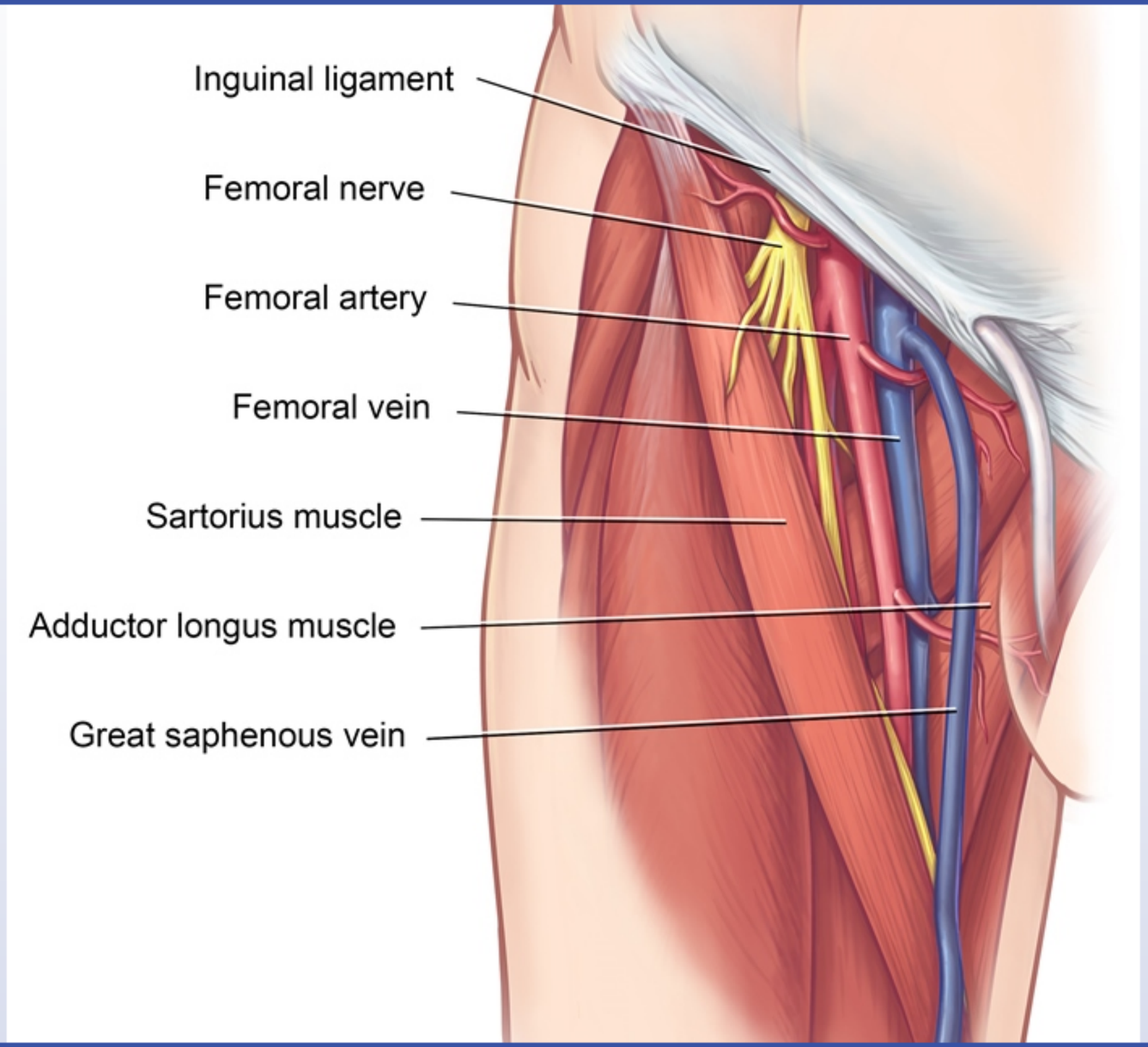

©UWorld

The femoral nerve (L2-L4) innervates the quadriceps muscles (enabling extension at the knee and flexion at the hip) and provides sensation for the arch of the foot, shin, and anteromedial thigh. The nerve emerges between the psoas and iliacus muscles and passes under the **inguinal ligament** (lateral to the femoral artery) into the thigh before branching in the femoral triangle into an anterior and posterior division.

The optimal site for a **femoral nerve block** is right below the inguinal ligament (ie, in the inguinal crease) at the lateral border of the femoral artery. Injecting at this site **anesthetizes** the skin and muscles of the **anterior thigh, femur, and knee** and can be used during repair of the quadriceps tendon. The block also anesthetizes structures supplied by the saphenous nerve (ie, the terminal extension of the femoral nerve) to decrease sensation in the medial leg below the knee.

(Choices A and D) The saphenous nerve (a branch of the femoral nerve that supplies sensation to the leg) can be anesthetized directly at the level of the adductor canal in the thigh (ie, adductor canal block) or at the medial tibial condyle in the knee (ie, saphenous nerve block). However, the branches of the femoral nerve that supply the knee arise proximal to the saphenous nerve and would not be anesthetized by injection at these locations.

(Choice C) The ischial spine divides the greater and lesser sciatic foramina in the bony pelvis. The ischial spine tip is a landmark for pudendal nerve block, which is used for anesthesia during vaginal deliveries and for minor surgeries of the vagina and perineum.

(Choice E) The obturator canal is a small gap in the obturator membrane (ie, the fibrous sheet covering the obturator foramen) that allows the obturator artery, obturator vein, and obturator nerve to travel from the pelvis to the thigh. An obturator nerve block would anesthetize the adductor muscles of the thigh and the skin of the medial aspect of the thigh but would not affect the quadriceps muscles or sensation to the knee.

Educational objective:
A femoral nerve block below the inguinal ligament (ie, in the inguinal crease) will anesthetize the skin and muscles of the anterior thigh, femur, and knee. This type of block can be used in patients requiring tendon repair after a knee injury (eg, quadriceps rupture).

References

- Anatomical landmarks for femoral nerve block: a comparison of four needle insertion sites.

Anatomy Nervous System Anesthesia

1
2
3
4
5
6
7
8
9
10
11
12
13
14
15
16
17
18
19
20
21
22
23
24
25
26
27
28
29
30
31

Exhibit Display

Femoral nerve and lateral femoral cutaneous nerve

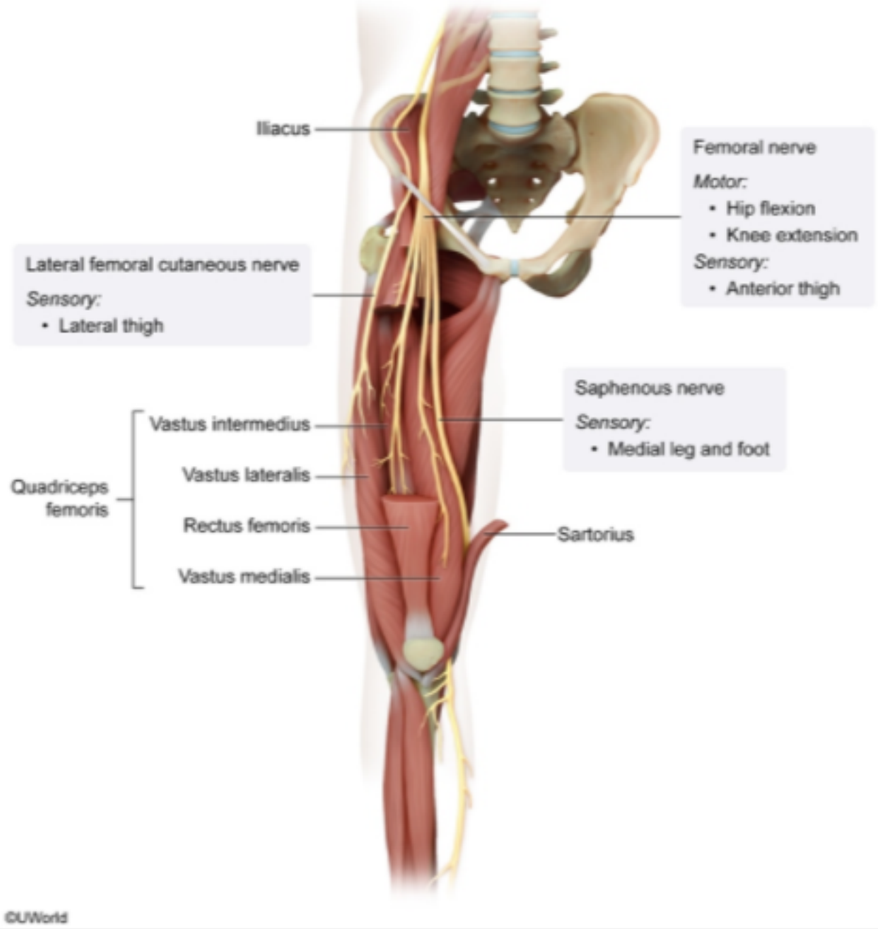

Zoom In | Zoom Out | Reset | Add To New Card | Existing Card

Anatomy | Nervous System | Anesthesia

1
2
3
4
5
6
7
8
9
10
11
12
13
14
15
16
17
18
19
20
21
22
23
24
25
26
27
28
29
30
31

Exhibit Display

Pudendal nerve block

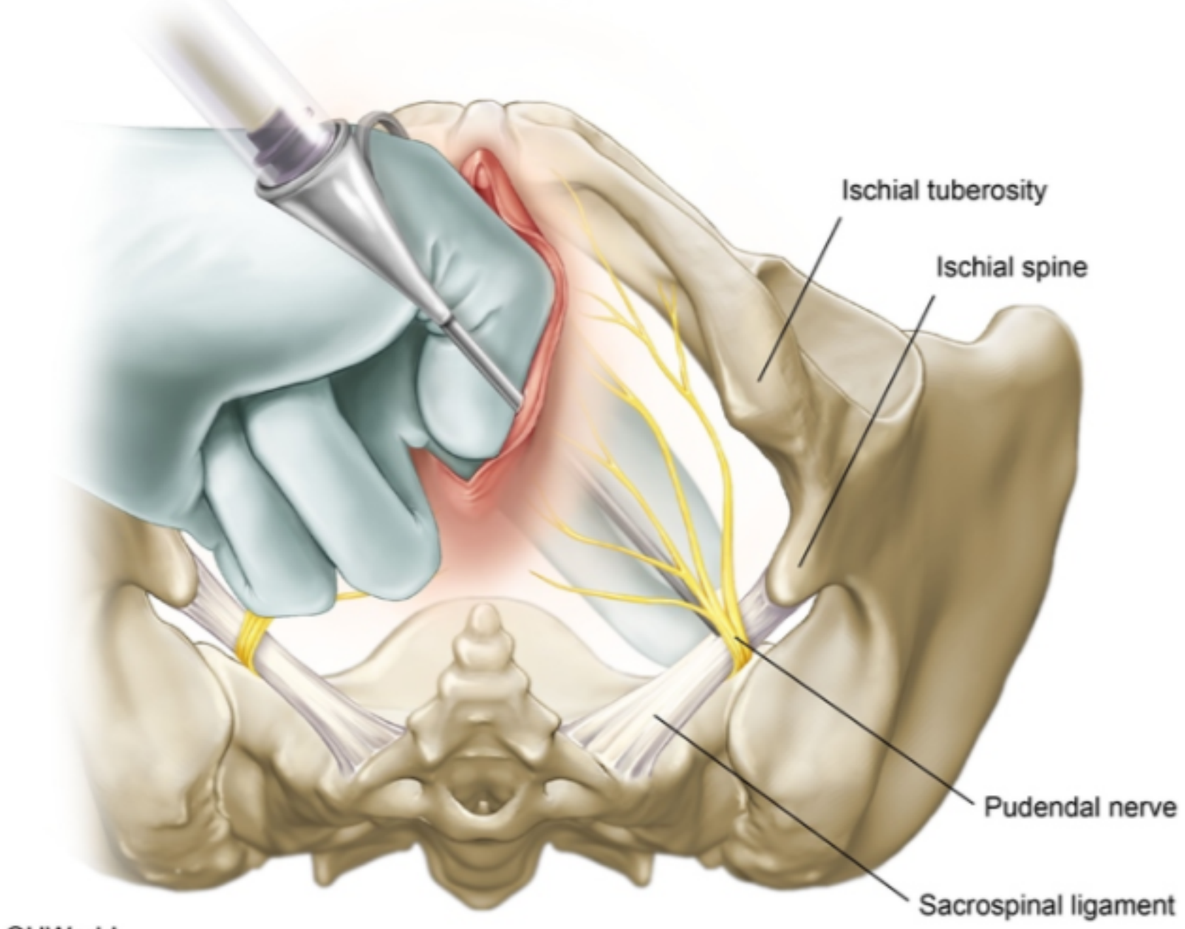

©UWorld

Zoom In | Zoom Out | Reset | Add To New Card | Existing Card

Anatomy | Nervous System | Anesthesia

1
2
3
4
5
6
7
8
9
10
11
12
13
14
15
16
17
18
19
20
21
22
23
24
25
26
27
28
29
30
31

A 4-day-old premature infant in the neonatal intensive care unit becomes hypotonic and less responsive. She was delivered vaginally at 30 weeks gestation, and her birth weight was 1,200 g (2 lb 10 oz). Physical examination shows a lethargic infant with weak and high-pitched crying, prominent scalp veins, and tense fontanelles. Cranial ultrasound reveals blood in the lateral ventricles. Which of the following structures is the most likely source of the bleeding?

A. Bridging cortical veins

B. Germinal matrix

C. Meningeal arteries

D. Sagittal sinus

E. Vessels of the circle of Willis

Submit

1
2
3
4
5
6
7
8
9
10
11
12
13
14
15
16
17
18
19
20
21
22
23
24
25
26
27
28
29
30
31

A 4-day-old premature infant in the neonatal intensive care unit becomes hypotonic and less responsive. She was delivered vaginally at 30 weeks gestation, and her birth weight was 1,200 g (2 lb 10 oz). Physical examination shows a lethargic infant with weak and high-pitched crying, prominent scalp veins, and tense fontanelles. Cranial ultrasound reveals blood in the lateral ventricles. Which of the following structures is the most likely source of the bleeding?

A. Bridging cortical veins (13%)
✓ B. Germinal matrix (60%)
C. Meningeal arteries (5%)
D. Sagittal sinus (13%)
E. Vessels of the circle of Willis (7%)

Omitted
Correct answer
B

60%
Answered correctly

02 secs
Time Spent

02/13/2020
Last Updated

Explanation

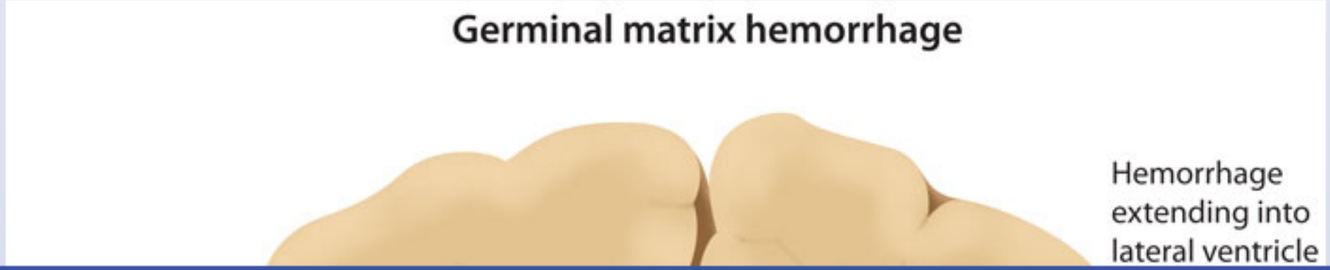

1
2
3
4
5
6
7
8
9
10
11
12
13
14
15
16
17
18
19
20
21
22
23
24
25
26
27
28
29
30
31

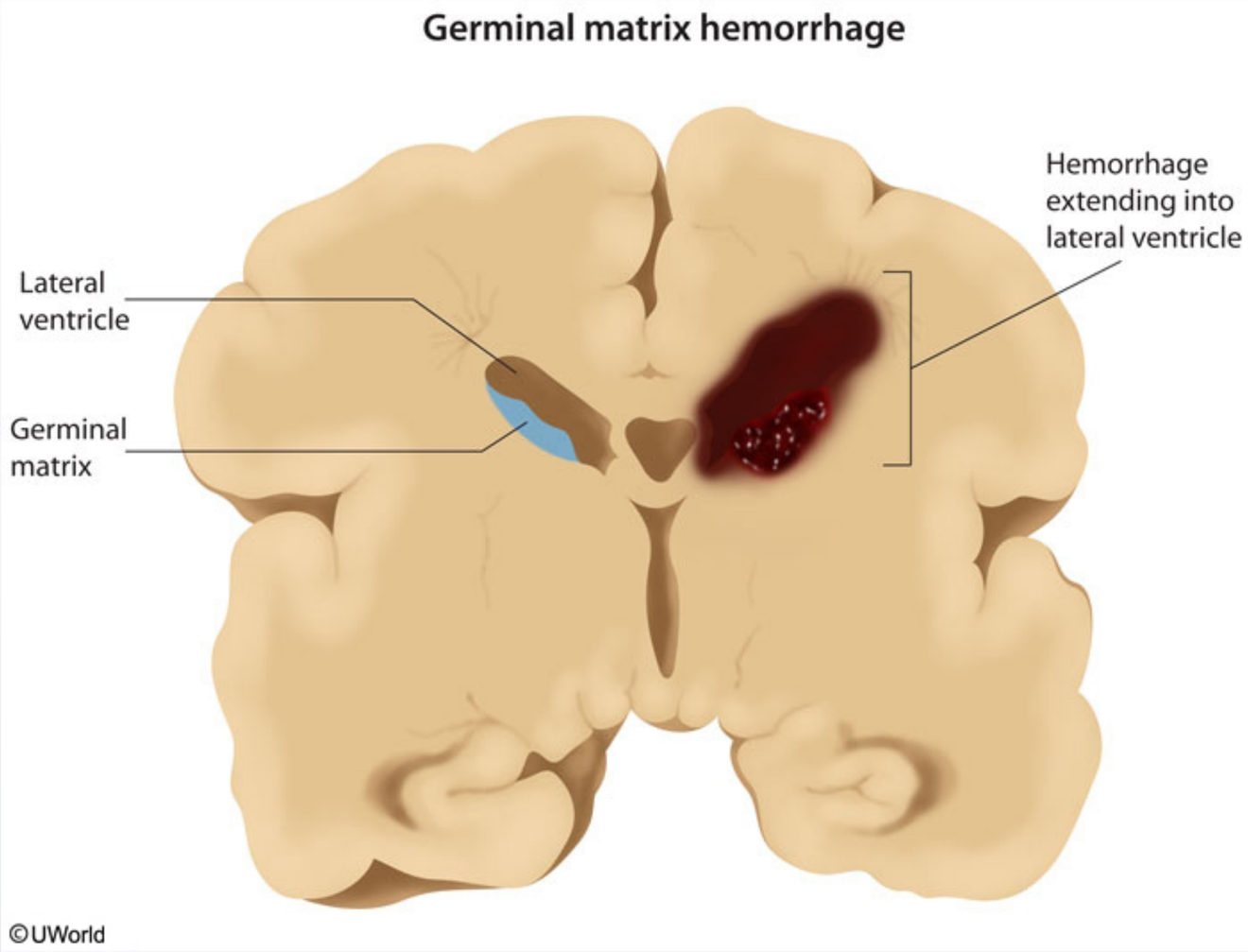

Intraventricular hemorrhage (IVH) is a common complication of prematurity that can lead to long-term impairment in neurodevelopment. IVH almost always manifests within the first 5 postnatal days in infants born **before 32 weeks gestation** and/or with **birth weight <1,500 g** (3 lb 5 oz). IVH in a newborn can be clinically silent or present with altered level of consciousness, hypotonia, and decreased spontaneous movements. If the

Intraventricular hemorrhage (IVH) is a common complication of prematurity that can lead to long-term impairment in neurodevelopment. IVH almost always manifests within the first 5 postnatal days in infants born **before 32 weeks gestation** and/or with **birth weight <1,500 g** (3 lb 5 oz). IVH in a newborn can be clinically silent or present with altered level of consciousness, hypotonia, and decreased spontaneous movements. If the bleeding is severe, catastrophic deterioration can occur with a **bulging anterior fontanelle**, hypotension, tonic-clonic seizures, irregular respirations, and coma.

IVH in preterm infants usually originates from the **germinal matrix**, a highly cellular and vascularized layer in the subventricular zone (source of neurons and glial cells during brain development). The matrix contains numerous fragile, thin-walled vessels lacking the glial fibers that support other blood vessels throughout the brain, making them more **susceptible to hemorrhage**. Between 24-32 weeks gestation, the germinal matrix starts to become less prominent, and its cellularity and vascularity decrease, leading to a reduced risk of IVH in infants born after 32 weeks.

(Choices A and C) In neonates, an assisted delivery (eg, forceps, vacuum) can result in subdural hematoma (cortical bridging veins) or epidural hematoma (middle meningeal artery). Both can cause bulging fontanelles and altered level of consciousness but are characterized by hematomas over the cerebral convexities rather than blood in the lateral ventricles.

(Choice D) The sagittal sinus and other dural venous sinuses are channels found between layers of dura mater in the brain. Certain conditions (eg, malignancy, hypercoagulable states, infection) can result in thrombosis within the dural sinuses; however, intraventricular bleeding would not be seen.

(Choice E) A ruptured saccular (berry) aneurysm at a branch point in vessels of the circle of Willis is the most common cause of spontaneous subarachnoid hemorrhage (SAH). Aneurysmal SAH is rare in infants and is associated with blood in the basal cisterns rather than the lateral ventricles.

Educational objective:
Neonatal intraventricular hemorrhage usually originates from the fragile germinal matrix in infants born before 32 weeks gestation and/or with birth weight <1,500 g (3 lb 5 oz). It is a common complication of prematurity that can lead to long-term neurodevelopmental impairment.

Anatomy	Nervous System	Intraventricular hemorrhage
Subject	System	Topic

Copyright © UWorld. All rights reserved.

1
2
3
4
5
6
7
8
9
10
11
12
13
14
15
16
17
18
19
20
21
22
23
24
25
26
27
28
29
30
31

A 23-year-old woman is brought to the emergency department unconscious after a motor vehicle accident. The patient was texting on her cell phone and was not wearing a seatbelt during the incident. She has no known medical problems and takes no medications. Her temperature is 36.7 C (98 F), blood pressure is 155/90 mm Hg, pulse is 62/min, and respirations are 10/min. A linear skull fracture at the junction of the frontal, parietal, temporal, and sphenoid bones is seen on head CT scan. A branch of which of the following arteries is most likely severed in this patient?

A. Facial
B. Maxillary
C. Middle cerebral
D. Occipital
E. Ophthalmic
F. Sphenopalatine

Submit

1
2
3
4
5
6
7
8
9
10
11
12
13
14
15
16
17
18
19
20
21
22
23
24
25
26
27
28
29
30
31

A 23-year-old woman is brought to the emergency department unconscious after a motor vehicle accident. The patient was texting on her cell phone and was not wearing a seatbelt during the incident. She has no known medical problems and takes no medications. Her temperature is 36.7 C (98 F), blood pressure is 155/90 mm Hg, pulse is 62/min, and respirations are 10/min. A linear skull fracture at the junction of the frontal, parietal, temporal, and sphenoid bones is seen on head CT scan. A branch of which of the following arteries is most likely severed in this patient?

A. Facial (10%)
✓ B. Maxillary (47%)
C. Middle cerebral (28%)
D. Occipital (1%)
E. Ophthalmic (4%)
F. Sphenopalatine (6%)

Omitted
Correct answer
B

47%
Answered correctly

02 secs
Time Spent

05/24/2020
Last Updated

Explanation

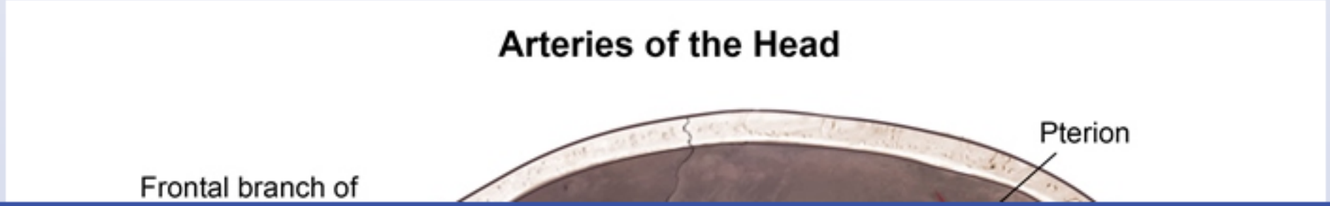

1
2
3
4
5
6
7
8
9
10
11
12
13
14
15
16
17
18
19
20
21
22
23
24
25
26
27
28
29
30
31

Arteries of the Head

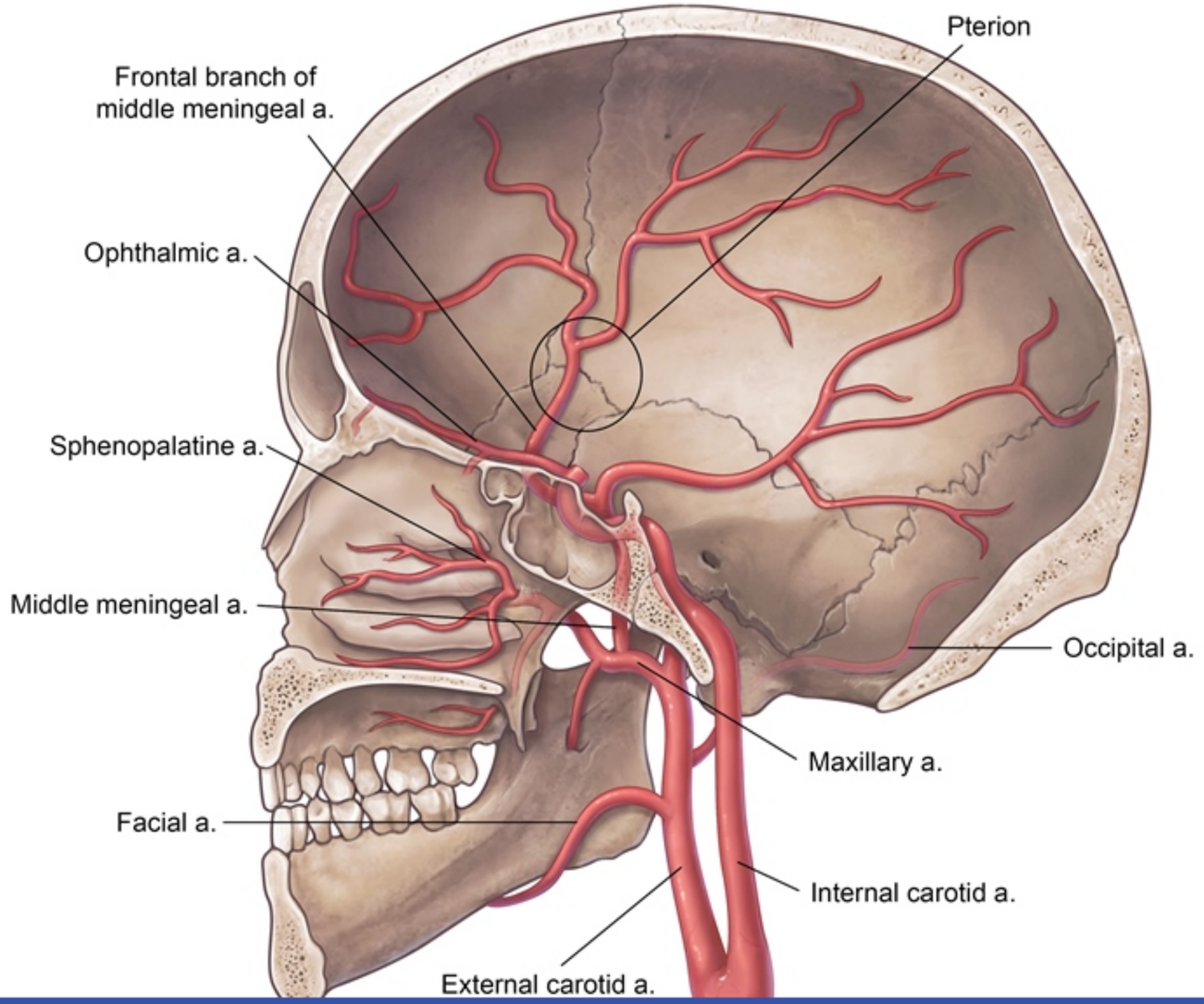

This patient has suffered a **fracture** at the **pterion**, a region where the frontal, parietal, temporal, and sphenoid bones meet in the skull. The bone is thin in this region, and fractures there risk lacerating the **middle meningeal artery** and causing an epidural hematoma. Epidural hematomas require prompt treatment as they are under systemic arterial pressure and can expand rapidly, leading to elevated intracranial pressure (can cause Cushing reflex), brain herniation (eg, uncal herniation with oculomotor nerve palsy), and death.

The middle meningeal artery is a branch of the **maxillary artery** (one of the terminal branches of the external carotid artery), which enters the skull at the foramen spinosum and supplies the dura mater and periosteum.

(Choice A) The facial artery is a branch of the external carotid artery, which courses over the mandible anterior to the insertion of the masseter muscle to supply the oral, nasal, and buccal regions.

(Choice C) The middle cerebral artery is a branch of the internal carotid artery and supplies much of the parietal and temporal regions of the brain. Injury to this artery or its branches can cause subarachnoid or intracerebral hemorrhage.

(Choice D) The occipital artery arises opposite the facial artery from the external carotid, coursing posteriorly instead of anteriorly. This vessel supplies the posterior scalp and the sternocleidomastoid muscles.

(Choice E) The ophthalmic artery is the first branch of the internal carotid artery, supplying the eye and orbital contents as well as the eyelids, forehead, and nose. The internal carotid artery has no branches in the neck.

(Choice F) The sphenopalatine artery is a branch of the third part of the maxillary artery and supplies much of the nasal mucosa. It anastomoses with branches of the ophthalmic and facial arteries within the anterior part of the nasal septum in a region known as Kiesselbach's plexus (a frequent site of nosebleeds).

Educational objective:
The middle meningeal artery is a branch of the maxillary artery, which enters the skull at the foramen spinosum and courses intracranially deep to the pterion (where the frontal, parietal, temporal, and sphenoid bones meet). Skull fractures at this site may cause laceration of this vessel, leading to an epidural hematoma.

References

- Clinical importance of the middle meningeal artery.

The middle meningeal artery is a branch of the **maxillary artery** (one of the terminal branches of the external carotid artery), which enters the skull at the foramen spinosum and supplies the dura mater and periosteum.

(Choice A) The facial artery is a branch of the external carotid artery, which courses over the mandible anterior to the insertion of the masseter muscle to supply the oral, nasal, and buccal regions.

(Choice C) The middle cerebral artery is a branch of the internal carotid artery and supplies much of the parietal and temporal regions of the brain. Injury to this artery or its branches can cause subarachnoid or intracerebral hemorrhage.

(Choice D) The occipital artery arises opposite the facial artery from the external carotid, coursing posteriorly instead of anteriorly. This vessel supplies the posterior scalp and the sternocleidomastoid muscles.

(Choice E) The ophthalmic artery is the first branch of the internal carotid artery, supplying the eye and orbital contents as well as the eyelids, forehead, and nose. The internal carotid artery has no branches in the neck.

(Choice F) The sphenopalatine artery is a branch of the third part of the maxillary artery and supplies much of the nasal mucosa. It anastomoses with branches of the ophthalmic and facial arteries within the anterior part of the nasal septum in a region known as Kiesselbach's plexus (a frequent site of nosebleeds).

Educational objective:
The middle meningeal artery is a branch of the maxillary artery, which enters the skull at the foramen spinosum and courses intracranially deep to the pterion (where the frontal, parietal, temporal, and sphenoid bones meet). Skull fractures at this site may cause laceration of this vessel, leading to an epidural hematoma.

References

- Clinical importance of the middle meningeal artery.

Anatomy	Nervous System	Epidural hematoma
Subject	System	Topic

Copyright © UWorld. All rights reserved.

1
2
3
4
5
6
7
8
9
10
11
12
13
14
15
16
17
18
19
20
21
22
23
24
25
26
27
28
29
30
31

A 46-year-old man comes to the office with left upper limb weakness and numbness. He has had chronic neck pain since being involved in a motor vehicle collision 4 years ago. He has no other medical problems. Neurological evaluation reveals that the tendon reflex shown in the image below is absent. Reflexes in the right upper extremity and both lower extremities are normal.

Imaging studies reveal degenerative changes in the spine causing mild spinal cord compression. Which of the following spinal segments is most likely affected in this patient?

A. C3-C4
B. C5-C6
C. C7-C8
D. C8-T1
E. T1-T2

Submit

1
2
3
4
5
6
7
8
9
10
11
12
13
14
15
16
17
18
19
20
21
22
23
24
25
26
27
28
29
30
31

A 46-year-old man comes to the office with left upper limb weakness and numbness. He has had chronic neck pain since being involved in a motor vehicle collision 4 years ago. He has no other medical problems. Neurological evaluation reveals that the tendon reflex shown in the image below is absent. Reflexes in the right upper extremity and both lower extremities are normal.

Imaging studies reveal degenerative changes in the spine causing mild spinal cord compression. Which of the following spinal segments is most likely affected in this patient?

A. C3-C4 (4%)
✓ B. C5-C6 (85%)
C. C7-C8 (6%)
D. C8-T1 (2%)
E. T1-T2 (0%)

Omitted
Correct answer
B

85%
Answered correctly

03 secs
Time Spent

05/10/2020
Last Updated

Myotomes & reflexes of the upper extremity		
Myotomes	C4	Shoulder/scapula elevation
	C5	Shoulder abduction
	C5, C6	Elbow flexion, wrist extension
	C7	Elbow extension, finger extension
	C8	Wrist flexion, finger flexion
	T1	Finger abduction
Reflexes	C5, C6	Biceps & brachioradialis reflexes
	C7, C8	Triceps reflex

©UWorld

This patient has an absent **biceps reflex**. The test is performed by quickly tapping a reflex hammer against the biceps brachii tendon as it passes through the cubital fossa. This action activates the muscle's stretch receptors that communicate via the musculocutaneous nerve with lower motor neurons in the anterior horn of the **C5-C6 spinal level**.

Axons from these motor neurons return along the musculocutaneous nerve and cause involuntary biceps muscle contraction and jerking of the forearm. The C5-C6 nerves also control the brachioradialis reflex. A stronger than normal reflex suggests an upper motor neuron lesion whereas an absent or decreased reflex indicates a lower motor neuron lesion at the corresponding spinal cord level.

	C8	Wrist flexion, finger flexion
	T1	Finger abduction
Reflexes	C5, C6	Biceps & brachioradialis reflexes
	C7, C8	Triceps reflex

©UWorld

This patient has an absent **biceps reflex**. The test is performed by quickly tapping a reflex hammer against the biceps brachii tendon as it passes through the cubital fossa. This action activates the muscle's stretch receptors that communicate via the musculocutaneous nerve with lower motor neurons in the anterior horn of the **C5-C6 spinal level**.

Axons from these motor neurons return along the musculocutaneous nerve and cause involuntary biceps muscle contraction and jerking of the forearm. The C5-C6 nerves also control the brachioradialis reflex. A stronger than normal reflex suggests an upper motor neuron lesion whereas an absent or decreased reflex indicates a lower motor neuron lesion at the corresponding spinal cord level.

(Choice A) The C3-C4 cervical nerves provide innervation to the diaphragm but do not mediate any specific reflexes.

(Choices C, D, and E) The C7, C8, and T1 spinal nerve roots form the median and ulnar nerves, which provide motor innervation to the wrist and hand. The T1 and T2 thoracic nerves innervate the rib muscles around the sternum, parts of the axilla, and part of the scapula. However, none of these spinal nerves mediate significant reflexes.

Educational objective:
The C5-C6 spinal nerves mediate the biceps and brachioradialis reflexes.

Anatomy	Nervous System	Radiculopathy
Subject	System	Topic

Copyright © UWorld. All rights reserved.

1
2
3
4
5
6
7
8
9
10
11
12
13
14
15
16
17
18
19
20
21
22
23
24
25
26
27
28
29
30
31

A 75-year-old man is brought to the emergency department after he was found unresponsive at home. The patient has a history of poorly controlled hypertension. Blood pressure is 240/120 mm Hg and pulse is 104 /min. He has extensor posturing and pinpoint pupils. CT scan of the head without contrast reveals an acute pontine hemorrhage with associated mass effect. The patient dies several hours later. Autopsy reveals disruption of all pigmented neurons in the posterior rostral pons at the lateral floor of the fourth ventricle. These neurons normally produce which of the following?

A. Dopamine
B. Dynorphin
C. Epinephrine
D. Histamine
E. Norepinephrine
F. Orexin
G. Oxytocin
H. Vasopressin

Submit

1
2
3
4
5
6
7
8
9
10
11
12
13
14
15
16
17
18
19
20
21
22
23
24
25
26
27
28
29
30
31

A 75-year-old man is brought to the emergency department after he was found unresponsive at home. The patient has a history of poorly controlled hypertension. Blood pressure is 240/120 mm Hg and pulse is 104 /min. He has extensor posturing and pinpoint pupils. CT scan of the head without contrast reveals an acute pontine hemorrhage with associated mass effect. The patient dies several hours later. Autopsy reveals disruption of all pigmented neurons in the posterior rostral pons at the lateral floor of the fourth ventricle. These neurons normally produce which of the following?

A. Dopamine (49%)
B. Dynorphin (6%)
C. Epinephrine (3%)
D. Histamine (1%)
✓ E. Norepinephrine (25%)
F. Orexin (8%)
G. Oxytocin (1%)
H. Vasopressin (3%)

Omitted
Correct answer
E

25%
Answered correctly

02 secs
Time Spent

02/12/2020
Last Updated

Explanation

This patient had a hypertensive hemorrhage in the pons at the level of the **locus ceruleus**, a paired pigmented brainstem nucleus located in the

1
2
3
4
5
6
7
8
9
10
11
12
13
14
15
16
17
18
19
20
21
22
23
24
25
26
27
28
29
30
31

This patient had a hypertensive hemorrhage in the pons at the level of the **locus ceruleus**, a paired pigmented brainstem nucleus located in the **posterior rostral pons** near the **lateral floor of the fourth ventricle**. The locus ceruleus functions as the principal site for **norepinephrine** synthesis in the brain and projects to virtually all parts of the central nervous system. It is involved in the control of mood, **arousal** (reticular activating system), sleep-wake states, cognition, and autonomic function (eg, blood pressure control). Abnormal activation of the locus ceruleus has been implicated in the pathogenesis of anxiety disorders (eg, panic attacks).

Patients with bilateral pontine hemorrhage typically present with coma due to disruption of the **reticular activating system**. Other features usually include total paralysis with extensor posturing due to corticospinal and corticobulbar tract injury and pinpoint pupils secondary to descending sympathetic tract damage.

(Choice A) Dopamine is produced in the ventral tegmental area and substantia nigra pars compacta located in the midbrain. The major dopaminergic pathways in the brain include the mesolimbic and mesocortical pathways (regulate cognition and behavior), the nigrostriatal pathway (regulates coordination of voluntary movements), and the tuberoinfundibular pathway (inhibits prolactin secretion).

(Choice B) Dynorphin is an opioid peptide that modulates the pain response. It is produced mostly in the periaqueductal gray, rostral ventral medulla, and dorsal horn of the spinal cord.

(Choice C) Norepinephrine is converted to epinephrine primarily in the adrenal medullae. Both of these neurotransmitters are released by the adrenal glands into the circulation after stimulation by sympathetic cholinergic preganglionic neurons.

(Choices D and F) Histamine and orexin are produced in the posterior hypothalamus and play an important role in arousal and wakefulness.

(Choices G and H) Oxytocin and vasopressin (antidiuretic hormone) are hormones produced by the hypothalamus and released from the posterior pituitary. Oxytocin promotes milk letdown and uterine contractions, whereas vasopressin causes vasoconstriction and free water reabsorption in the renal collecting ducts.

Educational objective:
The locus ceruleus is a paired brainstem nucleus located in the posterior rostral pons near the lateral floor of the fourth ventricle and functions as the principal site for norepinephrine synthesis in the brain. It projects to virtually all parts of the central nervous system and helps control mood, arousal (reticular activating system), sleep-wake states, cognition, and autonomic function.

References

1
2
3
4
5
6
7
8
9
10
11
12
13
14
15
16
17
18
19
20
21
22
23
24
25
26
27
28
29
30
31

(Choice A) Dopamine is produced in the ventral tegmental area and substantia nigra pars compacta located in the midbrain. The major dopaminergic pathways in the brain include the mesolimbic and mesocortical pathways (regulate cognition and behavior), the nigrostriatal pathway (regulates coordination of voluntary movements), and the tuberoinfundibular pathway (inhibits prolactin secretion).

(Choice B) Dynorphin is an opioid peptide that modulates the pain response. It is produced mostly in the periaqueductal gray, rostral ventral medulla, and dorsal horn of the spinal cord.

(Choice C) Norepinephrine is converted to epinephrine primarily in the adrenal medullae. Both of these neurotransmitters are released by the adrenal glands into the circulation after stimulation by sympathetic cholinergic preganglionic neurons.

(Choices D and F) Histamine and orexin are produced in the posterior hypothalamus and play an important role in arousal and wakefulness.

(Choices G and H) Oxytocin and vasopressin (antidiuretic hormone) are hormones produced by the hypothalamus and released from the posterior pituitary. Oxytocin promotes milk letdown and uterine contractions, whereas vasopressin causes vasoconstriction and free water reabsorption in the renal collecting ducts.

Educational objective:
The locus ceruleus is a paired brainstem nucleus located in the posterior rostral pons near the lateral floor of the fourth ventricle and functions as the principal site for norepinephrine synthesis in the brain. It projects to virtually all parts of the central nervous system and helps control mood, arousal (reticular activating system), sleep-wake states, cognition, and autonomic function.

References

- Organization of the locus coeruleus-norepinephrine system.
- Functional neuroanatomy of the noradrenergic locus coeruleus: its roles in the regulation of arousal and autonomic function part I: principles of functional organisation.

Anatomy	Nervous System	Acute intracerebral hemorrhage
Subject	System	Topic

Copyright © UWorld. All rights reserved.

1
2
3
4
5
6
7
8
9
10
11
12
13
14
15
16
17
18
19
20
21
22
23
24
25
26
27
28
29
30
31

A 34-year-old man begins treatment with combination chemotherapy for Hodgkin lymphoma. Shortly thereafter, he experiences severe vomiting and requires intravenous fluid supplementation. Which of the following sites in the brain is most likely responsible for his symptoms?

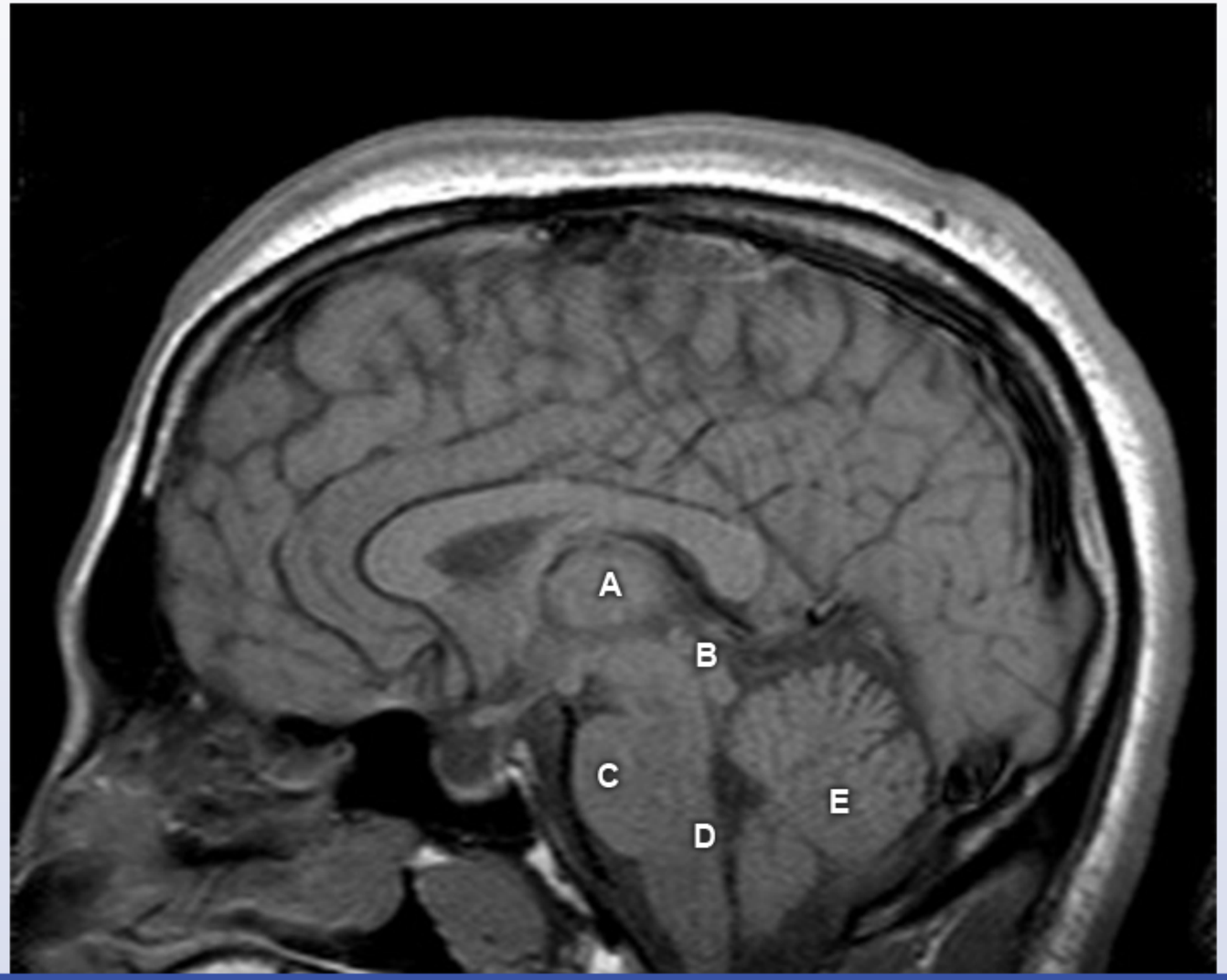

8
9
10
11
12
13
14
15
16
17
18
19
20
21
22
23
24
25
26
27
28
29
30
31
32
33
34
35
36
37
38

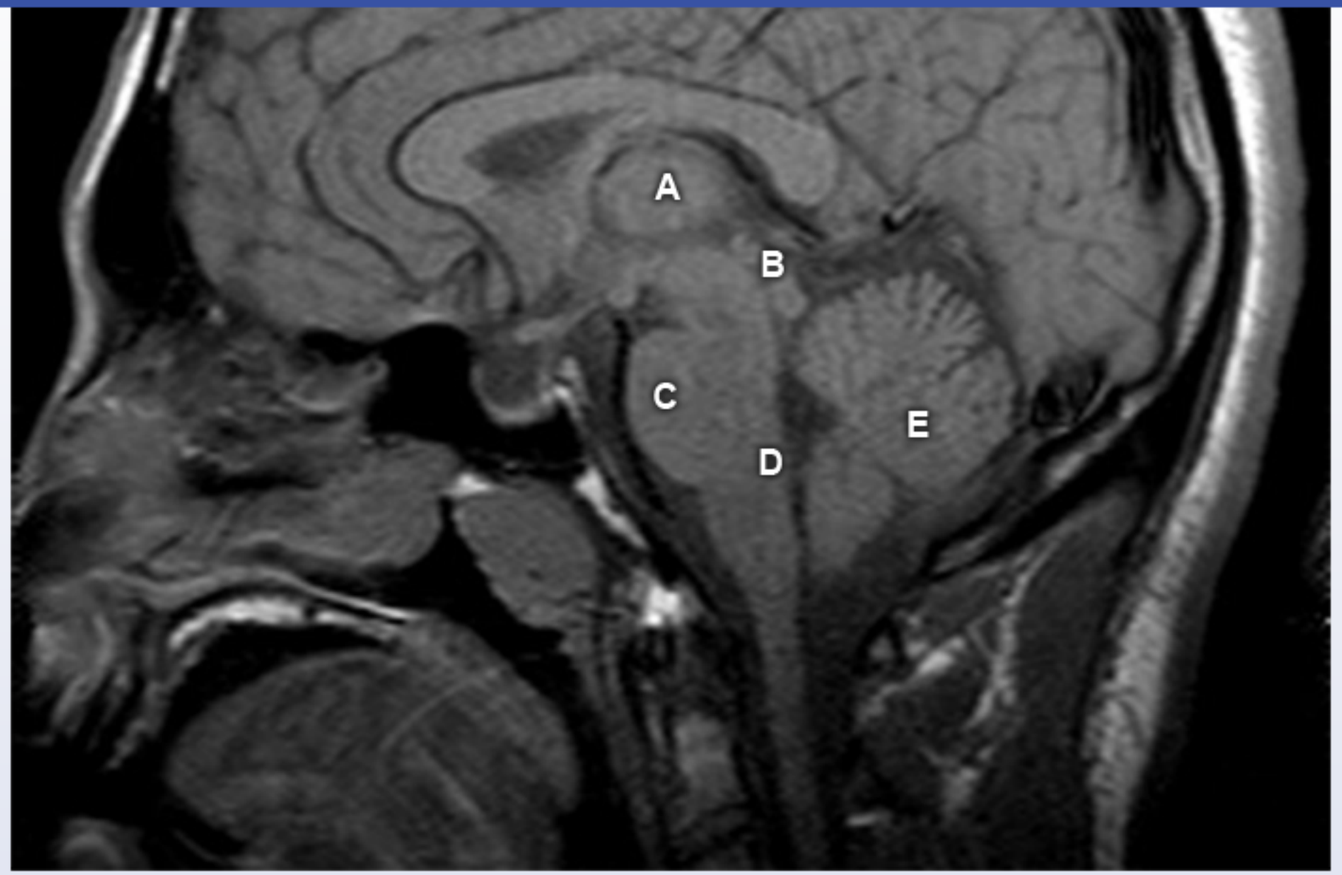

A. A

B. B

C. C

D. D

E. E

8
9
10
11
12
13
14
15
16
17
18
19
20
21
22
23
24
25
26
27
28
29
30
31
32
33
34
35
36
37
38

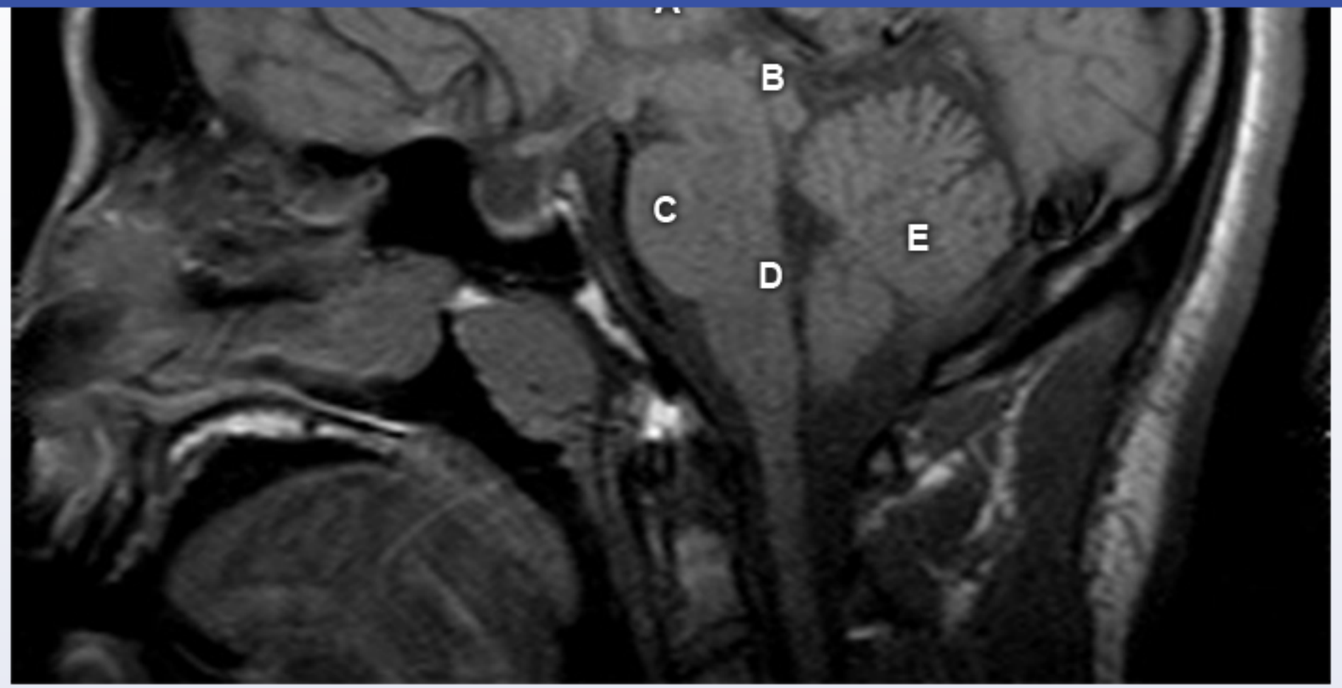

A. A

B. B

C. C

D. D

E. E

Submit

8
9
10
11
12
13
14
15
16
17
18
19
20
21
22
23
24
25
26
27
28
29
30
31
32
33
34
35
36
37
38

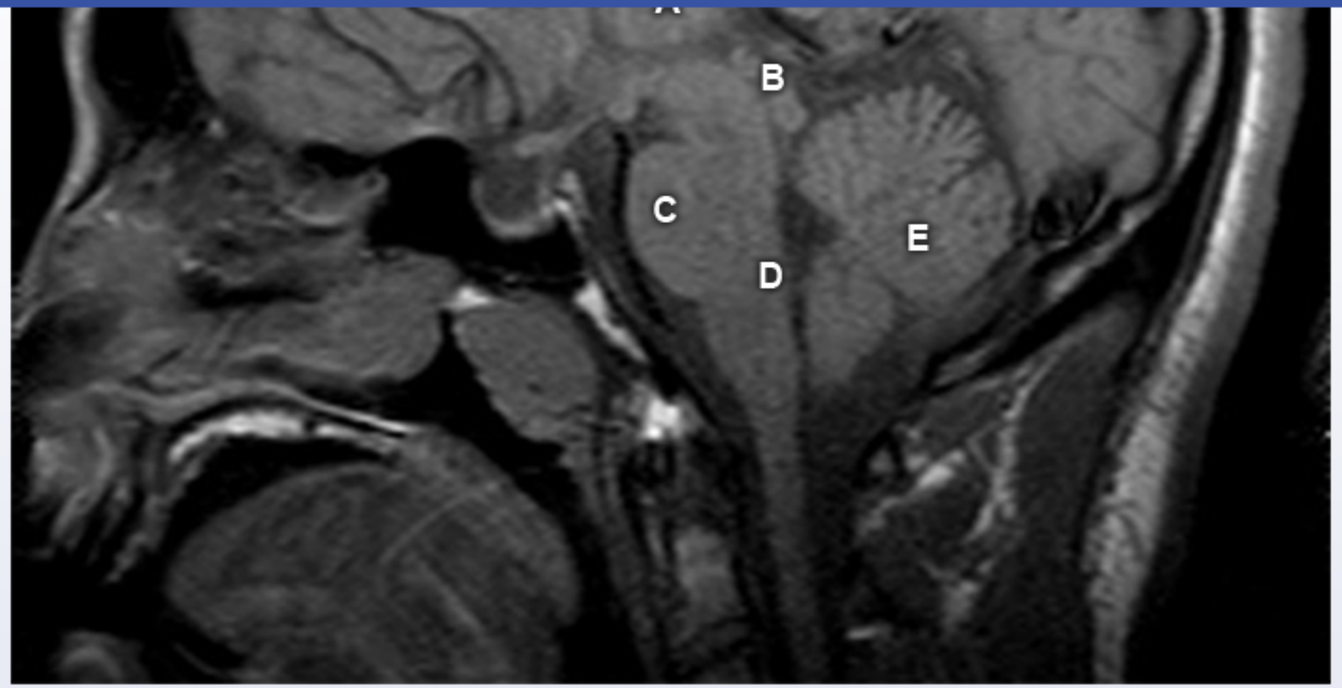

A. A (10%)

B. B (13%)

C. C (8%)

✓ D. D (64%)

E. E (3%)

Omitted
Correct answer

64%
Answered correctly

07 secs
Time Spent

03/03/2020
Last Updated

8
9
10
11
12
13
14
15
16
17
18
19
20
21
22
23
24
25
26
27
28
29
30
31
32
33
34
35
36
37
38

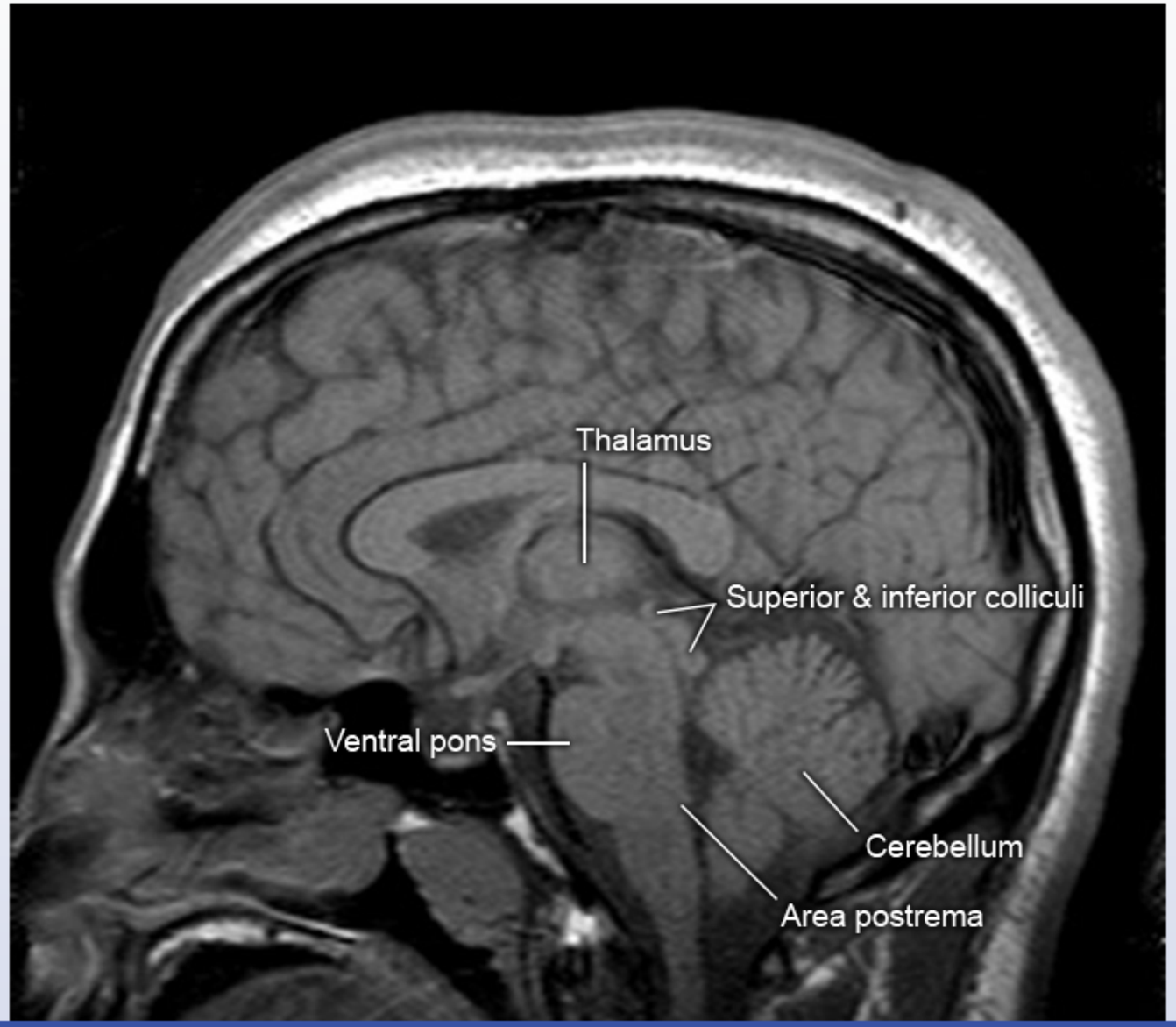

8
9
10
11
12
13
14
15
16
17
18
19
20
21
22
23
24
25
26
27
28
29
30
31
32
33
34
35
36
37
38

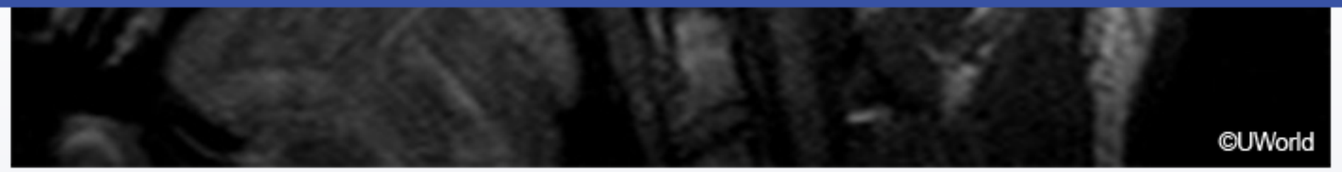

This patient developed acute vomiting after treatment with systemic chemotherapy. The vomiting reflex is initiated by the **chemoreceptor trigger zone** (CTZ, or area postrema) and nucleus tractus solitarius. The **area postrema** is located on the dorsal surface of the medulla at the caudal end of the fourth ventricle; this region does not have a well-developed blood-brain barrier, allowing it to be exposed to chemicals circulating in the blood.

The CTZ can be triggered directly by emetogenic substances (eg, drugs, toxins) or indirectly by vagal afferents from the gastrointestinal tract. **Chemotherapeutic agents** (eg, cyclophosphamide) cause damage to enterocytes, resulting in release of serotonin. This stimulates **5-HT3 receptors** on vagal afferent fibers located in the bowel wall, which then ascend to the CTZ to trigger the **vomiting reflex**. Chemotherapy-associated emetic stimuli in the cerebrospinal fluid and bloodstream also can stimulate the area postrema directly by causing local release of substance P, which activates **neurokinin-1 (NK1) receptors** in the brainstem to induce vomiting.

Selective 5-HT3 receptor antagonists (eg, ondansetron) and NK1 receptor antagonists (eg, aprepitant, fosaprepitant) can be used to ameliorate chemotherapy-induced nausea and vomiting by reducing overstimulation of the CTZ.

(Choice A) The thalamus is superior to the midbrain and makes up part of the lateral wall of the third ventricle. It coordinates sensory and motor function, regulates sleep and wakefulness, and plays an important role in memory and cognition.

(Choice B) The superior and inferior colliculi are located in the dorsal midbrain. They are involved in processing visual (superior colliculi) and auditory (inferior colliculus) information and initiating movement of the head and eyes in response to visual or auditory input.

(Choice C) The ventral pons is inferior to the midbrain in the brainstem and contains the corticospinal tract (eg, limb/torso movement), corticobulbar tract (eg, face/head/neck movement), and abducens nucleus (eg, horizontal eye movement).

(Choice E) The cerebellum makes up the posterior wall of the fourth ventricle and plays an important role in motor control (eg, coordination, precise movements, posture) and cognitive function (eg, attention, language).

Educational objective:
The vomiting reflex is initiated by the chemoreceptor trigger zone (ie, area postrema) and nucleus tractus solitarius within the dorsal medulla at the

8
9
10
11
12
13
14
15
16
17
18
19
20
21
22
23
24
25
26
27
28
29
30
31
32
33
34
35
36
37
38

receptors on vagal afferent fibers located in the bowel wall, which then ascend to the CTZ to trigger the **vomiting reflex**. Chemotherapy-associated emetic stimuli in the cerebrospinal fluid and bloodstream also can stimulate the area postrema directly by causing local release of substance P, which activates **neurokinin-1 (NK1) receptors** in the brainstem to induce vomiting.

Selective 5-HT3 receptor antagonists (eg, ondansetron) and NK1 receptor antagonists (eg, aprepitant, fosaprepitant) can be used to ameliorate chemotherapy-induced nausea and vomiting by reducing overstimulation of the CTZ.

(Choice A) The thalamus is superior to the midbrain and makes up part of the lateral wall of the third ventricle. It coordinates sensory and motor function, regulates sleep and wakefulness, and plays an important role in memory and cognition.

(Choice B) The superior and inferior colliculi are located in the dorsal midbrain. They are involved in processing visual (superior colliculi) and auditory (inferior colliculus) information and initiating movement of the head and eyes in response to visual or auditory input.

(Choice C) The ventral pons is inferior to the midbrain in the brainstem and contains the corticospinal tract (eg, limb/torso movement), corticobulbar tract (eg, face/head/neck movement), and abducens nucleus (eg, horizontal eye movement).

(Choice E) The cerebellum makes up the posterior wall of the fourth ventricle and plays an important role in motor control (eg, coordination, precise movements, posture) and cognitive function (eg, attention, language).

Educational objective:

The vomiting reflex is initiated by the chemoreceptor trigger zone (ie, area postrema) and nucleus tractus solitarius within the dorsal medulla at the caudal end of the fourth ventricle. The area postrema does not have a well-developed blood brain barrier, allowing it to be activated directly by emetogenic substances (eg, drugs, toxins) or indirectly by ascending afferents from the bowel wall (eg, chemotherapy-induced release of serotonin).

References

- Physiology, Chemoreceptor Trigger Zone

Anatomy	Nervous System	Nausea and vomiting
Subject	System	Topic

Copyright © UWorld. All rights reserved.

8
9
10
11
12
13
14
15
16
17
18
19
20
21
22
23
24
25
26
27
28
29
30
31
32
33
34
35
36
37
38

A 54-year-old man is brought to the emergency department by his wife after he develops difficulty speaking. When asked about the onset of his symptoms, the patient slowly responds with "I... weak... morning..." and becomes very frustrated. His wife says that he was able to grasp a pen without any problem while completing medical release forms, but had trouble signing his name. On examination, he is able to state his first name but with difficulty, and correctly points to different body parts on command. He also has mild weakness involving his right arm and face. This patient's speech difficulties are most likely caused by a lesion affecting which of the following brain areas?

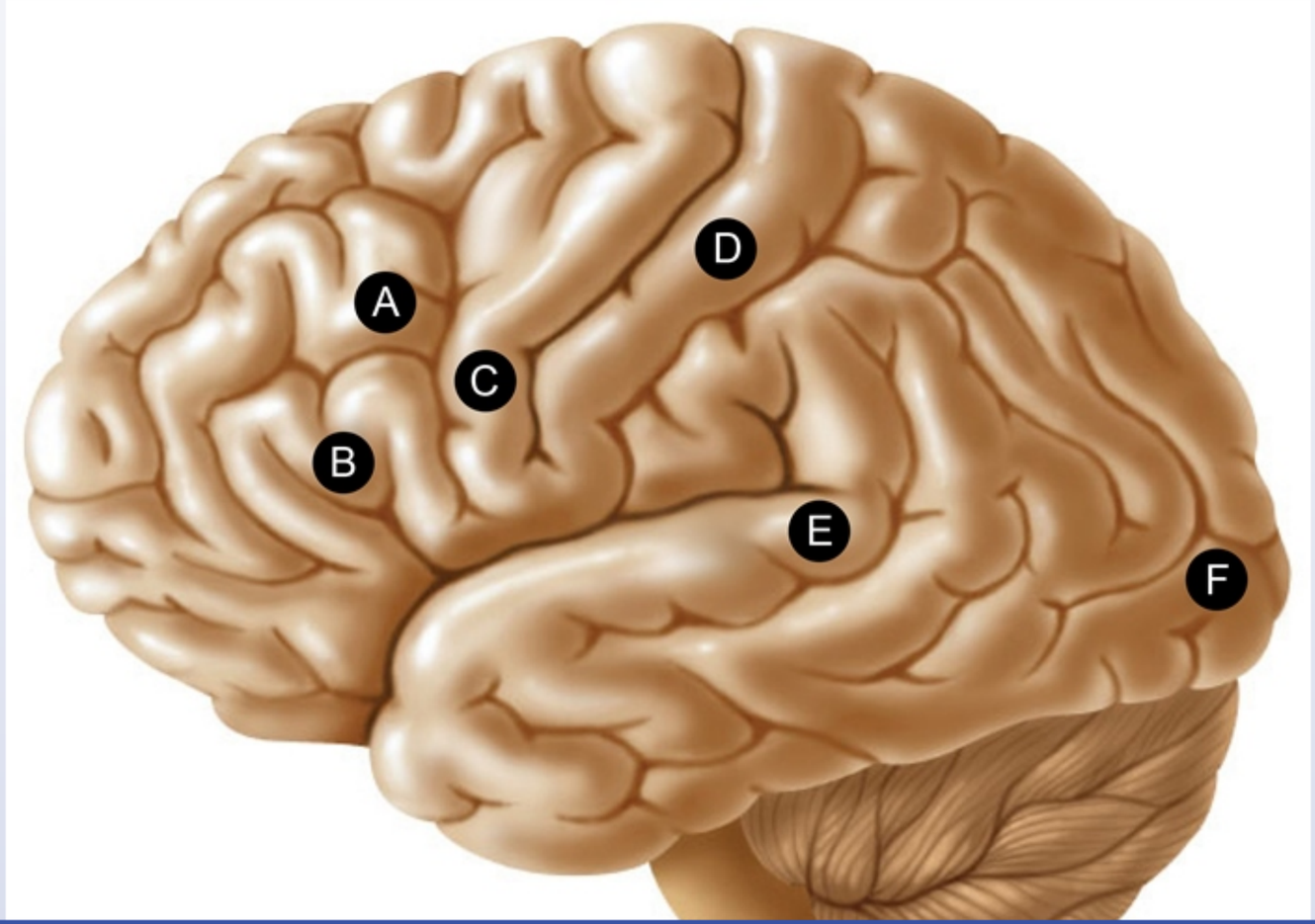

10
11
12
13
14
15
16
17
18
19
20
21
22
23
24
25
26
27
28
29
30
31
32
33
34
35
36
37
38
39
40

A. A

B. B

C. C

D. D

E. E

F. F

Submit

10
11
12
13
14
15
16
17
18
19
20
21
22
23
24
25
26
27
28
29
30
31
32
33
34
35
36
37
38
39
40

A. A (1%)
✓ B. B (72%)
C. C (14%)
D. D (2%)
E. E (9%)
F. F (0%)

Omitted
Correct answer

72%
Answered correctly

05 secs
Time Spent

04/08/2020
Last Updated

10
11
12
13
14
15
16
17
18
19
20
21
22
23
24
25
26
27
28
29
30
31
32
33
34
35
36
37
38
39
40

Common types of aphasia

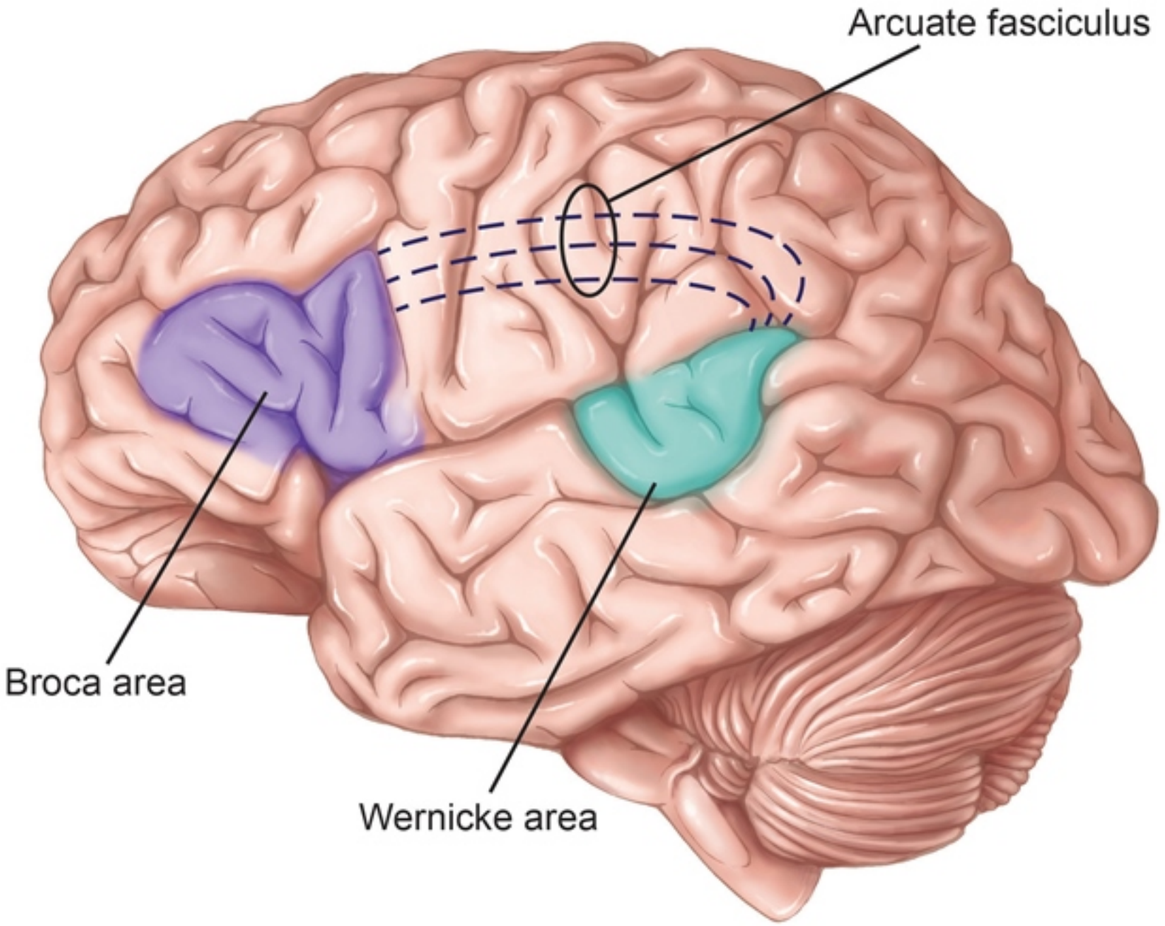

Aphasia	Spontaneous	Comprehension	Repetition	Associated features

Aphasia syndrome	Spontaneous speech	Comprehension	Repetition	Associated features
Broca	Sparse & nonfluent	Relatively preserved	Impaired	Right hemiparesis (face & upper limb)
Wernicke	Fluent & voluminous but lacks meaning	Greatly diminished	Impaired	Right superior visual field defect
Conduction	Fluent with phonemic errors	Relatively preserved	Very poor	None

©UWorld

This patient most likely has **Broca (motor, nonfluent) aphasia**. This condition classically results from damage to Broca area of the brain, the region responsible for all communicative motor planning. Individuals are able to communicate meaningfully, but their speech is slow and consists primarily of nouns and verbs. Speech may be punctuated by pauses after each word as the patient attempts to verbalize the next. Patients also often have difficulty writing and signing, and become frustrated as they have insight into their expressive language difficulties. They can understand spoken language and follow commands (intact speech comprehension) as Wernicke area is unaffected.

Broca area is in the caudal part of the **inferior frontal gyrus** of the **dominant (usually left) hemisphere** (Brodmann areas 44 and 45). Patients may have associated **right hemiparesis** involving the upper limb and face due to this region's proximity to the primary motor cortex.

(Choice A) The frontal eye field is found near the caudal end of the middle frontal gyrus anterior to the precentral sulcus (Brodmann areas 6 and 8). Damage here would cause the eyes to deviate to the ipsilateral side.

(Choice C) Lesions to the precentral gyrus (primary motor cortex) can cause slurred speech (dysarthria) due to paresis/paralysis of the skeletal

This patient most likely has **Broca (motor, nonfluent) aphasia**. This condition classically results from damage to Broca area of the brain, the region responsible for all communicative motor planning. Individuals are able to communicate meaningfully, but their speech is slow and consists primarily of nouns and verbs. Speech may be punctuated by pauses after each word as the patient attempts to verbalize the next. Patients also often have difficulty writing and signing, and become frustrated as they have insight into their expressive language difficulties. They can understand spoken language and follow commands (intact speech comprehension) as Wernicke area is unaffected.

Broca area is in the caudal part of the **inferior frontal gyrus** of the **dominant (usually left) hemisphere** (Brodmann areas 44 and 45). Patients may have associated **right hemiparesis** involving the upper limb and face due to this region's proximity to the primary motor cortex.

(Choice A) The frontal eye field is found near the caudal end of the middle frontal gyrus anterior to the precentral sulcus (Brodmann areas 6 and 8). Damage here would cause the eyes to deviate to the ipsilateral side.

(Choice C) Lesions to the precentral gyrus (primary motor cortex) can cause slurred speech (dysarthria) due to paresis/paralysis of the skeletal muscles involved in movements of the mouth, tongue, and larynx. Damage to Broca area is often associated with right-sided hemiparesis and oral apraxia due to extension of the lesion into the ipsilateral motor regions. However, it is injury to Broca area that leads to **language deficit**.

(Choice D) This is the postcentral gyrus (primary somatosensory cortex). A lesion here would cause sensation loss in the corresponding area of the contralateral body.

(Choice E) The caudal superior temporal gyrus (Brodmann area 22) is in the Wernicke area. A lesion here would cause a sensory (receptive) aphasia. Wernicke aphasia is also known as fluent aphasia in that speech flows readily but is meaningless ("word salad"). Patients typically lack insight into their problem.

(Choice F) A lesion to the visual cortex can cause cortical blindness or visual impairment that can make reading and writing difficult. Spoken speech would be unaffected.

Educational objective:
Broca (motor, nonfluent) aphasia results from damage to the inferior frontal gyrus of the dominant hemisphere. Patients are often frustrated as they understand language but cannot properly formulate the motor commands to write or form words (eg, slow, fragmented speech). Aphasia may be associated with right upper limb and face weakness due to extension of the lesion into the primary motor cortex.

References

may have associated **right hemiparesis** involving the upper limb and face due to this region's proximity to the primary motor cortex.

(Choice A) The frontal eye field is found near the caudal end of the middle frontal gyrus anterior to the precentral sulcus (Brodmann areas 6 and 8). Damage here would cause the eyes to deviate to the ipsilateral side.

(Choice C) Lesions to the precentral gyrus (primary motor cortex) can cause slurred speech (dysarthria) due to paresis/paralysis of the skeletal muscles involved in movements of the mouth, tongue, and larynx. Damage to Broca area is often associated with right-sided hemiparesis and oral apraxia due to extension of the lesion into the ipsilateral motor regions. However, it is injury to Broca area that leads to **language deficit**.

(Choice D) This is the postcentral gyrus (primary somatosensory cortex). A lesion here would cause sensation loss in the corresponding area of the contralateral body.

(Choice E) The caudal superior temporal gyrus (Brodmann area 22) is in the Wernicke area. A lesion here would cause a sensory (receptive) aphasia. Wernicke aphasia is also known as fluent aphasia in that speech flows readily but is meaningless ("word salad"). Patients typically lack insight into their problem.

(Choice F) A lesion to the visual cortex can cause cortical blindness or visual impairment that can make reading and writing difficult. Spoken speech would be unaffected.

Educational objective:
Broca (motor, nonfluent) aphasia results from damage to the inferior frontal gyrus of the dominant hemisphere. Patients are often frustrated as they understand language but cannot properly formulate the motor commands to write or form words (eg, slow, fragmented speech). Aphasia may be associated with right upper limb and face weakness due to extension of the lesion into the primary motor cortex.

References

- Neuroanatomic correlation of the post-stroke aphasias studied with imaging.

Anatomy	Nervous System	Aphasia
Subject	System	Topic

Copyright © UWorld. All rights reserved.

may have associated **right hemiparesis** involving the upper limb and face due to this region's proximity to the primary motor cortex.

Exhibit Display

Homunculus

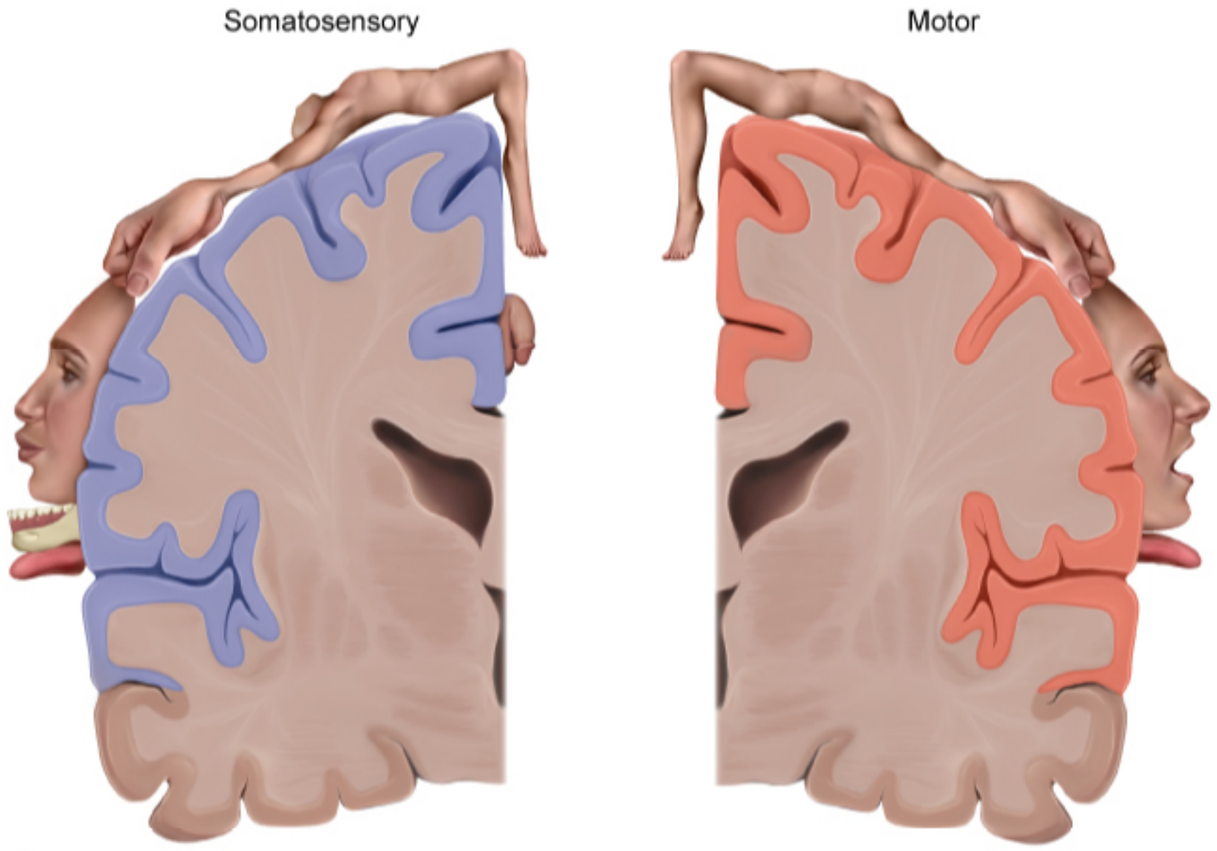

©UWorld

Zoom In | Zoom Out | Reset | Add To New Card | Existing Card

may have associated **right hemiparesis** involving the upper limb and face due to this region's proximity to the primary motor cortex.

Exhibit Display

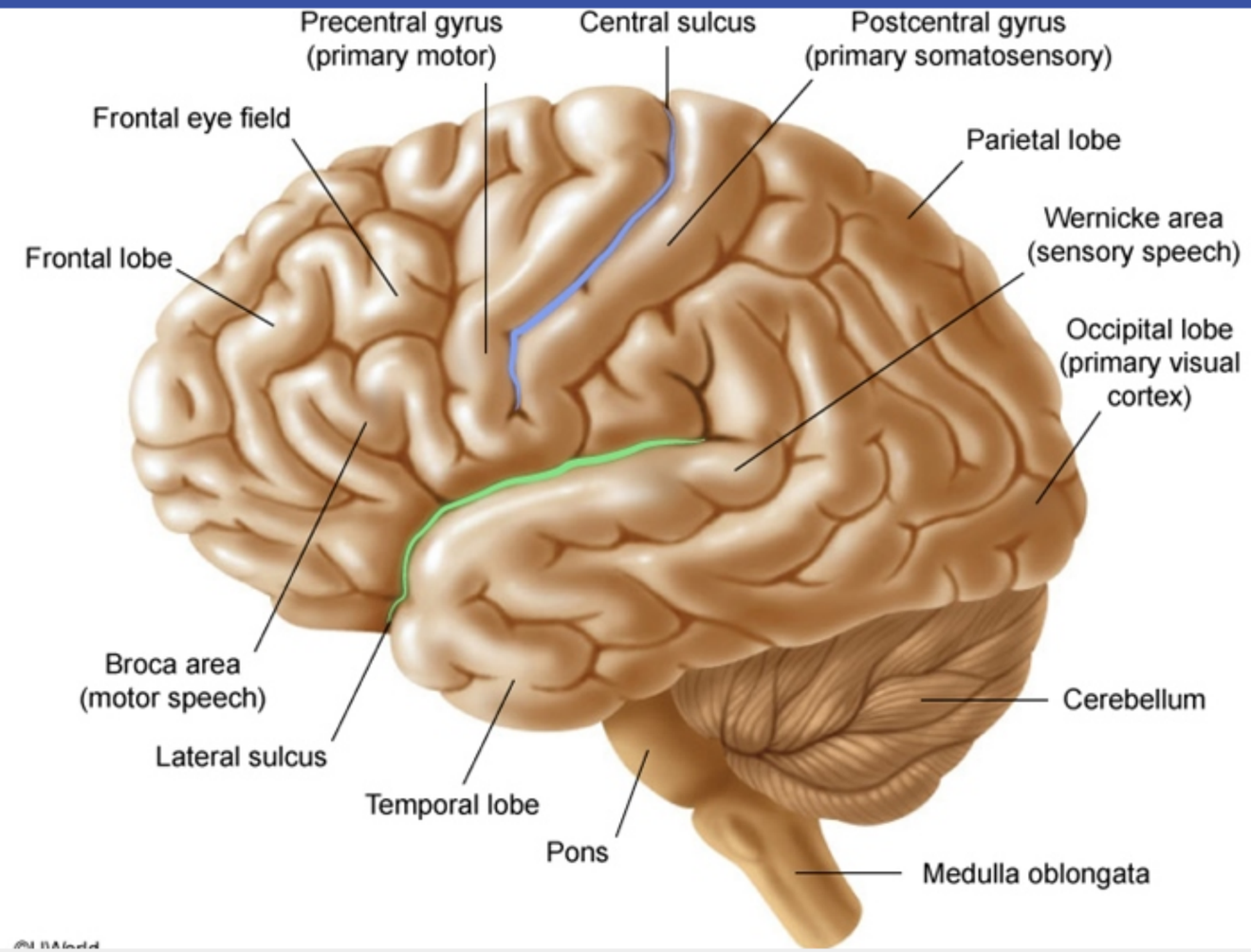

Zoom In | Zoom Out | Reset | Add To New Card | Existing Card

A 23-year-old man is brought to the emergency department after sustaining stab injuries in a street fight. The patient feels lightheaded and dizzy. His blood pressure is 100/60 mm Hg and pulse is 115/min. Physical examination shows profuse bleeding from penetrating wounds over the left neck and shoulder area. Intravenous fluids are administered, and a blood transfusion is initiated. Urgent surgical exploration is performed, and the injured blood vessel is repaired. Further exploration shows complete transection of the nerve indicated by the arrow in the image below.



10
11
12
13
14
15
16
17
18
19
20
21
22
23
24
25
26
27
28
29
30
31
32
33
34
35
36
37
38
39
40



Which of the following actions is most likely to be weakened as a result of this patient's nerve injury?

- A. Abduction of the fingers
- B. Adduction of the thumb
- C. Extension of the wrist
- D. Flexion of the wrist
- E. Opposition of the thumb

Submit

10
11
12
13
14
15
16
17
18
19
20
21
22
23
24
25
26
27
28
29
30
31
32
33
34
35
36
37
38
39
40



Which of the following actions is most likely to be weakened as a result of this patient's nerve injury?

A. Abduction of the fingers (3%)

B. Adduction of the thumb (3%)

✓ C. Extension of the wrist (76%)

D. Flexion of the wrist (10%)

E. Opposition of the thumb (5%)

Omitted
Correct answer

76%
Answered correctly

07 secs
Time Spent

05/20/2020
Last Updated

10
11
12
13
14
15
16
17
18
19
20
21
22
23
24
25
26
27
28
29
30
31
32
33
34
35
36
37
38
39
40

Brachial plexus

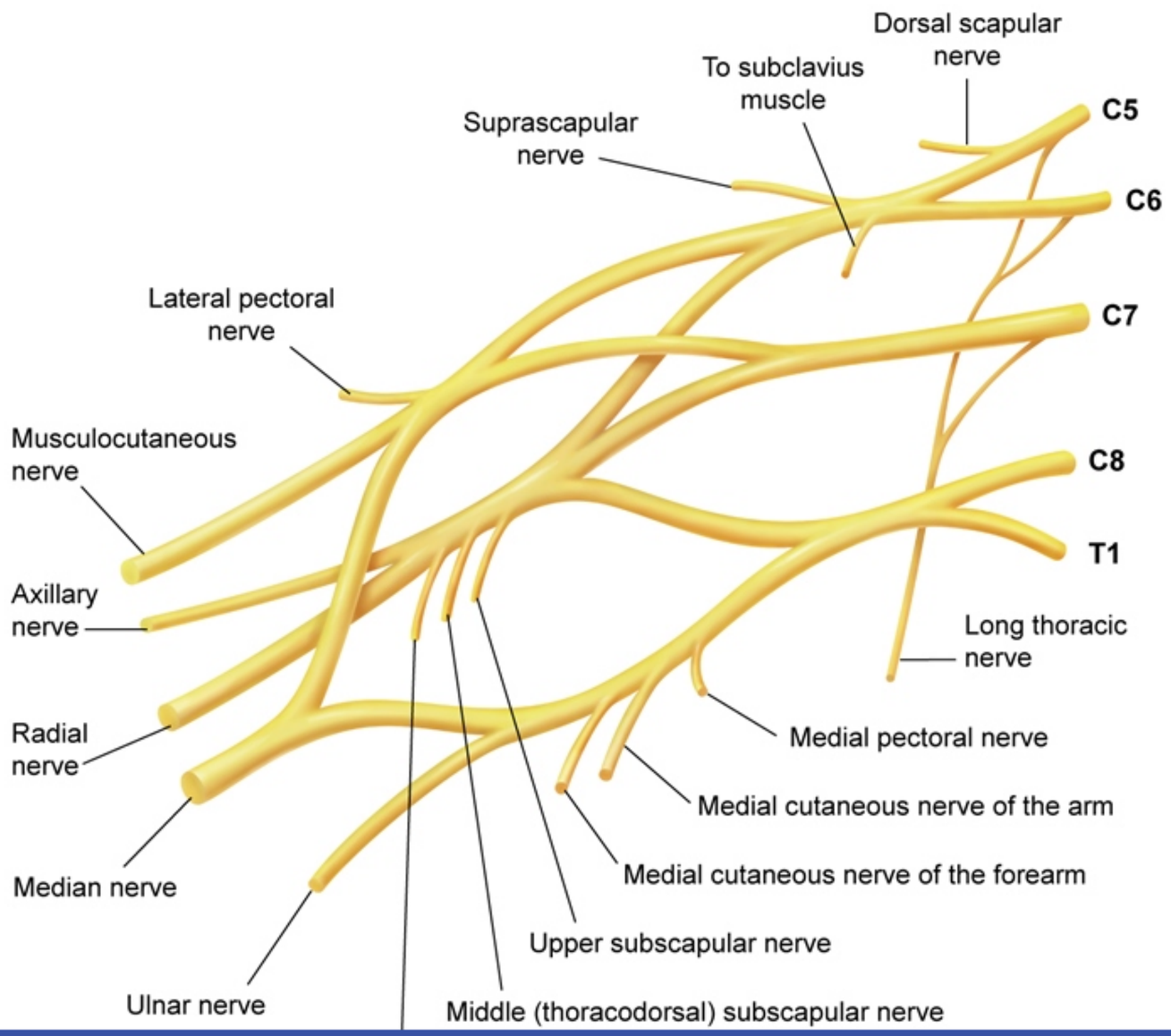

10
11
12
13
14
15
16
17
18
19
20
21
22
23
24
25
26
27
28
29
30
31
32
33
34
35
36
37
38
39
40

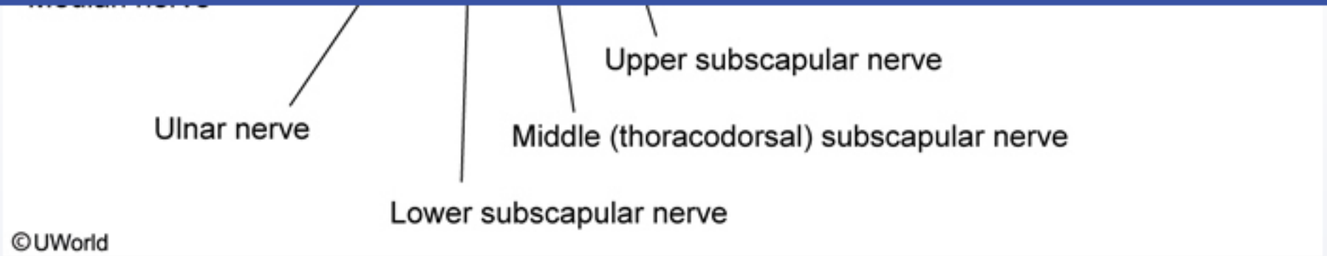

The radial nerve is the largest branch of the brachial plexus and receives fibers from C5-T1. It innervates all of the extensor muscles of the upper limb below the shoulder and provides sensory innervation to the skin of the posterior arm, forearm, and dorsal lateral hand.

This nerve tracks within the radial groove on the humerus; therefore, it is vulnerable to traumatic injury (eg, penetrating stab wound) at the **humeral midshaft**. The nerve can also be injured during its superficial course within the **axilla**. Patients with proximal radial neuropathy typically have weakness during wrist and finger extension (wrist drop) and variable sensory loss over the posterior arm and forearm.

(Choices A, B, D, and E) Damage to the median or ulnar nerve can result in weakness on wrist flexion. Damage to the median nerve can also result in weakness on thumb opposition, whereas ulnar nerve damage may limit finger abduction and thumb adduction.

Educational objective:
The radial nerve provides sensory innervation to the skin of the posterior arm, forearm, and dorsal lateral hand and provides motor innervation to all of the extensor muscles of the upper limb below the shoulder. Damage to the proximal radial nerve (eg, at the axilla or midshaft humerus) may result in wrist drop.

References

- Clinical features of wrist drop caused by compressive radial neuropathy and its anatomical considerations.
- Anatomical, clinical, and electrodiagnostic features of radial neuropathies.

Anatomy	Nervous System	Brachial plexus
Subject	System	Topic

Copyright © UWorld. All rights reserved.

10
11
12
13
14
15
16
17
18
19
20
21
22
23
24
25
26
27
28
29
30
31
32
33
34
35
36
37
38
39
40

Exhibit Display

Important nerves in the arm

Nerve	Motor function	Region of sensory loss with neuropathy
Radial nerve	Extension at all arm, wrist, & finger joints below the shoulder, forearm supination, thumb abduction in plane of palm	

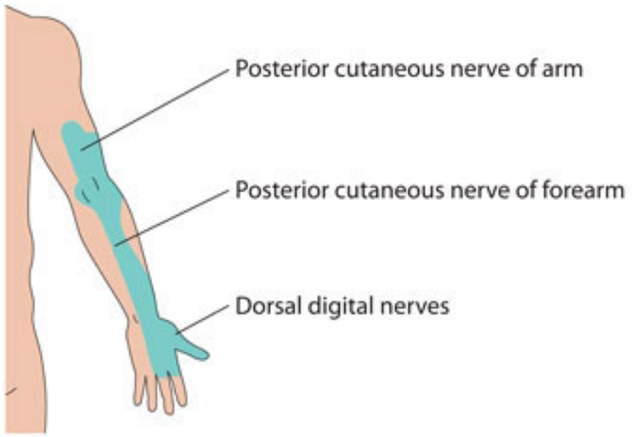

©UWorld

Zoom In | Zoom Out | Reset | Add To New Card | Existing Card

10
11
12
13
14
15
16
17
18
19
20
21
22
23
24
25
26
27
28
29
30
31
32
33
34
35
36
37
38
39
40

Exhibit Display

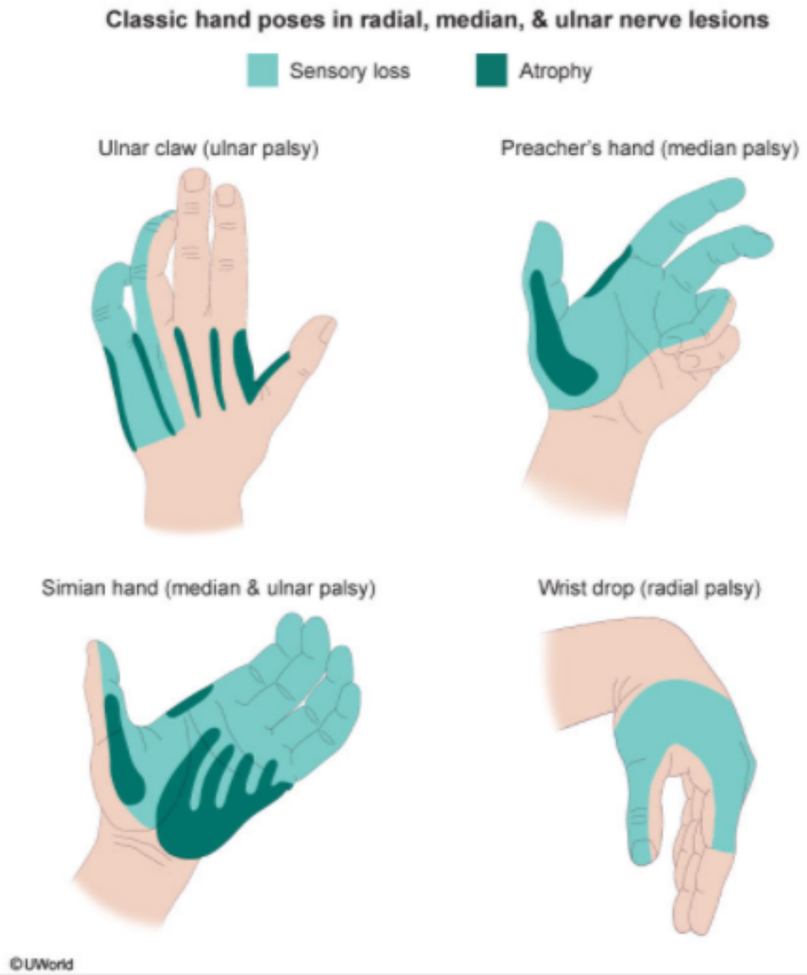

Zoom In | Zoom Out | Reset | Add To New Card | Existing Card

10
11
12
13
14
15
16
17
18
19
20
21
22
23
24
25
26
27
28
29
30
31
32
33
34
35
36
37
38
39
40

Exhibit Display

Median nerve

Motor function	Cutaneous innervation
Thumb flexion & opposition, flexion of digits 2 & 3, wrist flexion & abduction, forearm pronation	

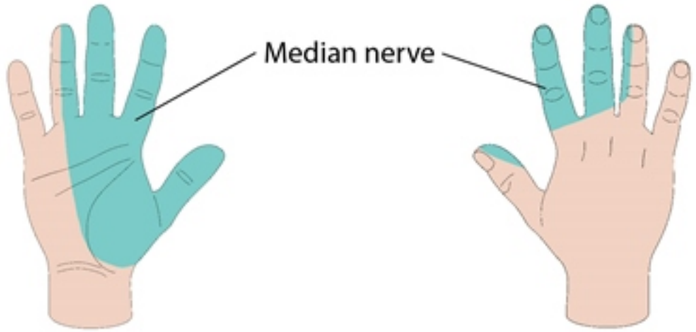

©UWorld

Zoom In | Zoom Out | Reset | Add To New Card | Existing Card

10
11
12
13
14
15
16
17
18
19
20
21
22
23
24
25
26
27
28
29
30
31
32
33
34
35
36
37
38
39
40

Exhibit Display

Nerve	Motor function	Region of sensory loss with neuropathy
Ulnar nerve	Finger abduction & adduction other than thumb, thumb adduction, flexion of digits 4 & 5, wrist flexion & adduction	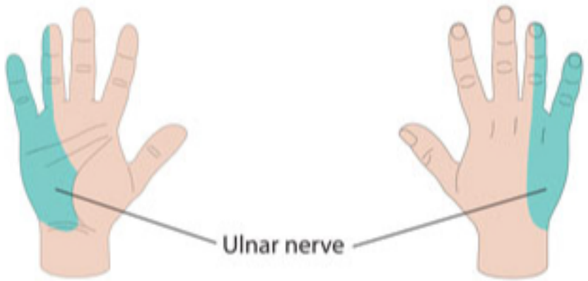

©UWorld

Zoom In | Zoom Out | Reset | Add To New Card | Existing Card

A 35-year-old, right-handed mechanic comes to the clinic due to progressive right hand weakness. The patient frequently uses a screwdriver at work. Neurologic examination shows preserved sensation in the upper limbs. There is weakness on extension of the fingers and thumb in the right hand. Strength is otherwise intact. Triceps reflexes are 2+ and bilaterally symmetric. The nerve affected in this patient was most likely injured at which of the following locations?

- A. Axilla
- B. Carpal tunnel
- C. Coracobrachialis
- D. Hook of hamate
- E. Midshaft of the humerus
- F. Supinator muscle

Submit

A 35-year-old, right-handed mechanic comes to the clinic due to progressive right hand weakness. The patient frequently uses a screwdriver at work. Neurologic examination shows preserved sensation in the upper limbs. There is weakness on extension of the fingers and thumb in the right hand. Strength is otherwise intact. Triceps reflexes are 2+ and bilaterally symmetric. The nerve affected in this patient was most likely injured at which of the following locations?

- A. Axilla (1%)
- B. Carpal tunnel (20%)
- C. Coracobrachialis (5%)
- D. Hook of hamate (11%)
- E. Midshaft of the humerus (17%)
- ✓ F. Supinator muscle (43%)

Omitted
Correct answer
F

43%
Answered correctly

02 secs
Time Spent

02/19/2020
Last Updated

Explanation

10
11
12
13
14
15
16
17
18
19
20
21
22
23
24
25
26
27
28
29
30
31
32
33
34
35
36
37
38
39
40

Radial nerve
(posterior view)

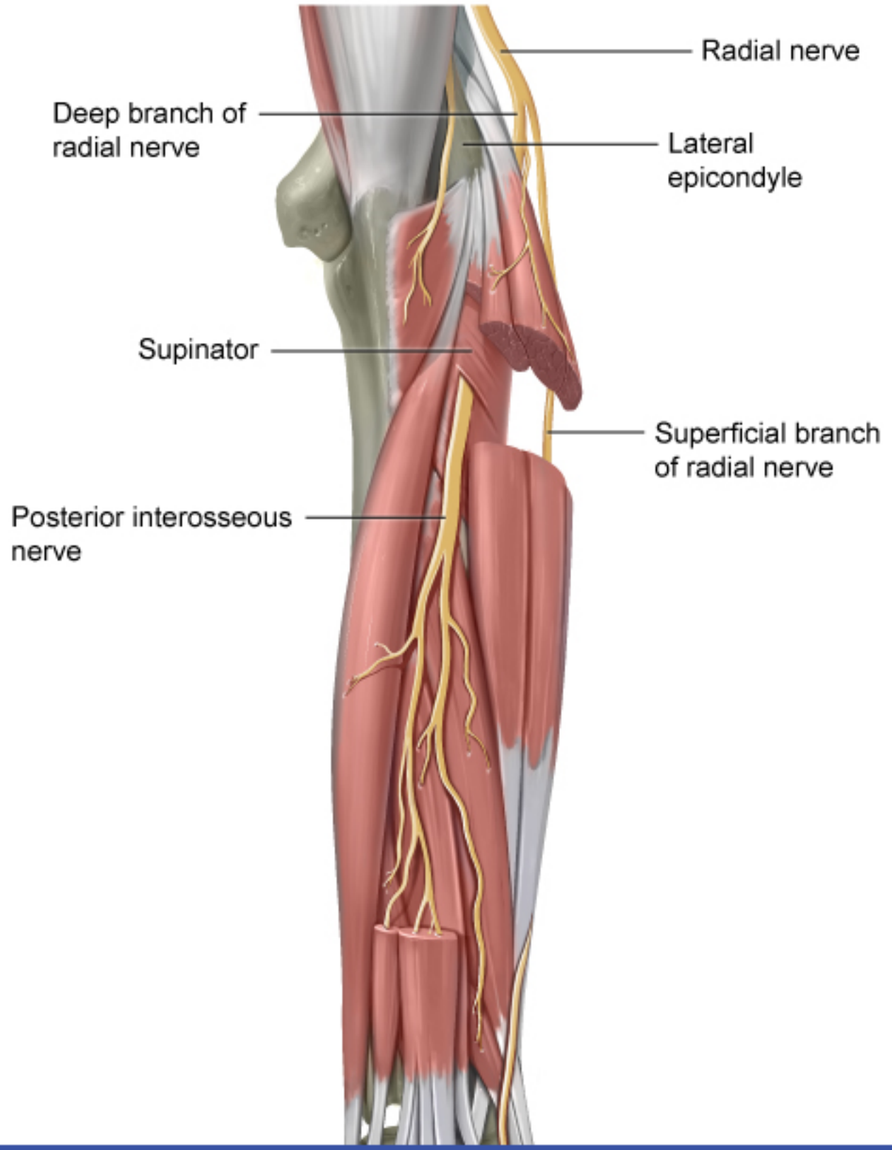

10
11
12
13
14
15
16
17
18
19
20
21
22
23
24
25
26
27
28
29
30
31
32
33
34
35
36
37
38
39
40

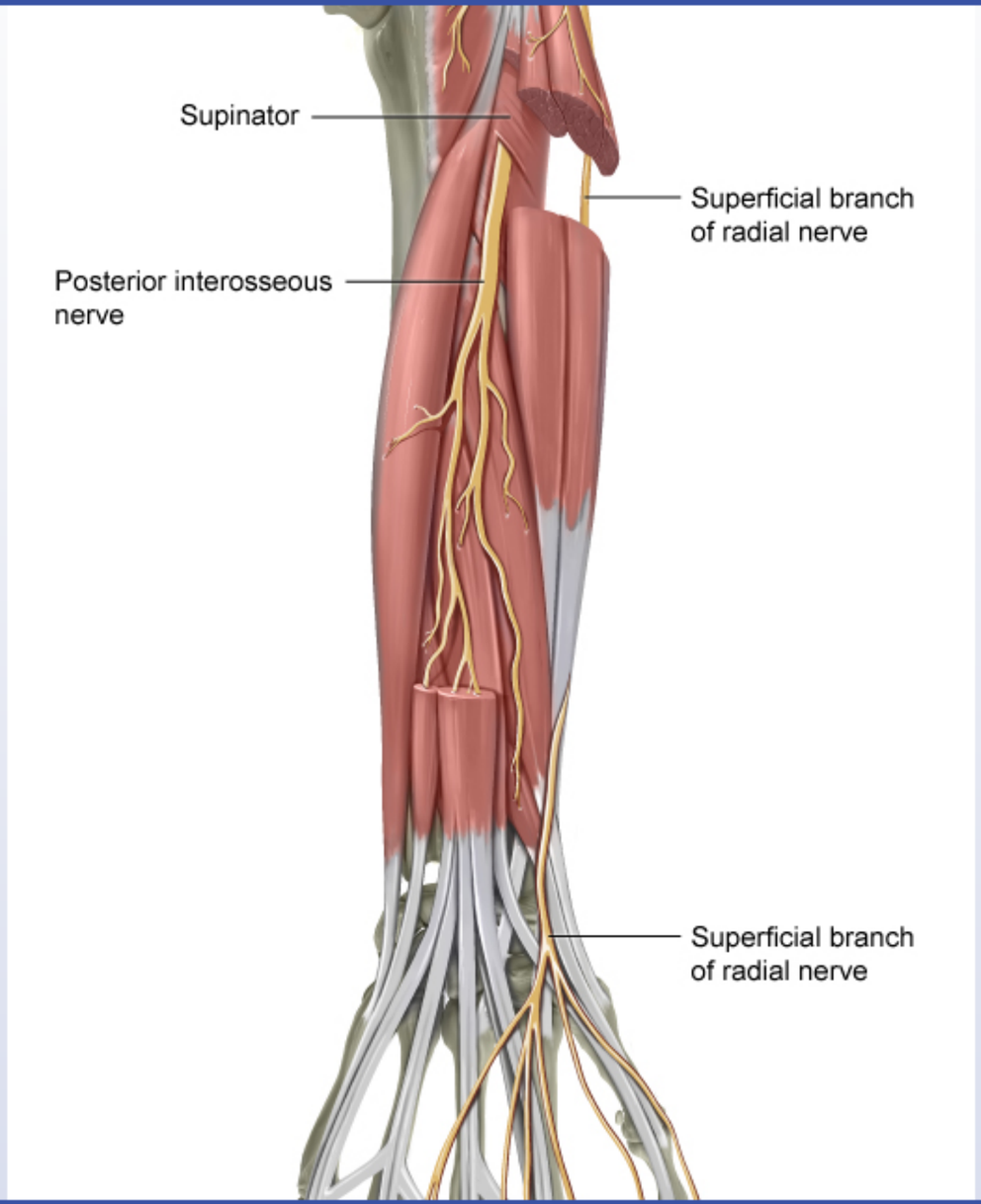

10
11
12
13
14
15
16
17
18
19
20
21
22
23
24
25
26
27
28
29
30
31
32
33
34
35
36
37
38
39
40

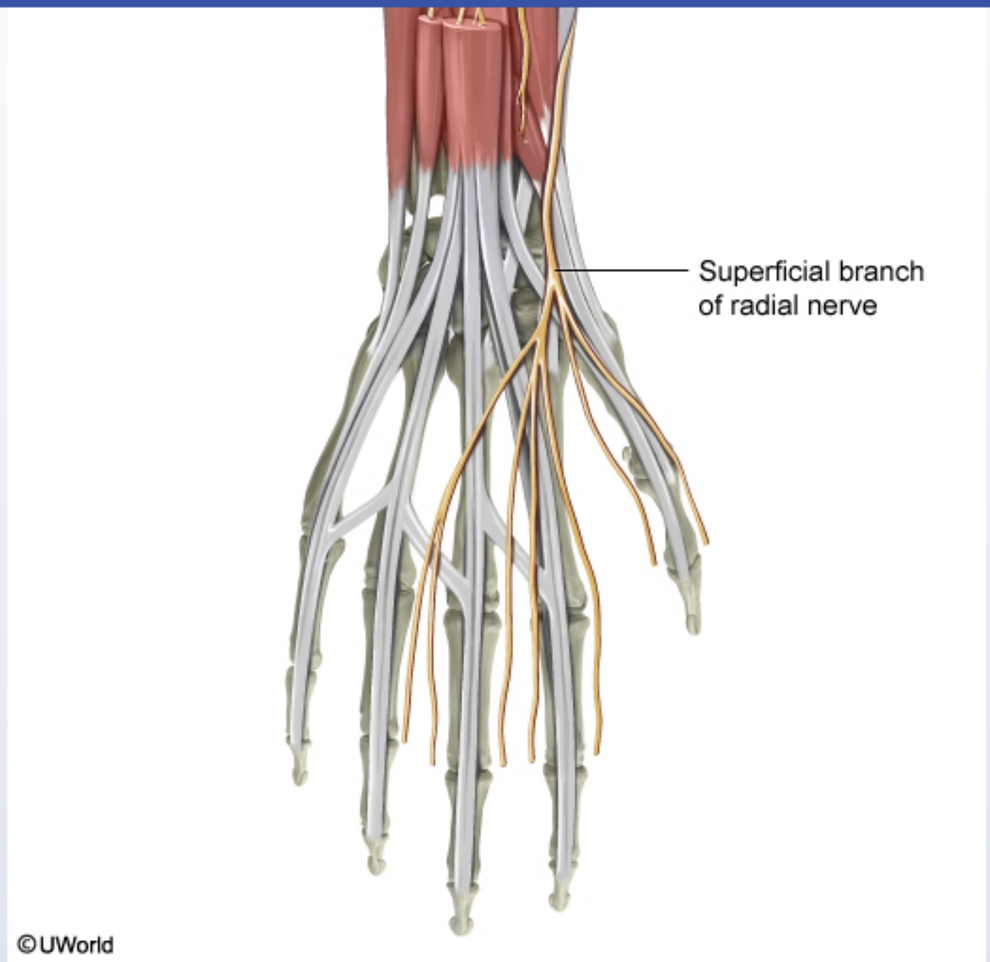

The radial nerve enters the forearm anterior to the lateral epicondyle and divides into superficial and deep branches. The superficial branch provides purely somatic sensory innervation to the radial half of the dorsal hand, and the deep branch innervates the extensor compartment muscles in the forearm. After passing between the superficial and deep parts of the **supinator muscle**, the deep branch continues as the posterior interosseous nerve, which innervates muscles involved in finger and thumb extension.

Injury to the deep branch of the radial nerve at the supinator muscle may occur due to **repetitive pronation/supination** of the forearm (eg,

©UWorld

The radial nerve enters the forearm anterior to the lateral epicondyle and divides into superficial and deep branches. The superficial branch provides purely somatic sensory innervation to the radial half of the dorsal hand, and the deep branch innervates the extensor compartment muscles in the forearm. After passing between the superficial and deep parts of the **supinator muscle**, the deep branch continues as the posterior interosseous nerve, which innervates muscles involved in finger and thumb extension.

Injury to the deep branch of the radial nerve at the supinator muscle may occur due to **repetitive pronation/supination** of the forearm (eg, frequent screwdriver use), direct trauma, or dislocation of the head of the radius. Patients typically have **weakness on finger and thumb extension** (ie, finger drop). The triceps brachii (responsible for elbow extension and triceps reflex) and extensor carpi radialis longus (responsible for wrist extension) are typically unaffected because the branches supplying these muscles diverge proximal to the supinator muscle. Cutaneous **sensory branches** are similarly **preserved**.

(Choices A and E) Injury to the radial nerve at the axilla (eg, crutch palsy) typically causes weakness of the forearm, hand, and finger extensor muscles (eg, wrist drop) with absent triceps reflex and sensory loss over the posterior arm, forearm, and dorsolateral hand. Injury to the nerve at the midshaft humerus (eg, radial groove) usually causes similar forearm/hand deficits with sparing of the triceps muscle.

(Choice B) Carpal tunnel syndrome can result from any condition that reduces the size of the carpal tunnel and compresses the median nerve (eg, pregnancy, hypothyroidism). Patients typically have pain/paresthesia affecting the first 3 and a half digits along with thenar atrophy and thumb abduction/opposition weakness as the disease progresses.

(Choice C) The coracobrachialis muscle lies deep to the biceps brachii and is innervated by the musculocutaneous nerve. Nerve injury may result in decreased strength on forearm flexion and sensory loss over the lateral forearm.

(Choice D) In the wrist, the ulnar nerve passes between the hook of hamate and the pisiform bone in the Guyon canal. Ulnar nerve injury at this site can cause weakness on finger abduction/adduction and clawing of the fourth and fifth digits.

Educational objective:
Injury to the radial nerve at the supinator muscle may occur due to repetitive pronation/supination of the forearm, direct trauma, or subluxation of the radius. Patients typically have weakness during finger and thumb extension (ie, finger-drop) without wrist drop or sensory deficits.

References

©UWorld

Exhibit Display

Radial nerve

Motor function	Cutaneous innervation
Extension at all arm, wrist & finger joints below the shoulder, forearm supination, thumb abduction in plane of palm	

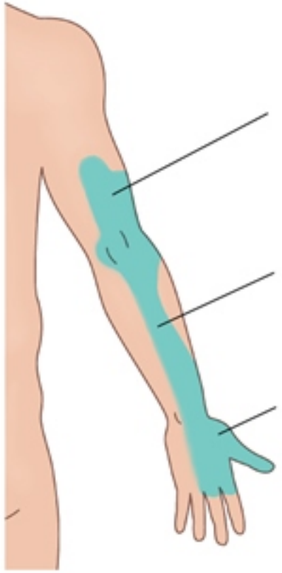

©UWorld

Zoom In | Zoom Out | Reset | Add To New Card | Existing Card

References

extension (ie, finger drop). The triceps brachii (responsible for elbow extension and triceps reflex) and extensor carpi radialis longus (responsible for wrist extension) are typically unaffected because the branches supplying these muscles diverge proximal to the supinator muscle. Cutaneous **sensory branches** are similarly **preserved**.

(Choices A and E) Injury to the radial nerve at the axilla (eg, crutch palsy) typically causes weakness of the forearm, hand, and finger extensor muscles (eg, wrist drop) with absent triceps reflex and sensory loss over the posterior arm, forearm, and dorsolateral hand. Injury to the nerve at the midshaft humerus (eg, radial groove) usually causes similar forearm/hand deficits with sparing of the triceps muscle.

(Choice B) Carpal tunnel syndrome can result from any condition that reduces the size of the carpal tunnel and compresses the median nerve (eg, pregnancy, hypothyroidism). Patients typically have pain/paresthesia affecting the first 3 and a half digits along with thenar atrophy and thumb abduction/opposition weakness as the disease progresses.

(Choice C) The coracobrachialis muscle lies deep to the biceps brachii and is innervated by the musculocutaneous nerve. Nerve injury may result in decreased strength on forearm flexion and sensory loss over the lateral forearm.

(Choice D) In the wrist, the ulnar nerve passes between the hook of hamate and the pisiform bone in the Guyon canal. Ulnar nerve injury at this site can cause weakness on finger abduction/adduction and clawing of the fourth and fifth digits.

Educational objective:
Injury to the radial nerve at the supinator muscle may occur due to repetitive pronation/supination of the forearm, direct trauma, or subluxation of the radius. Patients typically have weakness during finger and thumb extension (ie, finger-drop) without wrist drop or sensory deficits.

References

- Clinical features of wrist drop caused by compressive radial neuropathy and its anatomical considerations.
- Anatomical, clinical, and electrodiagnostic features of radial neuropathies.

Anatomy	Nervous System	Radial neuropathy
Subject	System	Topic

Copyright © UWorld. All rights reserved.

A 35-year-old woman with a history of migraines is evaluated due to a recent increase in headache frequency and severity. She has had no focal weakness, sensory loss, vision changes, or seizures. The patient has no other medical conditions and takes sumatriptan as needed. She does not use tobacco, alcohol, or illicit drugs. Physical examination shows no focal neurological deficits. Neuroimaging reveals a small aneurysm arising from the segment of right internal carotid artery within the cavernous sinus. If this patient's aneurysm continues to expand, which of the following findings is most likely to be observed?

A. Deviation of the tongue to the right when protruded

B. Inability to contract the right orbicularis oculi muscle

C. Loss of sensation from anterior two-thirds of the tongue

D. Vision defect affecting the left half of the visual field

E. Weakness of the right lateral rectus muscle

Submit

A 35-year-old woman with a history of migraines is evaluated due to a recent increase in headache frequency and severity. She has had no focal weakness, sensory loss, vision changes, or seizures. The patient has no other medical conditions and takes sumatriptan as needed. She does not use tobacco, alcohol, or illicit drugs. Physical examination shows no focal neurological deficits. Neuroimaging reveals a small aneurysm arising from the segment of right internal carotid artery within the cavernous sinus. If this patient's aneurysm continues to expand, which of the following findings is most likely to be observed?

A. Deviation of the tongue to the right when protruded (2%)

B. Inability to contract the right orbicularis oculi muscle (6%)

C. Loss of sensation from anterior two-thirds of the tongue (4%)

D. Vision defect affecting the left half of the visual field (10%)

✓ E. Weakness of the right lateral rectus muscle (75%)

Omitted
Correct answer
E

75%
Answered correctly

02 secs
Time Spent

05/15/2020
Last Updated

Explanation

Cavernous carotid aneurysm

10
11
12
13
14
15
16
17
18
19
20
21
22
23
24
25
26
27
28
29
30
31
32
33
34
35
36
37
38
39
40

Cavernous carotid aneurysm

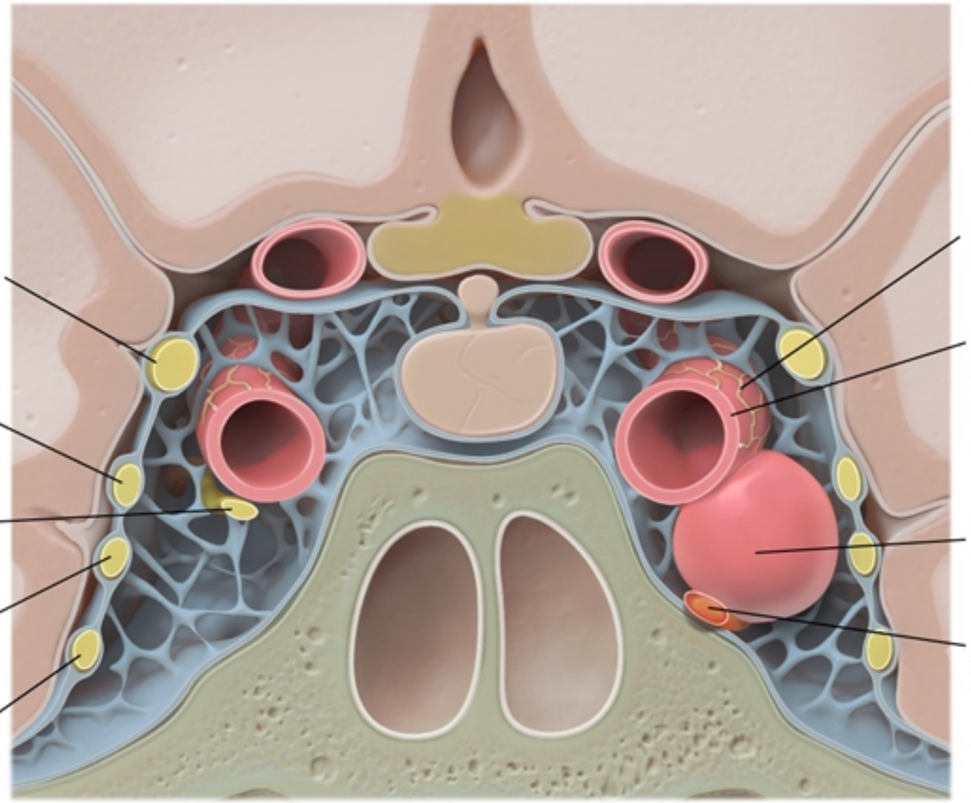

©UWorld

This patient has a **cavernous carotid aneurysm**, which was discovered during an evaluation for a change in headache frequency and severity from past migraines. Small aneurysms of the cavernous segment of the internal carotid artery are typically asymptomatic; however, as they enlarge, they can compress nearby structures and cause a unilateral, throbbing headache and/or cranial nerve deficits.

The **abducens nerve** (CN VI), which passes through the cavernous sinus next to the internal carotid artery, is the most likely structure to be damaged by an expanding aneurysm. Compression or stretching of the nerve results in **ipsilateral lateral rectus weakness**, which can cause

This patient has a **cavernous carotid aneurysm**, which was discovered during an evaluation for a change in headache frequency and severity from past migraines. Small aneurysms of the cavernous segment of the internal carotid artery are typically asymptomatic; however, as they enlarge, they can compress nearby structures and cause a unilateral, throbbing headache and/or cranial nerve deficits.

The **abducens nerve** (CN VI), which passes through the cavernous sinus next to the internal carotid artery, is the most likely structure to be damaged by an expanding aneurysm. Compression or stretching of the nerve results in **ipsilateral lateral rectus weakness**, which can cause esotropia (**inward eye deviation**) and horizontal **diplopia** (double vision) that is worse when looking toward the side of the lesion.

Other nerves that can be damaged by a cavernous carotid aneurysm include the oculomotor nerve (CN III), trochlear nerve (CN IV), and V1 and V2 branches of the trigeminal nerve (CN V), all of which run on the lateral wall of the cavernous sinus.

(Choice A) The hypoglossal nerves (CN XII) innervate the genioglossus muscles, which are responsible for tongue protrusion. Injury to the right hypoglossal nerve (most commonly during carotid endarterectomy) would cause ipsilateral genioglossus weakness with deviation of the tongue to the right during protrusion.

(Choice B) Muscles of facial expression, including the orbicularis oculi, are innervated by the facial nerve (CN VII). Damage to the lower motor neurons of the facial nerve (eg, parotid gland tumor, trauma) often results in complete paralysis of ipsilateral facial muscles.

(Choice C) General sensation from the anterior two-thirds of the tongue is carried by the lingual nerve (mandibular division of the trigeminal nerve), which, unlike the other 2 divisions of the trigeminal nerve, does not course through the cavernous sinus.

(Choice D) Homonymous hemianopia is a defect in half of the visual field due to a contralateral lesion in the visual pathways posterior to the optic chiasm (eg, optic tract, optic radiations). Cavernous carotid aneurysms can occasionally compress the optic nerve or chiasm, usually resulting in ipsilateral monocular vision loss or a nonspecific decrease in visual acuity rather than homonymous hemianopia.

Educational objective:
An expanding aneurysm in the cavernous portion of the internal carotid artery (ICA) is most likely to initially cause headache and diplopia (ipsilateral lateral rectus weakness) due to compressing or stretching of the abducens nerve (CN VI) as it runs next to the ICA in the cavernous sinus. Other commonly affected nerves include the oculomotor nerve (CN III), trochlear nerve (CN IV), and the V1 and V2 branches of the trigeminal nerve (CN V).

10 11 12 13 14 15 16 17 18 19 20 21 22 23 24 25 26 27 28 29 30 31 32 33 34 35 36 37 38 39 40

The **abducens nerve** (CN VI), which passes through the cavernous sinus next to the internal carotid artery, is the most likely structure to be damaged by an expanding aneurysm. Compression or stretching of the nerve results in **ipsilateral lateral rectus weakness**, which can cause esotropia (**inward eye deviation**) and horizontal **diplopia** (double vision) that is worse when looking toward the side of the lesion.

Other nerves that can be damaged by a cavernous carotid aneurysm include the oculomotor nerve (CN III), trochlear nerve (CN IV), and V1 and V2 branches of the trigeminal nerve (CN V), all of which run on the lateral wall of the cavernous sinus.

(Choice A) The hypoglossal nerves (CN XII) innervate the genioglossus muscles, which are responsible for tongue protrusion. Injury to the right hypoglossal nerve (most commonly during carotid endarterectomy) would cause ipsilateral genioglossus weakness with deviation of the tongue to the right during protrusion.

(Choice B) Muscles of facial expression, including the orbicularis oculi, are innervated by the facial nerve (CN VII). Damage to the lower motor neurons of the facial nerve (eg, parotid gland tumor, trauma) often results in complete paralysis of ipsilateral facial muscles.

(Choice C) General sensation from the anterior two-thirds of the tongue is carried by the lingual nerve (mandibular division of the trigeminal nerve), which, unlike the other 2 divisions of the trigeminal nerve, does not course through the cavernous sinus.

(Choice D) Homonymous hemianopia is a defect in half of the visual field due to a contralateral lesion in the visual pathways posterior to the optic chiasm (eg, optic tract, optic radiations). Cavernous carotid aneurysms can occasionally compress the optic nerve or chiasm, usually resulting in ipsilateral monocular vision loss or a nonspecific decrease in visual acuity rather than homonymous hemianopia.

Educational objective:
An expanding aneurysm in the cavernous portion of the internal carotid artery (ICA) is most likely to initially cause headache and diplopia (ipsilateral lateral rectus weakness) due to compressing or stretching of the abducens nerve (CN VI) as it runs next to the ICA in the cavernous sinus. Other commonly affected nerves include the oculomotor nerve (CN III), trochlear nerve (CN IV), and the V1 and V2 branches of the trigeminal nerve (CN V).

Anatomy	Nervous System	Abducens palsy
Subject	System	Topic

Copyright © UWorld. All rights reserved.

10
11
12
13
14
15
16
17
18
19
20
21
22
23
24
25
26
27
28
29
30
31
32
33
34
35
36
37
38
39
40

The **abducens nerve** (CN VI), which passes through the cavernous sinus next to the internal carotid artery, is the most likely structure to be

Exhibit Display

Nerve at risk during carotid endarterectomy

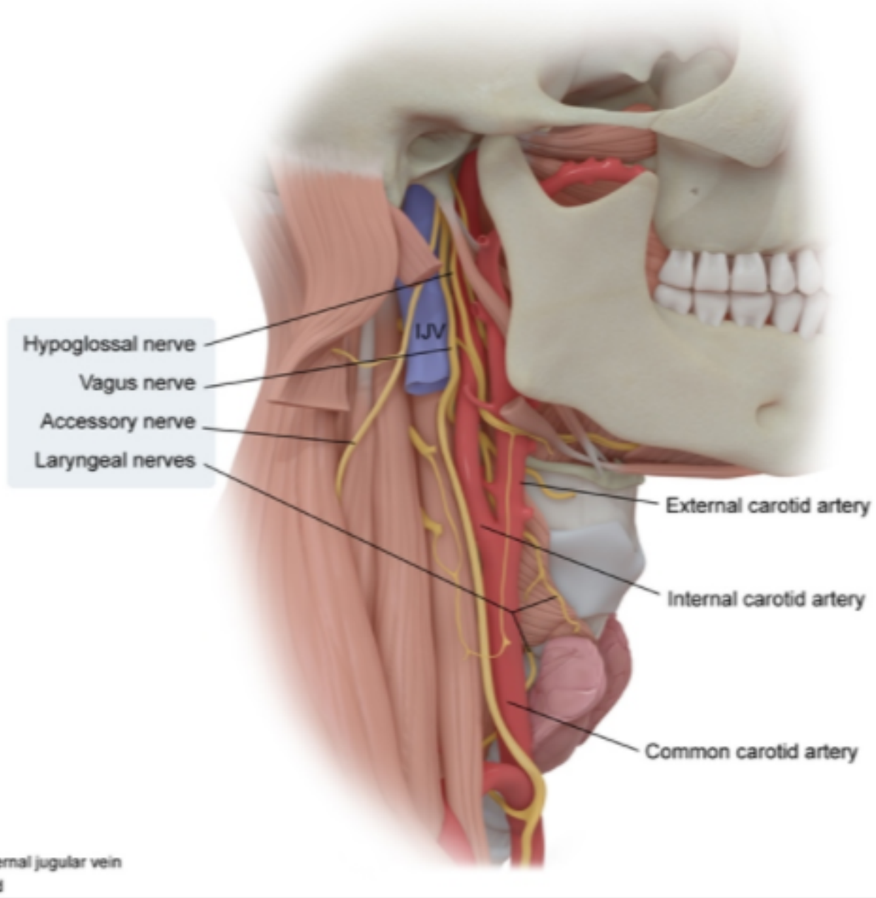

Zoom In | Zoom Out | Reset | Add To New Card | Existing Card

The **abducens nerve** (CN VI), which passes through the cavernous sinus next to the internal carotid artery, is the most likely structure to be

Exhibit Display

Muscles of facial expression

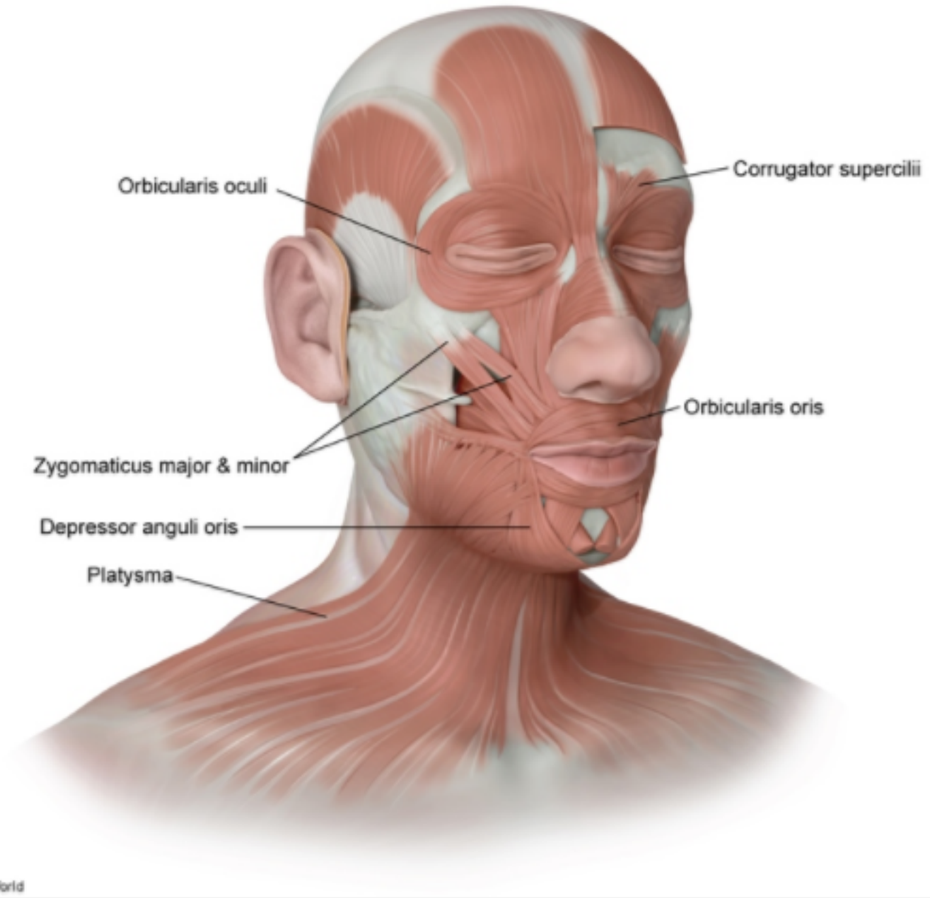

Zoom In | Zoom Out | Reset | Add To New Card | Existing Card

10
11
12
13
14
15
16
17
18
19
20
21
22
23
24
25
26
27
28
29
30
31
32
33
34
35
36
37
38
39
40

A 25-year-old man comes to the office due to right arm weakness. The patient injured his right shoulder several months ago in a motor vehicle accident and has had difficulty elevating his arm since. On examination, there is diminished pinprick and temperature sensation over a small area in the right upper lateral arm and prominent atrophy of the right deltoid with 3/5 strength on right shoulder abduction. Reflexes and handgrip strength are normal in the upper extremities bilaterally. This patient most likely injured which of the following nerves?

A. Axillary
B. Dorsal scapular
C. Long thoracic
D. Median
E. Musculocutaneous
F. Radial
G. Thoracodorsal
H. Ulnar

Submit

A 25-year-old man comes to the office due to right arm weakness. The patient injured his right shoulder several months ago in a motor vehicle accident and has had difficulty elevating his arm since. On examination, there is diminished pinprick and temperature sensation over a small area in the right upper lateral arm and prominent atrophy of the right deltoid with 3/5 strength on right shoulder abduction. Reflexes and handgrip strength are normal in the upper extremities bilaterally. This patient most likely injured which of the following nerves?

- ✓ A. Axillary (84%)
- B. Dorsal scapular (4%)
- C. Long thoracic (1%)
- D. Median (0%)
- E. Musculocutaneous (6%)
- F. Radial (1%)
- G. Thoracodorsal (1%)
- H. Ulnar (0%)

Omitted
Correct answer
A

84%
Answered correctly

02 secs
Time Spent

04/13/2020
Last Updated

Explanation

Axillary nerve

10
11
12
13
14
15
16
17
18
19
20
21
22
23
24
25
26
27
28
29
30
31
32
33
34
35
36
37
38
39
40

Axillary nerve
(posterior view)

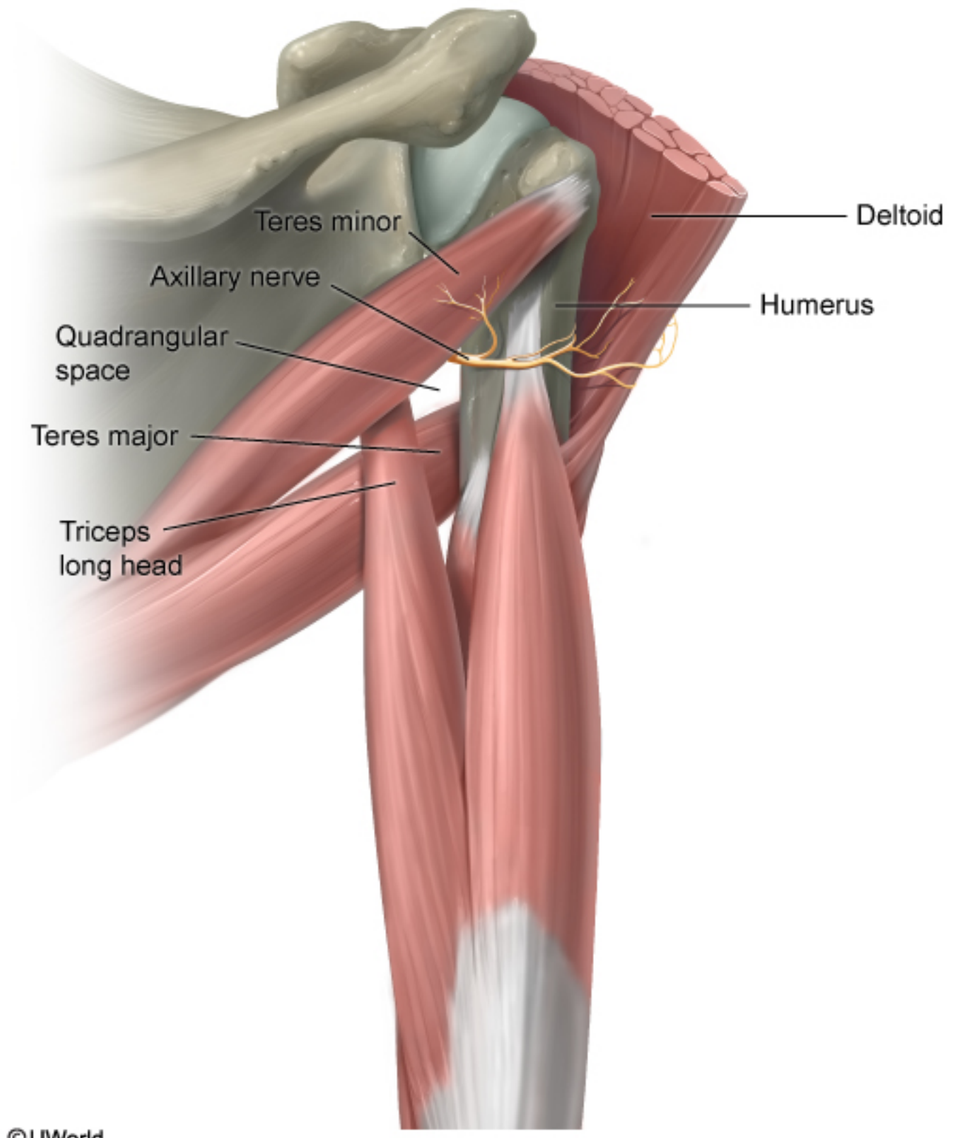

©UWorld

The axillary nerve originates from the posterior cord of the brachial plexus and carries fibers from C5 and C6. It courses deep in the axilla below the shoulder joint, then runs through the quadrangular space (bounded superiorly by the teres minor, laterally by the humerus, medially by the long head of the triceps, and inferiorly by the teres major) and along the surgical neck of the posterior humerus. At this point, it gives rise to motor branches that supply the deltoid and teres minor muscles, and a sensory branch that innervates the skin over the lateral shoulder.

Axillary nerve injury most commonly occurs in the setting of shoulder trauma (eg, anterior dislocation, proximal humeral fracture). Patients often have sensory loss over the upper lateral arm and weakness on shoulder abduction due to denervation (and possibly atrophy) of the deltoid muscle.

(Choice B) The dorsal scapular nerve provides motor innervation to the rhomboids (retract the scapula) and levator scapulae muscles (elevate the scapula).

(Choice C) Long thoracic nerve injury classically occurs during axillary lymph node dissection and results in paralysis of the serratus anterior muscle, leading to winging of the scapula.

(Choice D) Proximal injury to the median nerve (eg, due to supracondylar humerus fracture) may result in palmar sensory loss over the first 3 digits and impairment of thumb flexion/opposition, flexion of the second/third digits, and wrist flexion/abduction.

(Choice E) Injury to the musculocutaneous nerve can cause sensory loss over the lateral forearm and weakened elbow flexion due to denervation of the biceps brachii and brachialis muscles.

(Choice F) Injury to the radial nerve at the axilla (eg, "crutch palsy") typically causes weakness of the forearm, hand, and finger extensor muscles (eg, wrist drop, absent triceps reflex) with sensory loss over the posterior arm, forearm, and dorsolateral hand.

(Choice G) The thoracodorsal nerve provides motor innervation to the latissimus dorsi muscle, which is responsible for shoulder extension, adduction, and internal rotation.

(Choice H) Ulnar nerve injury most commonly occurs at the elbow, resulting in sensory loss over the medial 1½ digits of the hand and weakness on wrist flexion/adduction, finger abduction/adduction, and flexion of the fourth/fifth digits.

Educational objective:
Injury to the axillary nerve most commonly occurs in the setting of shoulder trauma (eg, anterior dislocation, humeral fracture) and presents with

The axillary nerve originates from the posterior cord of the brachial plexus and carries fibers from C5 and C6. It courses deep in the axilla below the shoulder joint, then runs through the quadrangular space (bounded superiorly by the teres minor, laterally by the humerus, medially by the long head of the triceps, and inferiorly by the teres major) and along the surgical neck of the posterior humerus. At this point, it gives rise to motor branches that supply the deltoid and teres minor muscles, and a sensory branch that innervates the skin over the lateral shoulder.

Axillary nerve injury most commonly occurs in the setting of shoulder trauma (eg, anterior dislocation, proximal humeral fracture). Patients often have sensory loss over the upper lateral arm and weakness on shoulder abduction due to denervation (and possibly atrophy) of the deltoid muscle.

(Choice B) The dorsal scapular nerve provides motor innervation to the rhomboids (retract the scapula) and levator scapulae muscles (elevate the scapula).

(Choice C) Long thoracic nerve injury classically occurs during axillary lymph node dissection and results in paralysis of the serratus anterior muscle, leading to winging of the scapula.

(Choice D) Proximal injury to the median nerve (eg, due to supracondylar humerus fracture) may result in palmar sensory loss over the first 3 digits and impairment of thumb flexion/opposition, flexion of the second/third digits, and wrist flexion/abduction.

(Choice E) Injury to the musculocutaneous nerve can cause sensory loss over the lateral forearm and weakened elbow flexion due to denervation of the biceps brachii and brachialis muscles.

(Choice F) Injury to the radial nerve at the axilla (eg, "crutch palsy") typically causes weakness of the forearm, hand, and finger extensor muscles (eg, wrist drop, absent triceps reflex) with sensory loss over the posterior arm, forearm, and dorsolateral hand.

(Choice G) The thoracodorsal nerve provides motor innervation to the latissimus dorsi muscle, which is responsible for shoulder extension, adduction, and internal rotation.

(Choice H) Ulnar nerve injury most commonly occurs at the elbow, resulting in sensory loss over the medial 1½ digits of the hand and weakness on wrist flexion/adduction, finger abduction/adduction, and flexion of the fourth/fifth digits.

Educational objective:
Injury to the axillary nerve most commonly occurs in the setting of shoulder trauma (eg, anterior dislocation, humeral fracture) and presents with

10
11
12
13
14
15
16
17
18
19
20
21
22
23
24
25
26
27
28
29
30
31
32
33
34
35
36
37
38
39
40

Exhibit Display

Axillary nerve

Motor function	Cutaneous innervation
Abduction of arm at shoulder beyond first 15 degrees	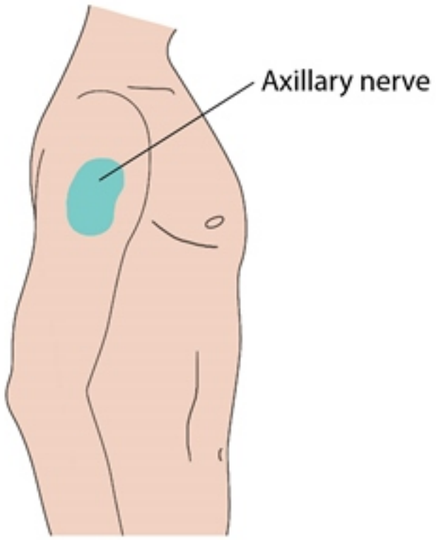

©UWorld

Zoom In | Zoom Out | Reset | Add To New Card | Existing Card

Injury to the axillary nerve most commonly occurs in the setting of shoulder trauma (eg, anterior dislocation, humeral fracture) and presents with

10
11
12
13
14
15
16
17
18
19
20
21
22
23
24
25
26
27
28
29
30
31
32
33
34
35
36
37
38
39
40

Exhibit Display

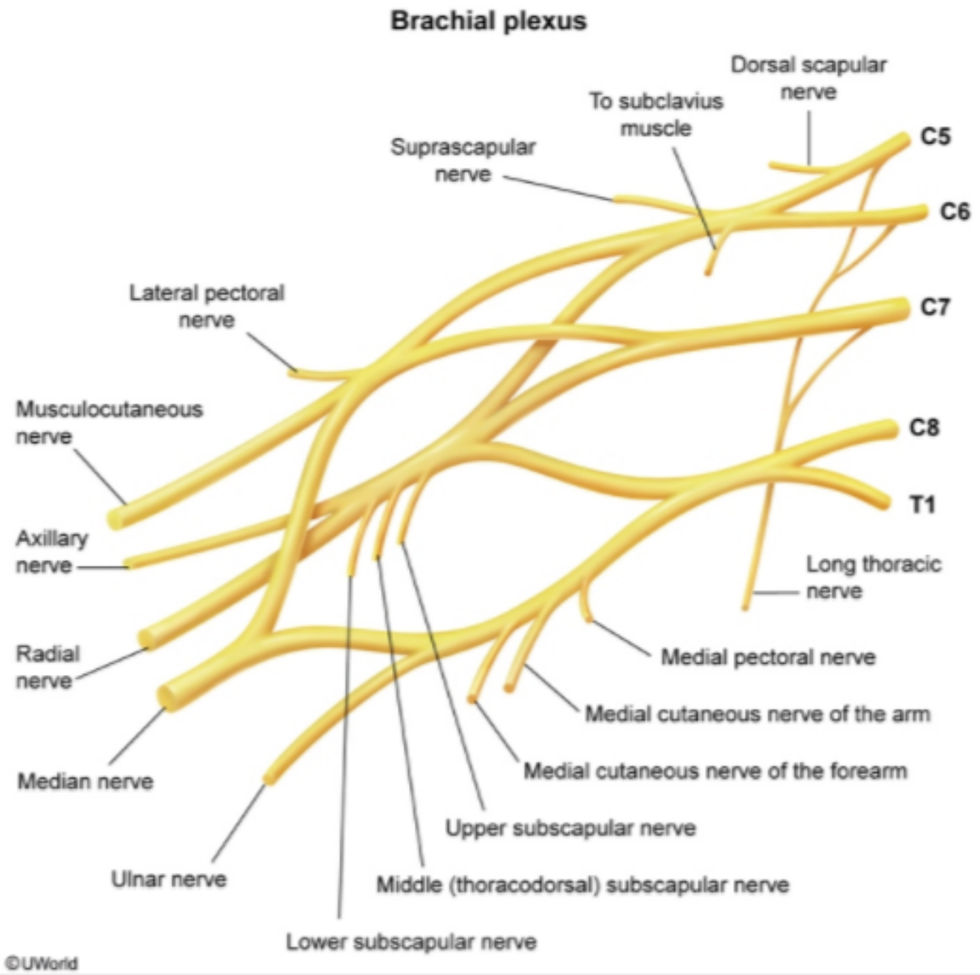

Zoom In | Zoom Out | Reset | Add To New Card | Existing Card

Injury to the axillary nerve most commonly occurs in the setting of shoulder trauma (eg, anterior dislocation, humeral fracture) and presents with

the scapula).

(Choice C) Long thoracic nerve injury classically occurs during axillary lymph node dissection and results in paralysis of the serratus anterior muscle, leading to winging of the scapula.

(Choice D) Proximal injury to the median nerve (eg, due to supracondylar humerus fracture) may result in palmar sensory loss over the first 3 digits and impairment of thumb flexion/opposition, flexion of the second/third digits, and wrist flexion/abduction.

(Choice E) Injury to the musculocutaneous nerve can cause sensory loss over the lateral forearm and weakened elbow flexion due to denervation of the biceps brachii and brachialis muscles.

(Choice F) Injury to the radial nerve at the axilla (eg, "crutch palsy") typically causes weakness of the forearm, hand, and finger extensor muscles (eg, wrist drop, absent triceps reflex) with sensory loss over the posterior arm, forearm, and dorsolateral hand.

(Choice G) The thoracodorsal nerve provides motor innervation to the latissimus dorsi muscle, which is responsible for shoulder extension, adduction, and internal rotation.

(Choice H) Ulnar nerve injury most commonly occurs at the elbow, resulting in sensory loss over the medial 1½ digits of the hand and weakness on wrist flexion/adduction, finger abduction/adduction, and flexion of the fourth/fifth digits.

Educational objective:
Injury to the axillary nerve most commonly occurs in the setting of shoulder trauma (eg, anterior dislocation, humeral fracture) and presents with sensory loss over the lateral shoulder and weakness on shoulder abduction (due to denervation of the deltoid muscle).

References

- Peripheral nerve entrapment and injury in the upper extremity.
- Axillary nerve injury.

Anatomy	Nervous System	Axillary nerve injury
Subject	System	Topic

Copyright © UWorld. All rights reserved.

10
11
12
13
14
15
16
17
18
19
20
21
22
23
24
25
26
27
28
29
30
31
32
33
34
35
36
37
38
39
40

A 38-year-old man is brought to the office for evaluation of behavioral changes. His wife says the patient has had frequent outbursts of anger, depressive mood, and insomnia. The patient recently lost his job as a machine operator because of lack of focus and poor memory. Over the past several years, he also has had involuntary, jerky, nonpurposeful movements of the extremities and face that have progressively worsened. These abnormal movements are present while he is awake but not during sleep. His 55-year-old mother has similar abnormal body movements and is at a nursing home with dementia. Which of the following labeled regions of a normal brain is most likely to be affected by this patient's disease process?

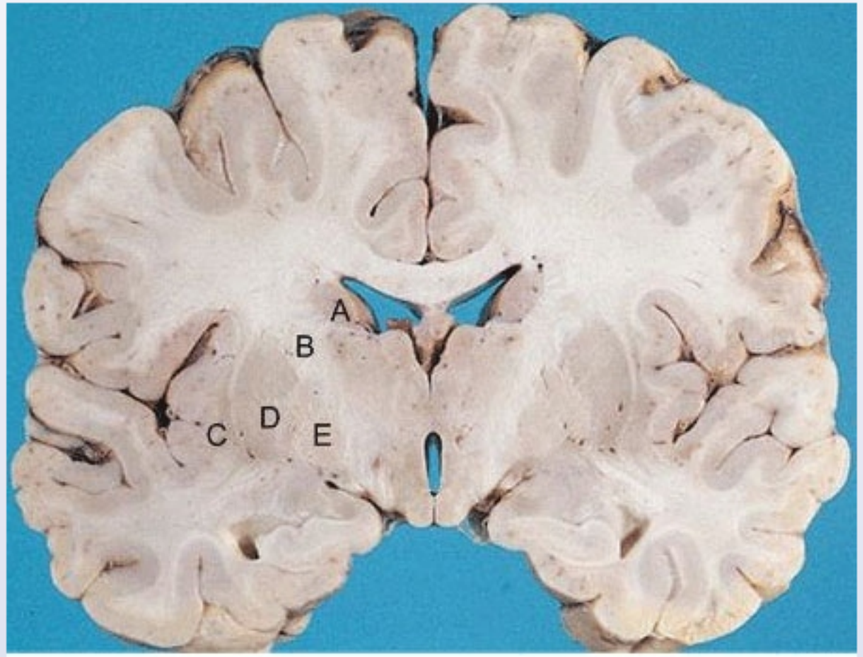

Displayed with permission from Springer Healthcare Ltd.
©Copyright 1995, 2004 by Current Medicine

A. A

B. B

10
11
12
13
14
15
16
17
18
19
20
21
22
23
24
25
26
27
28
29
30
31
32
33
34
35
36
37
38
39
40

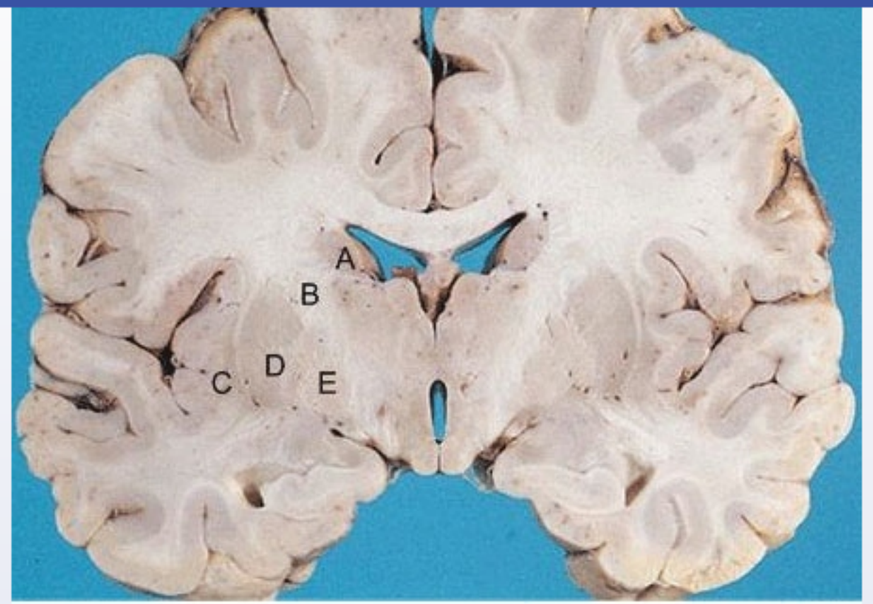

Displayed with permission from Springer Healthcare Ltd.
©Copyright 1995, 2004 by Current Medicine

A. A

B. B

C. C

D. D

E. E

Submit

10
11
12
13
14
15
16
17
18
19
20
21
22
23
24
25
26
27
28
29
30
31
32
33
34
35
36
37
38
39
40

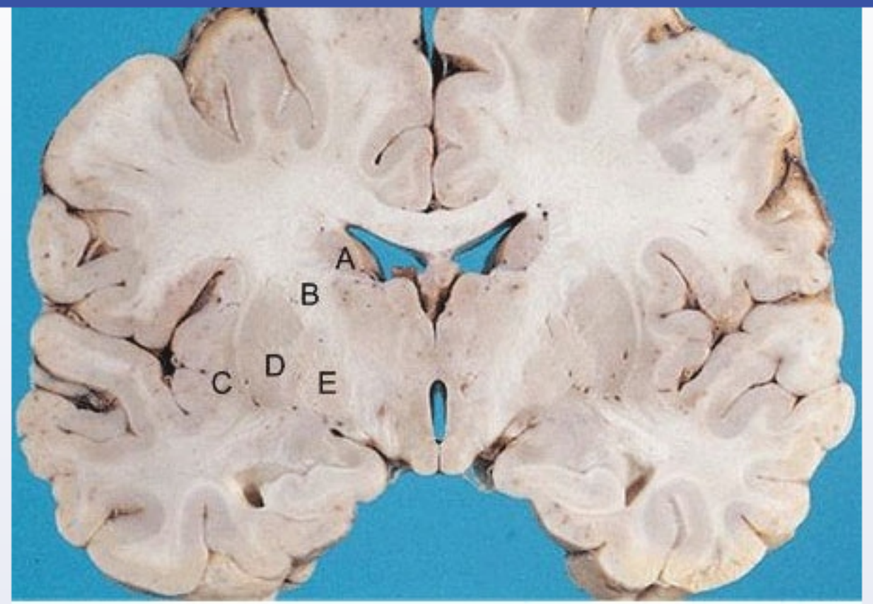

Displayed with permission from Springer Healthcare Ltd.
©Copyright 1995, 2004 by Current Medicine

- ✓ A. A (69%)
- B. B (2%)
- C. C (3%)
- D. D (13%)
- E. E (10%)

Omitted
Correct answer

69%
Answered correctly

04 secs
Time Spent

04/07/2020
Last Updated

10
11
12
13
14
15
16
17
18
19
20
21
22
23
24
25
26
27
28
29
30
31
32
33
34
35
36
37
38
39
40

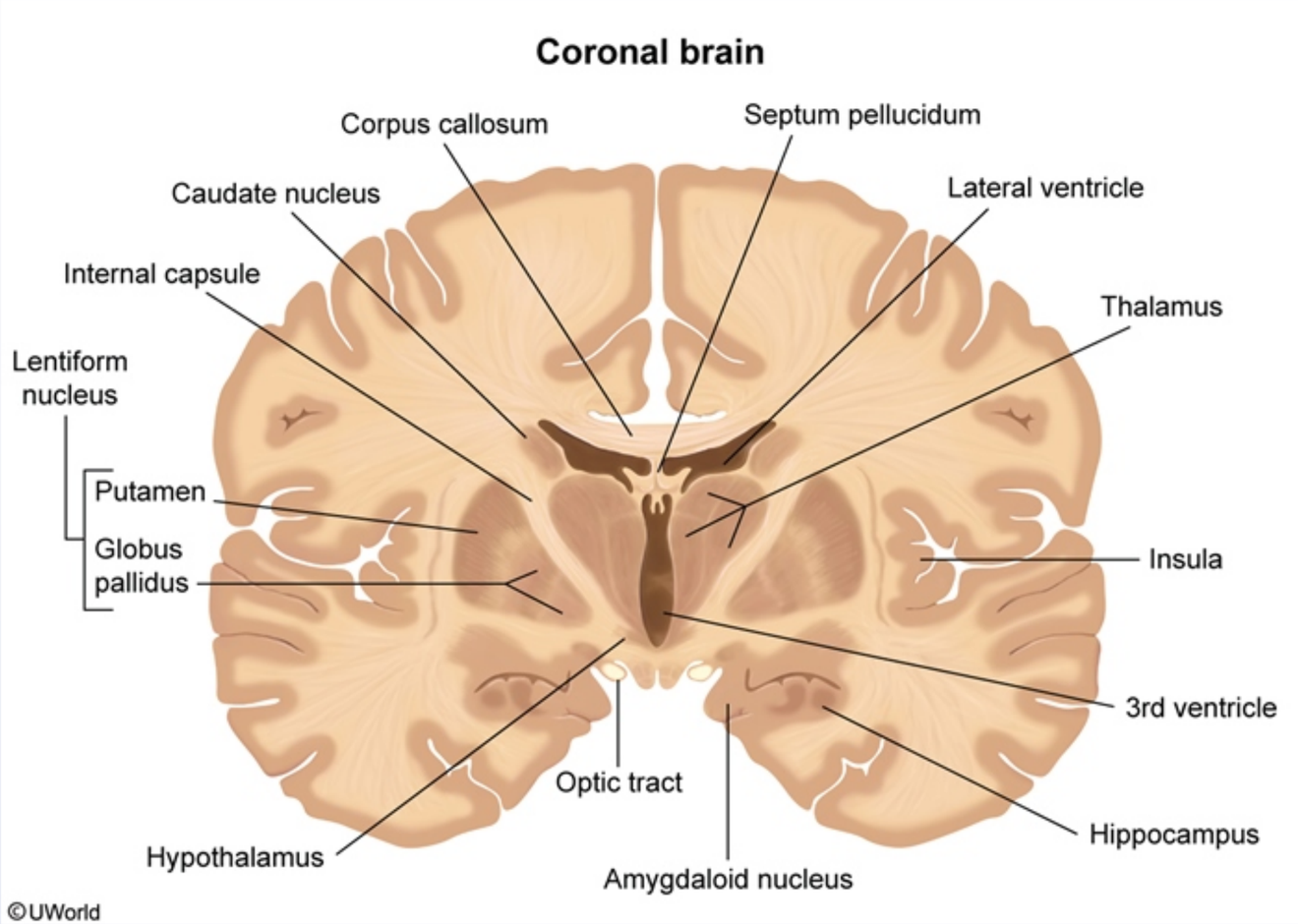

This patient's cognitive decline, chorea (jerky, nonpurposeful movements), and family history of similar symptoms are highly suggestive of **Huntington disease** (HD). This autosomal dominant disease results from an excessive number of **CAG trinucleotide repeats** in the huntingtin gene, causing a gain-of-function mutation that results in the accumulation of toxic mutant huntingtin protein. The abnormal protein buildup causes **loss of inhibitory (GABA) neurons** in the caudate nucleus, leading to the characteristic movement abnormalities observed in HD.

This patient's cognitive decline, chorea (jerky, nonpurposeful movements), and family history of similar symptoms are highly suggestive of **Huntington disease** (HD). This autosomal dominant disease results from an excessive number of **CAG trinucleotide repeats** in the huntingtin gene, causing a gain-of-function mutation that results in the accumulation of toxic mutant huntingtin protein. The abnormal protein buildup causes **loss of inhibitory (GABA) neurons** in the caudate nucleus, leading to the characteristic movement abnormalities observed in HD.

Although the diagnosis of HD is confirmed by genetic analysis, imaging studies can support the clinical findings and typically show **atrophy of the caudate nuclei**, causing enlargement of the lateral ventricles. The caudate nucleus is a curved or C-shaped structure in its complete form. The head of the caudate can be identified in the inferolateral walls of the frontal horns of the lateral ventricles. The caudate nucleus and putamen together make up the striatum, which is critical for movement control and coordination along with behavioral regulation.

(Choice B) This structure is the internal capsule. The anterior limb of the internal capsule separates the caudate nucleus from the globus pallidus and putamen and carries a portion of the thalamocortical fibers. The posterior limb of the internal capsule separates the globus pallidus and putamen from the thalamus and carries corticospinal motor and somatic sensory fibers as well as visual and auditory fibers.

(Choice C) This structure is the insular cortex (insula). The insula plays a role in the limbic system (emotion) as well as in the coordination of some autonomic functions.

(Choice D) Although the putamen does atrophy in Huntington disease, this change is not as significant or as specific to Huntington disease as atrophy of the caudate nucleus.

(Choice E) Atrophy of the globus pallidus is observed late in the progression of HD when generalized cortical atrophy occurs.

Educational objective:
The head of the caudate lies in the inferolateral wall of the frontal horn of the lateral ventricle. It is separated from the globus pallidus and putamen by the internal capsule. Atrophy of the caudate nuclei with enlargement of the lateral ventricles is characteristic of Huntington disease and can be observed on neuroimaging.

Anatomy	Nervous System	Huntington disease
Subject	System	Topic

Copyright © UWorld. All rights reserved.

10
11
12
13
14
15
16
17
18
19
20
21
22
23
24
25
26
27
28
29
30
31
32
33
34
35
36
37
38
39
40

Exhibit Display

Anatomy of the basal ganglia

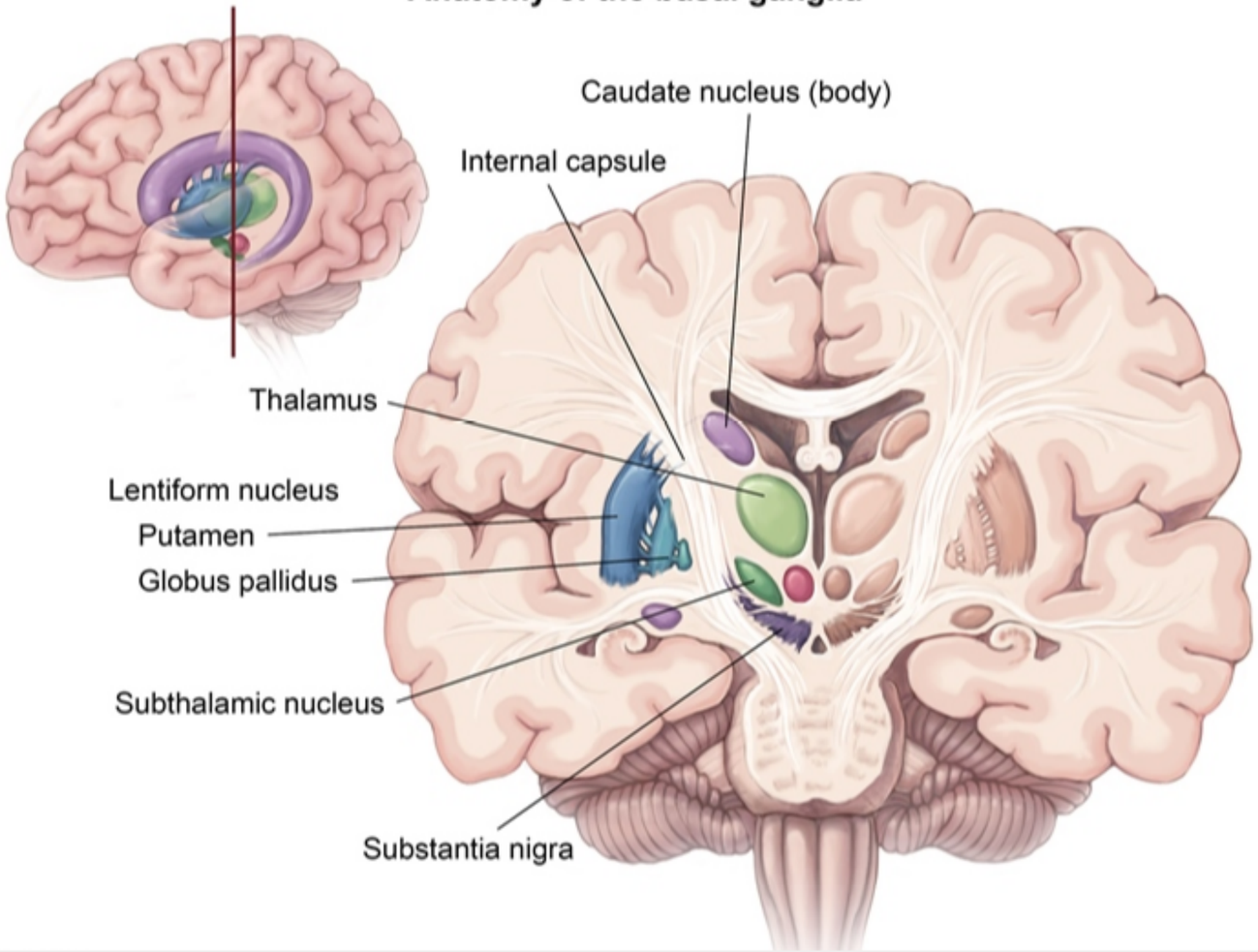

Zoom In | Zoom Out | Reset | Add To New Card | Existing Card

Copyright © UWorld. All rights reserved.

A 69-year-old hospitalized woman is evaluated for new-onset weakness of the right foot. The patient has a history of chronic hip pain due to osteoarthritis and underwent left total hip arthroplasty under general anesthesia while in the right lateral decubitus position 2 days ago. Since the surgery, she has had difficulty moving her right foot. Other medical conditions include lumbar spinal stenosis, hypertension, type 2 diabetes mellitus, and a small ischemic stroke with no residual deficit. On examination of the right lower extremity, the patient is unable to dorsiflex or evert the foot or extend the toes. Sensation is decreased over the dorsum of the right foot. The rest of the neurologic examination of the right lower extremity is normal. Injury to which of the following structures is the most likely cause of this patient's current symptoms?

- A. Common fibular nerve
- B. Deep fibular nerve
- C. Femoral nerve
- D. Lateral sural cutaneous nerve
- E. Lumbosacral spinal nerve roots
- F. Sciatic nerve
- G. Tibial nerve

Submit

A 69-year-old hospitalized woman is evaluated for new-onset weakness of the right foot. The patient has a history of chronic hip pain due to osteoarthritis and underwent left total hip arthroplasty under general anesthesia while in the right lateral decubitus position 2 days ago. Since the surgery, she has had difficulty moving her right foot. Other medical conditions include lumbar spinal stenosis, hypertension, type 2 diabetes mellitus, and a small ischemic stroke with no residual deficit. On examination of the right lower extremity, the patient is unable to dorsiflex or evert the foot or extend the toes. Sensation is decreased over the dorsum of the right foot. The rest of the neurologic examination of the right lower extremity is normal. Injury to which of the following structures is the most likely cause of this patient's current symptoms?

- ✓ A. Common fibular nerve (70%)
- B. Deep fibular nerve (13%)
- C. Femoral nerve (1%)
- D. Lateral sural cutaneous nerve (1%)
- E. Lumbosacral spinal nerve roots (1%)
- F. Sciatic nerve (3%)
- G. Tibial nerve (7%)

Omitted
Correct answer
A

70%
Answered correctly

02 secs
Time Spent

02/18/2020
Last Updated

Explanation

Sciatic nerve

10
11
12
13
14
15
16
17
18
19
20
21
22
23
24
25
26
27
28
29
30
31
32
33
34
35
36
37
38
39
40

Sciatic nerve

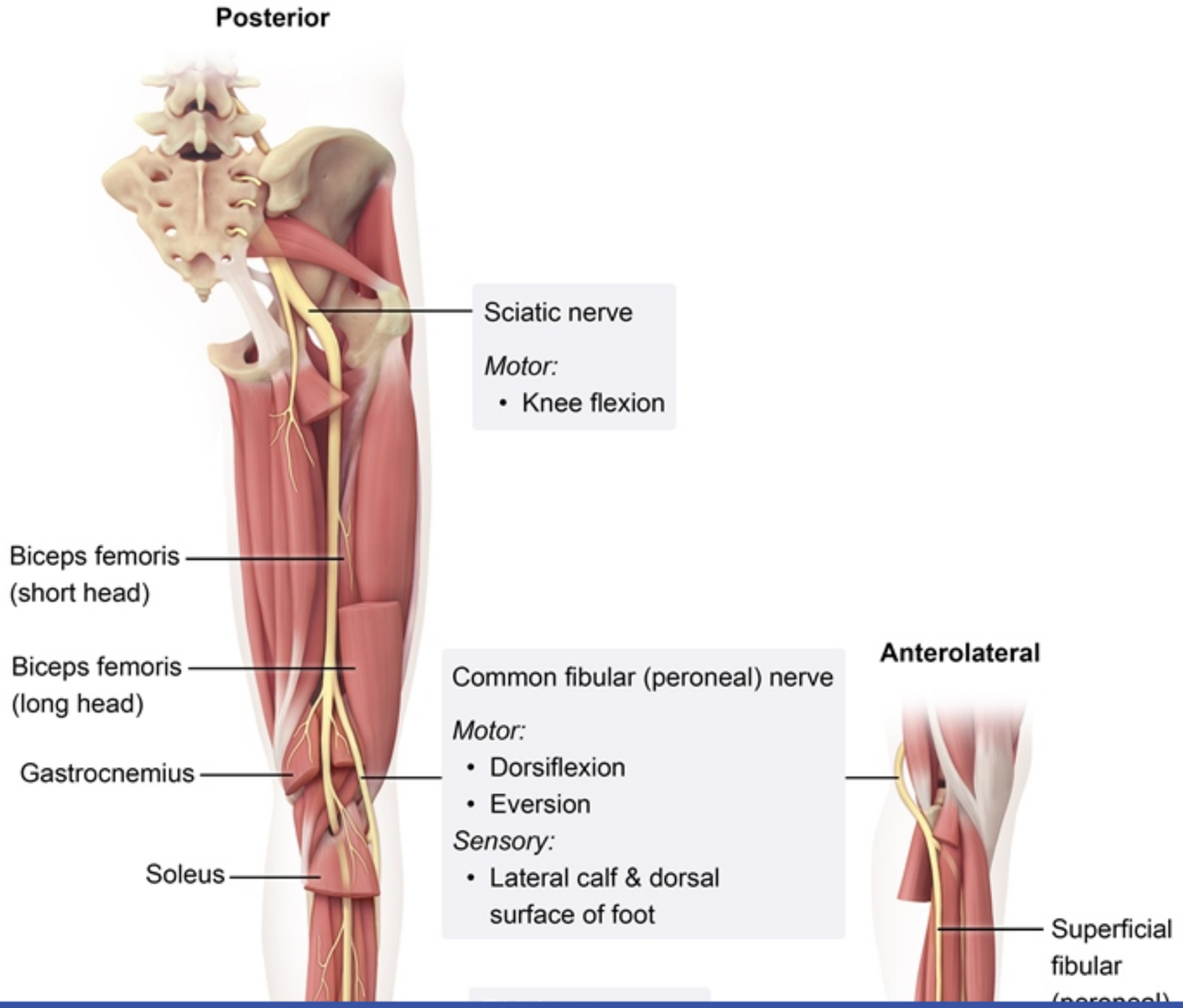

10
11
12
13
14
15
16
17
18
19
20
21
22
23
24
25
26
27
28
29
30
31
32
33
34
35
36
37
38
39
40

Exhibit Display

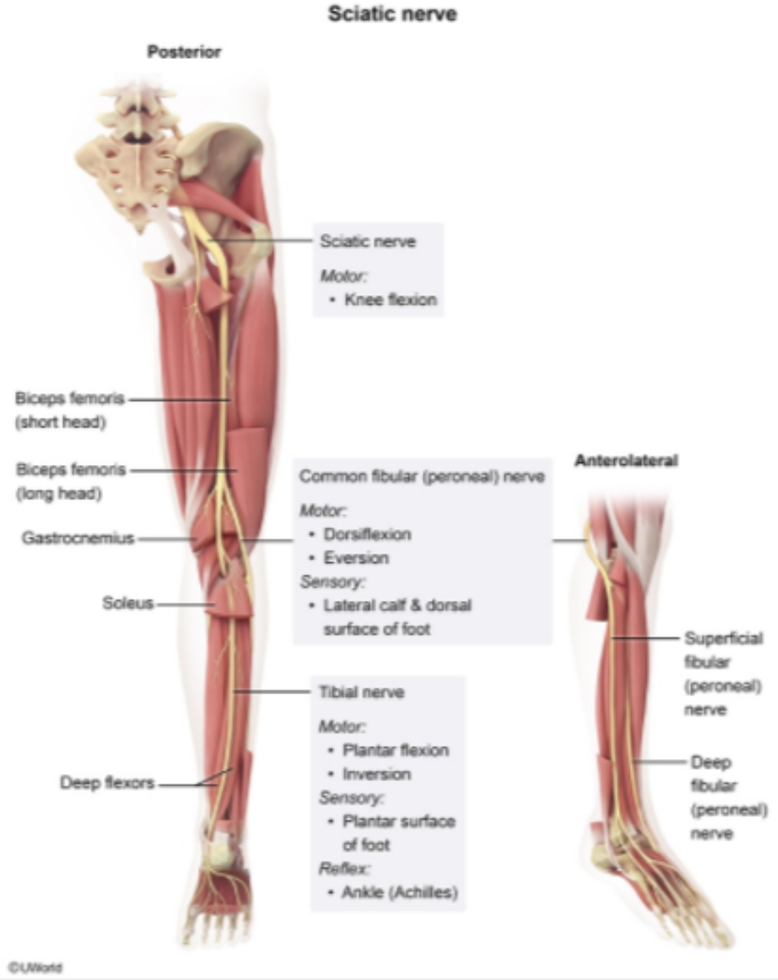

Zoom In | Zoom Out | Reset | Add To New Card | Existing Card

(peroneal)

10
11
12
13
14
15
16
17
18
19
20
21
22
23
24
25
26
27
28
29
30
31
32
33
34
35
36
37
38
39
40

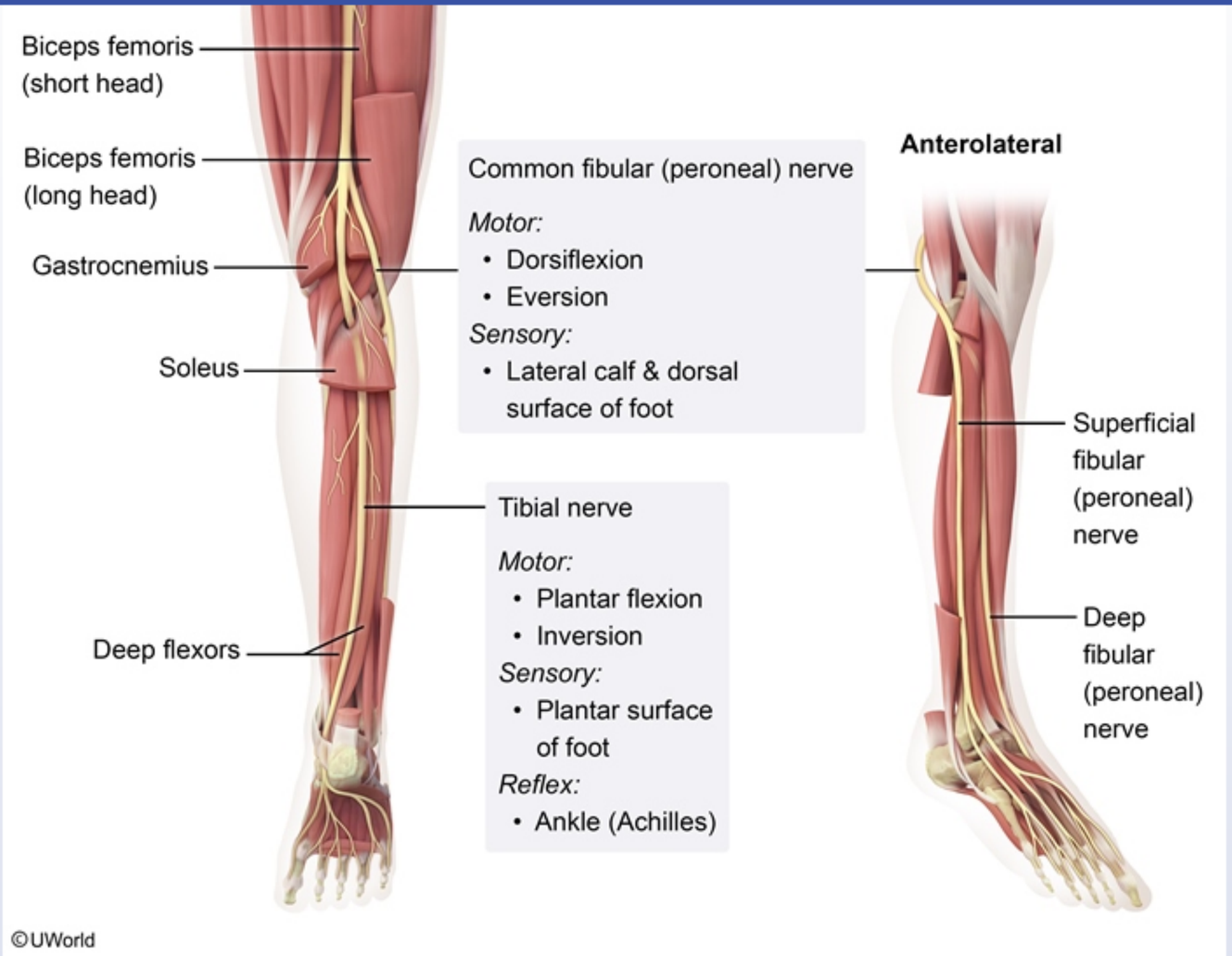

The **common fibular** (peroneal) nerve originates in the popliteal fossa as the lateral branch of the sciatic nerve. From there, it courses laterally around the head and neck of the fibula before dividing into the deep and superficial fibular nerves. Because of its proximity to the **lateral neck** of the **fibula**, the common fibular nerve is particularly susceptible to **compression** from a leg cast or during prolonged time in the lateral decubitus position (eg, during surgical procedures).

The **common fibular** (peroneal) nerve originates in the popliteal fossa as the lateral branch of the sciatic nerve. From there, it courses laterally around the head and neck of the fibula before dividing into the deep and superficial fibular nerves. Because of its proximity to the **lateral neck** of the **fibula**, the common fibular nerve is particularly susceptible to **compression** from a leg cast or during prolonged time in the lateral decubitus position (eg, during surgical procedures).

Common fibular neuropathy characteristically presents with deficits involving both the deep fibular (eg, weakness in foot dorsiflexion and toe extension) and the superficial fibular (eg, weakness in foot eversion, sensory loss over the dorsal foot) nerves **(Choice B)**. In an ambulatory patient, gait examination typically shows **foot drop** due to loss of dorsiflexion, with the affected foot lifted high off the ground to compensate (ie, steppage gait).

(Choice C) Although the femoral nerve is rarely injured during hip replacement, this injury would result in weakness on hip flexion and knee extension along with loss of sensation over the anterior thigh.

(Choice D) The lateral sural cutaneous nerve is a branch of the common fibular nerve that provides sensory innervation to the posterolateral leg; it does not provide motor innervation.

(Choice E) Irritation of the lumbosacral spinal nerve roots can cause variable sensorimotor deficits due to the involvement of multiple myotomes and dermatomes. This patient's sensorimotor findings are specific for common fibular nerve injury.

(Choice F) The most common cause of proximal sciatic nerve injury is trauma or surgery involving the hip joint. However, sciatic nerve injury causes deficits in the fibular, tibial, and sural nerve distributions, with loss of sensation over the posterior leg and weakness involving the hamstrings and most of the muscles of the lower leg.

(Choice G) The tibial nerve can be injured at the knee by trauma or compression (eg, Baker cyst in the popliteal fossa). Proximal tibial neuropathy usually causes weakness in foot plantar flexion and decreased sensation over the sole of the foot.

Educational objective:
The common fibular nerve is susceptible to injury at the lateral neck of the fibula due to compression (ie, prolonged lying on the affected side) or fracture. Patients typically have weakness in foot dorsiflexion, foot eversion, and toe extension along with sensory loss over the lateral leg and dorsal foot.

References

- Entrapment neuropathies of the lower extremity

10
11
12
13
14
15
16
17
18
19
20
21
22
23
24
25
26
27
28
29
30
31
32
33
34
35
36
37
38
39
40

A 45-year-old woman is evaluated for numbness and painful tingling of the right hand. The symptoms began 2 months ago and are especially prominent after she plays tennis. On examination, there is diminished sensation in the lateral palm, thenar eminence, and palmar aspect of the first 3½ digits of the right hand. This patient most likely has an injury involving a nerve that courses between which of the following structures?

A. Biceps and coracobrachialis muscles

B. Flexor carpi ulnaris and flexor digitorum profundus muscles

C. Humeral and ulnar heads of the pronator teres muscle

D. Olecranon and the medial epicondyle of the humerus

E. Supinator muscle and the head of the radius

Submit

A 45-year-old woman is evaluated for numbness and painful tingling of the right hand. The symptoms began 2 months ago and are especially prominent after she plays tennis. On examination, there is diminished sensation in the lateral palm, thenar eminence, and palmar aspect of the first 3½ digits of the right hand. This patient most likely has an injury involving a nerve that courses between which of the following structures?

- A. Biceps and coracobrachialis muscles (9%)
- B. Flexor carpi ulnaris and flexor digitorum profundus muscles (25%)
- ✓ C. Humeral and ulnar heads of the pronator teres muscle (29%)
- D. Olecranon and the medial epicondyle of the humerus (13%)
- E. Supinator muscle and the head of the radius (21%)

Omitted
Correct answer
C

29%
Answered correctly

01 sec
Time Spent

03/25/2020
Last Updated

Explanation

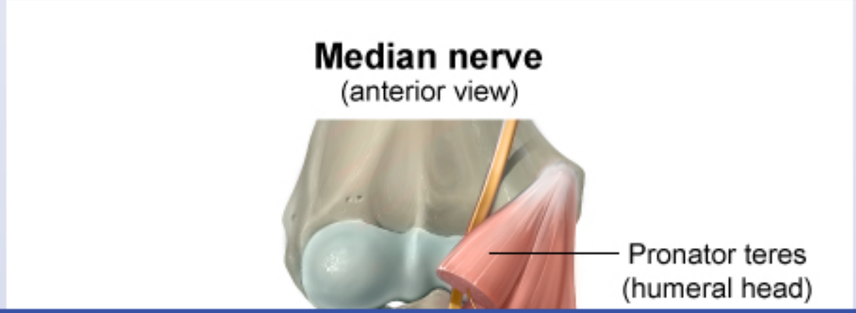

10
11
12
13
14
15
16
17
18
19
20
21
22
23
24
25
26
27
28
29
30
31
32
33
34
35
36
37
38
39
40

Median nerve
(anterior view)

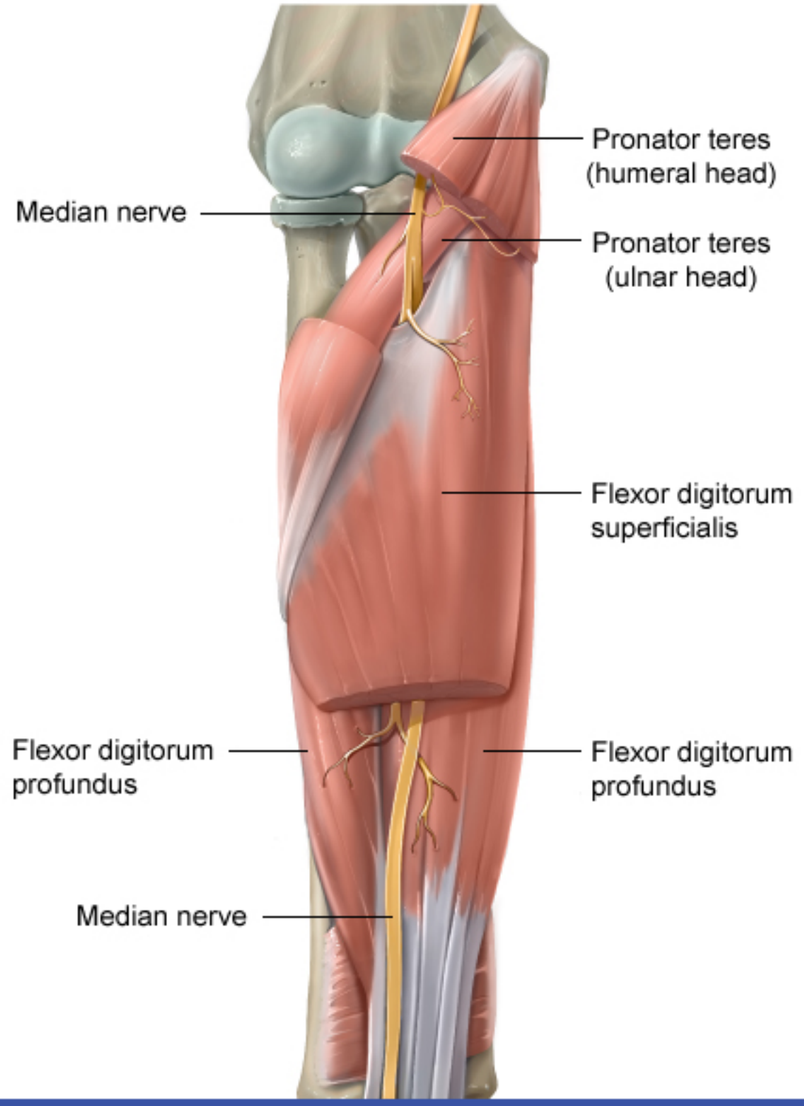

10
11
12
13
14
15
16
17
18
19
20
21
22
23
24
25
26
27
28
29
30
31
32
33
34
35
36
37
38
39
40

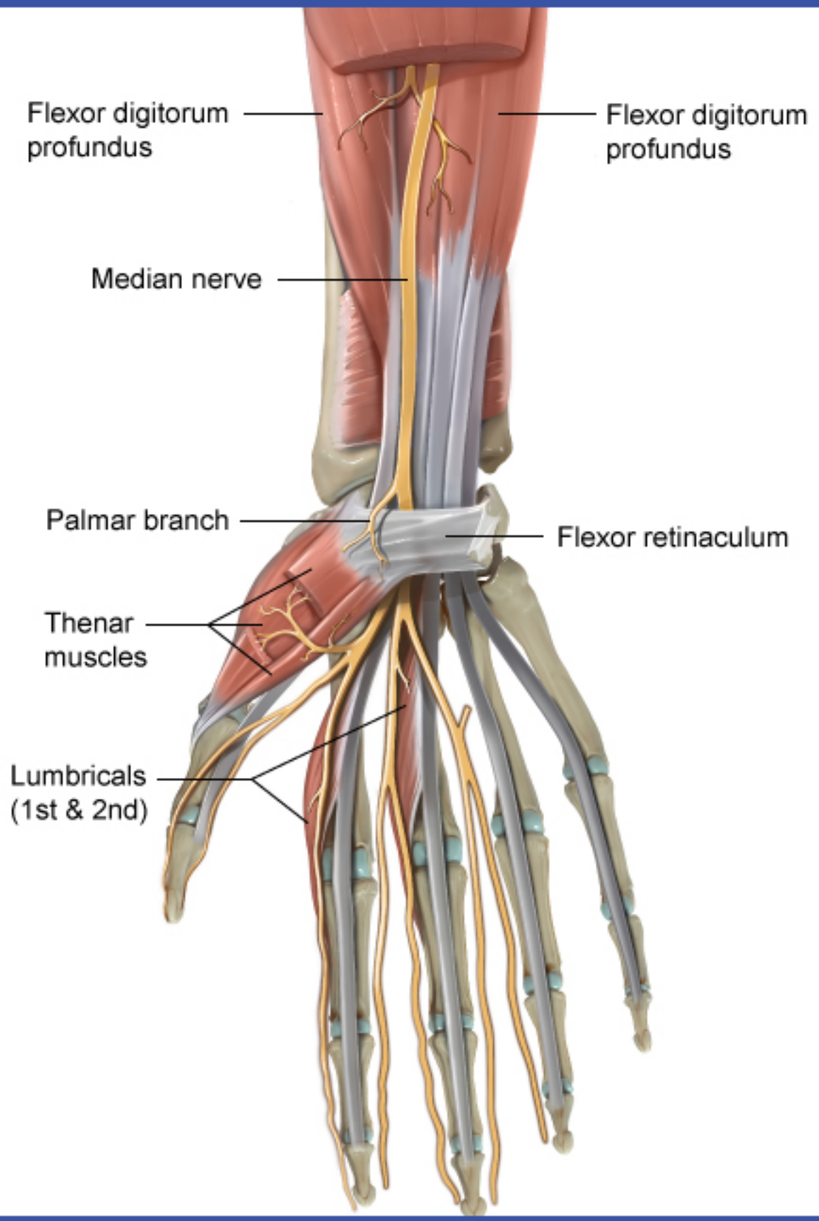

©UWorld

This patient has diminished sensation that involves the entire sensory distribution of the median nerve and is exacerbated by repetitive, forceful pronation (eg, tennis). This presentation is most consistent with compression of the median nerve as it passes between the two heads of the pronator teres (ie, pronator teres syndrome).

The median nerve arises from the medial and lateral cords of the brachial plexus and travels with the brachial artery in the medial bicipital groove (ie, longitudinal hollow between the biceps brachii and triceps brachii muscles) of the upper arm. In the forearm, the median nerve **courses between** the humeral and ulnar **heads of the pronator teres muscle** and between the flexor digitorum superficialis and flexor digitorum profundus muscles before entering the hand through the carpal tunnel.

Median nerve **compression at the carpal tunnel**, which is distal to the takeoff of the palmar branch, typically **impairs sensation** to the palmar aspects of the **first 3½ digits**. In contrast, **compression by the pronator teres** occurs proximal to the takeoff of the palmar branch; therefore, sensation is impaired not only to the palmar aspect of the first 3½ digits but also to the **entire lateral palm** and thenar eminence (ie, sensory distribution of the palmar branch).

(Choice A) The musculocutaneous nerve courses between the biceps brachii and coracobrachialis muscles in the upper arm. Injury (eg, trauma, shoulder dislocation) can cause sensory loss over the lateral forearm.

(Choices B and D) The ulnar nerve courses between the olecranon and the medial epicondyle of the humerus (ie, the cubital tunnel) before passing between the flexor carpi ulnaris and flexor digitorum profundus muscles in the forearm. Ulnar nerve injury at the elbow (eg, compression, trauma) can cause sensory loss in the dorsomedial hand, medial palm, and medial 1½ digits.

(Choice E) The deep branch of the radial nerve (ie, posterior interosseous nerve) courses between the supinator muscle and the head of the radius in the upper forearm. Injury (eg, humeral fracture, compression) can cause sensory loss in the posterior forearm, dorsolateral hand, and dorsal thumb.

Educational objective:
In the forearm, the median nerve courses between the humeral and ulnar heads of the pronator teres muscle and between the flexor digitorum superficialis and flexor digitorum profundus muscles. Compression prior to the takeoff of the palmar branch (eg, between the heads of the pronator teres) results in sensory loss over the lateral palm and palmar aspects of the first 3½ digits.

References

©UWorld

Exhibit Display

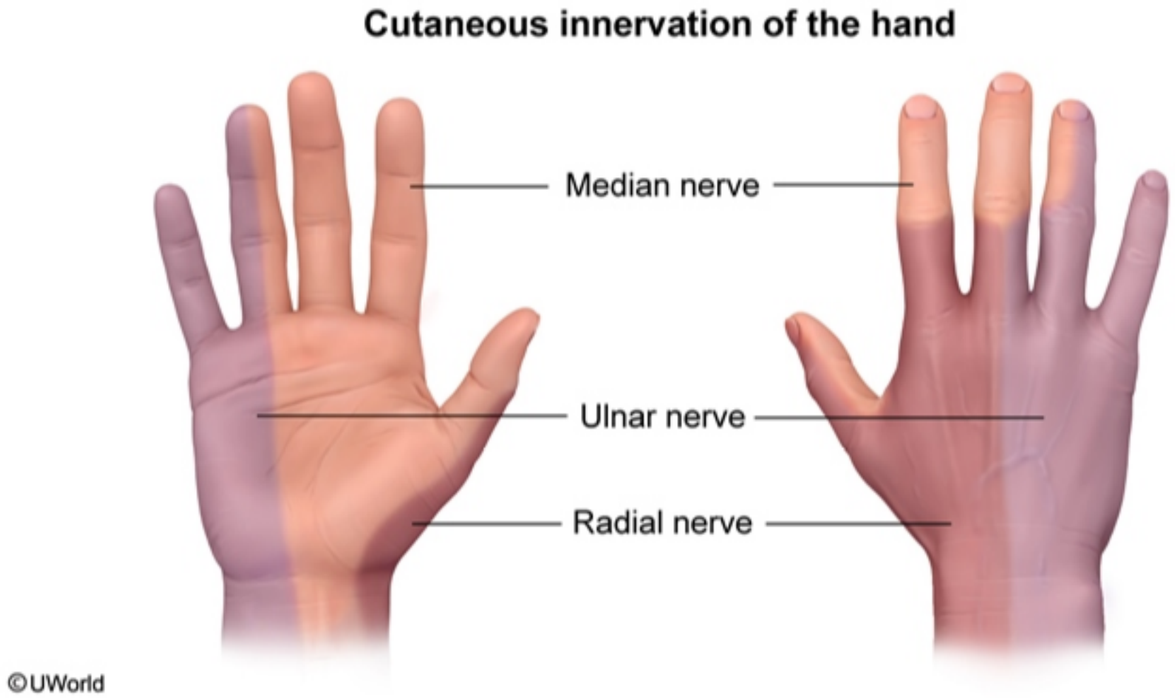

Zoom In | Zoom Out | Reset | Add To New Card | Existing Card

References

©UWorld

Exhibit Display

Carpal tunnel, palmar view

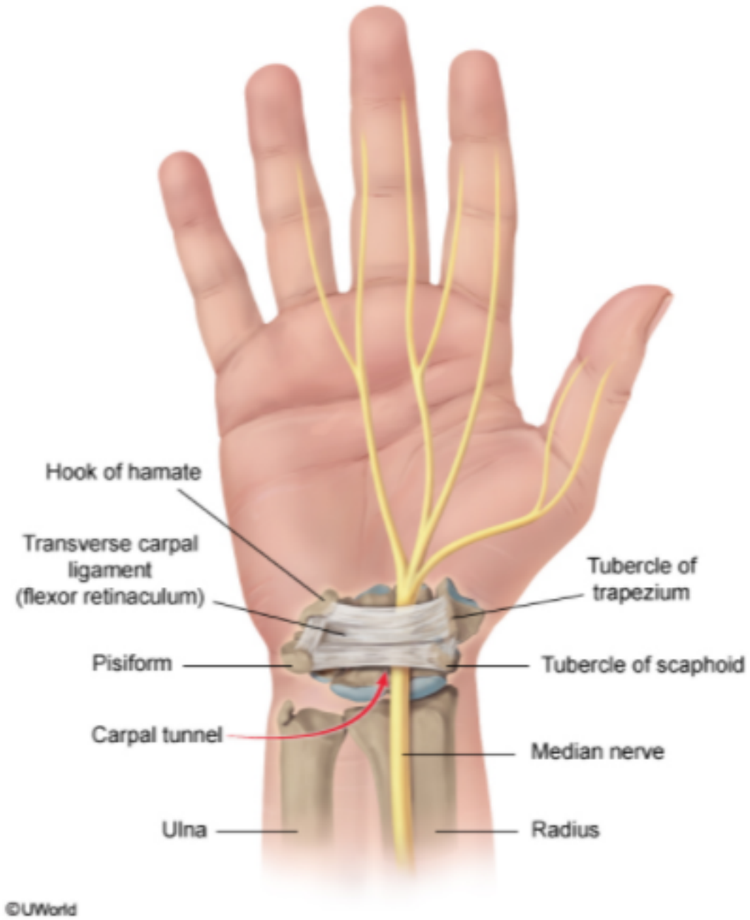

Zoom In | Zoom Out | Reset | Add To New Card | Existing Card

References

©UWorld

Exhibit Display

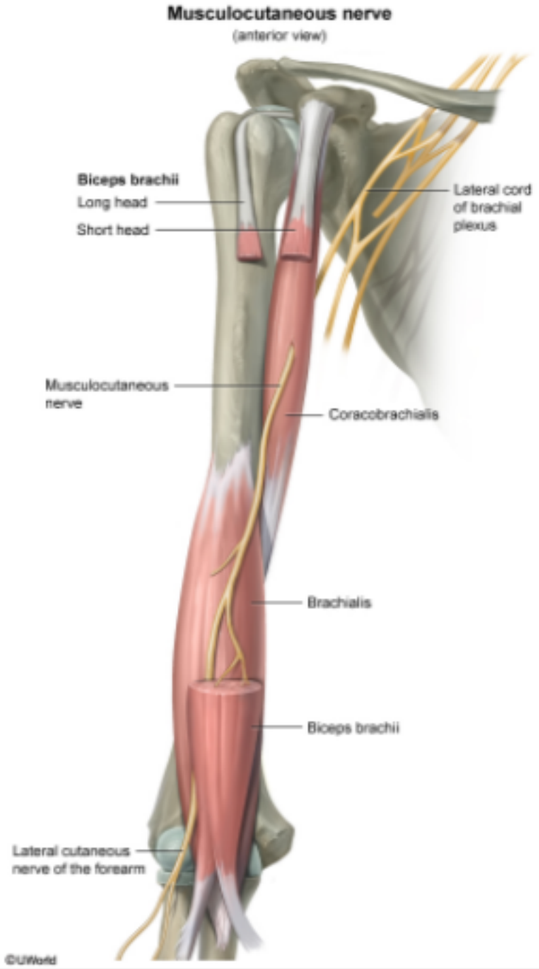

Zoom In | Zoom Out | Reset | Add To New Card | Existing Card

References

©UWorld

Exhibit Display

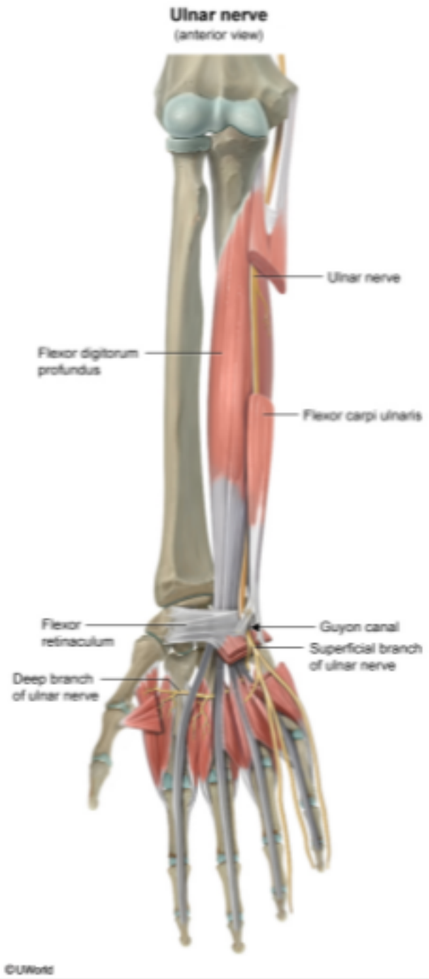

Zoom In | Zoom Out | Reset | Add To New Card | Existing Card

References

©UWorld

Exhibit Display

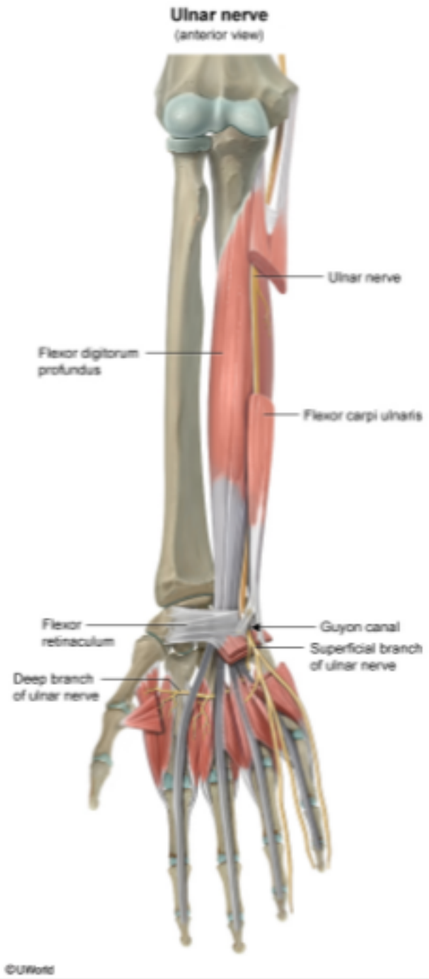

Zoom In | Zoom Out | Reset | Add To New Card | Existing Card

References

10
11
12
13
14
15
16
17
18
19
20
21
22
23
24
25
26
27
28
29
30
31
32
33
34
35
36
37
38
39
40

©UWorld

Exhibit Display

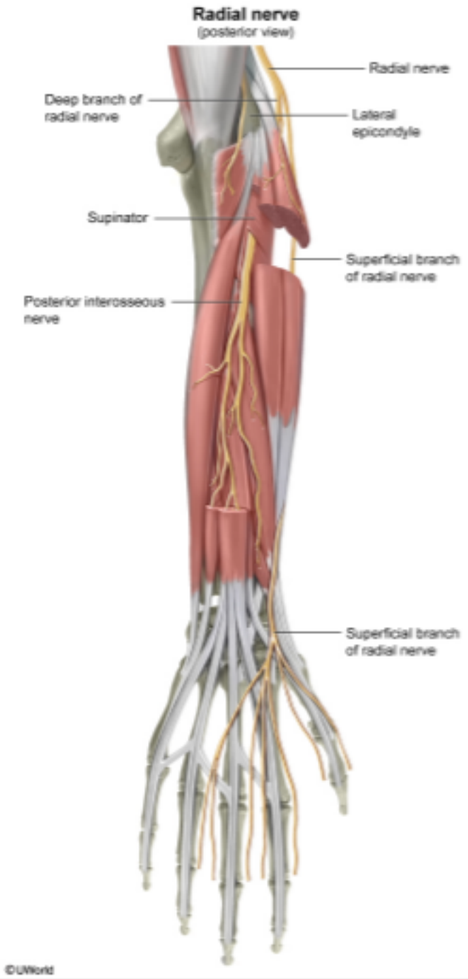

Zoom In | Zoom Out | Reset | Add To New Card | Existing Card

References

A 64-year-old smoker is evaluated for nagging right shoulder pain that radiates to the ipsilateral arm. The patient also has weakness in the right upper extremity. His symptoms started 2 months ago and have worsened progressively. On neurologic examination, the patient is awake, alert, oriented, and follows commands. He has partial right-sided ptosis with fully intact extraocular movements. His pupils are asymmetric in dim light with 2 mm on the right and 4 mm on the left, but both are reactive to light. The pupils become more symmetric in bright light. The right upper extremity has 3/5 strength and absent deep tendon reflexes. This patient's autonomic dysfunction is most likely a result of a lesion involving which of the following?

A. Autonomic ganglia
B. Brainstem
C. Cerebral cortex
D. Spinal cord
E. Subcortical grey matter
F. Vagus nerve

Submit

A 64-year-old smoker is evaluated for nagging right shoulder pain that radiates to the ipsilateral arm. The patient also has weakness in the right upper extremity. His symptoms started 2 months ago and have worsened progressively. On neurologic examination, the patient is awake, alert, oriented, and follows commands. He has partial right-sided ptosis with fully intact extraocular movements. His pupils are asymmetric in dim light with 2 mm on the right and 4 mm on the left, but both are reactive to light. The pupils become more symmetric in bright light. The right upper extremity has 3/5 strength and absent deep tendon reflexes. This patient's autonomic dysfunction is most likely a result of a lesion involving which of the following?

- ✓ A. Autonomic ganglia (51%)
- B. Brainstem (16%)
- C. Cerebral cortex (6%)
- D. Spinal cord (20%)
- E. Subcortical grey matter (3%)
- F. Vagus nerve (2%)

Omitted
Correct answer
A

51%
Answered correctly

02 secs
Time Spent

03/27/2020
Last Updated

Explanation

Ciliary ganglion

Oculomotor nerve (CN III)

Short ciliary nerves

10
11
12
13
14
15
16
17
18
19
20
21
22
23
24
25
26
27
28
29
30
31
32
33
34
35
36
37
38
39
40

Ciliary ganglion

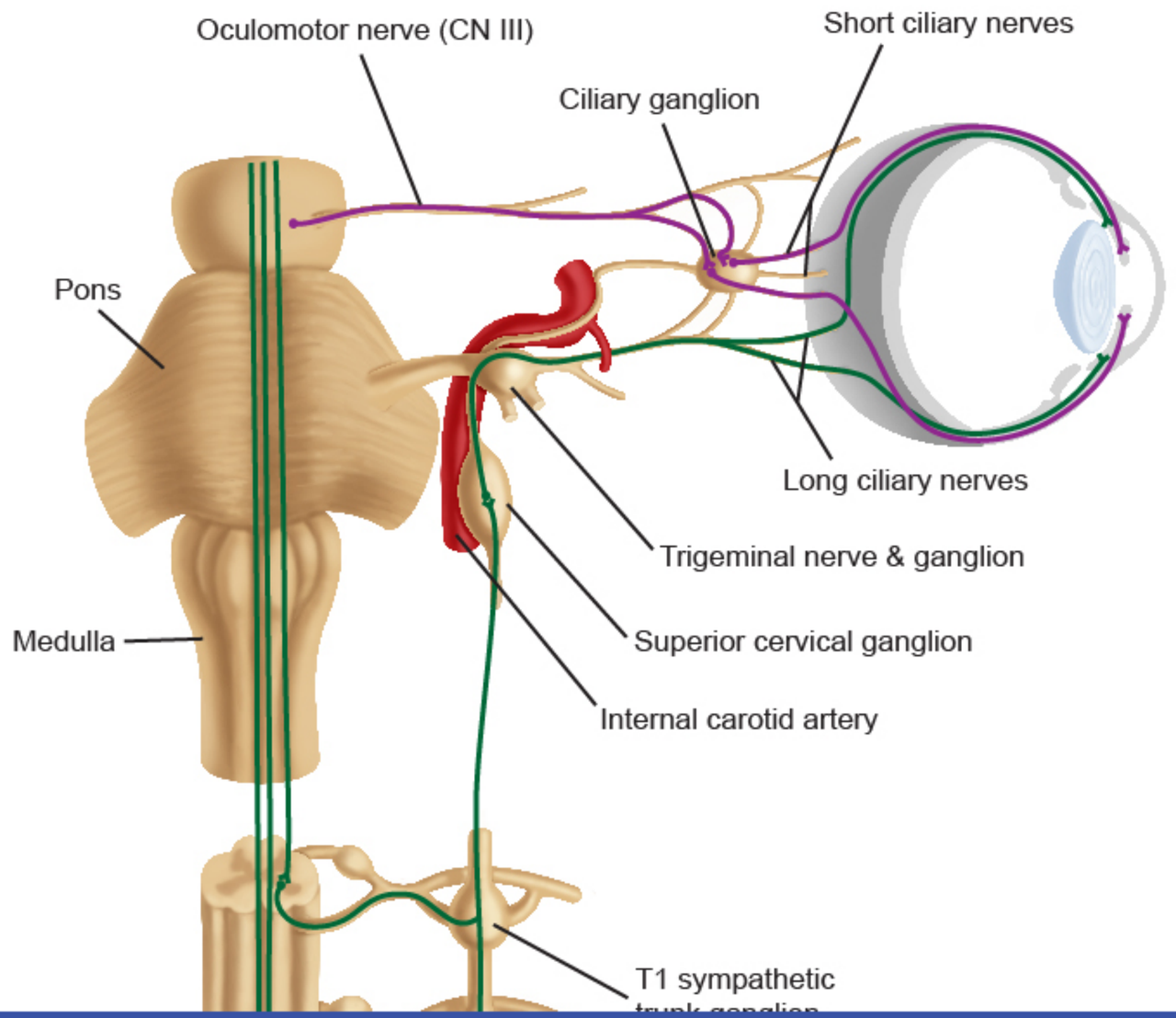

10
11
12
13
14
15
16
17
18
19
20
21
22
23
24
25
26
27
28
29
30
31
32
33
34
35
36
37
38
39
40

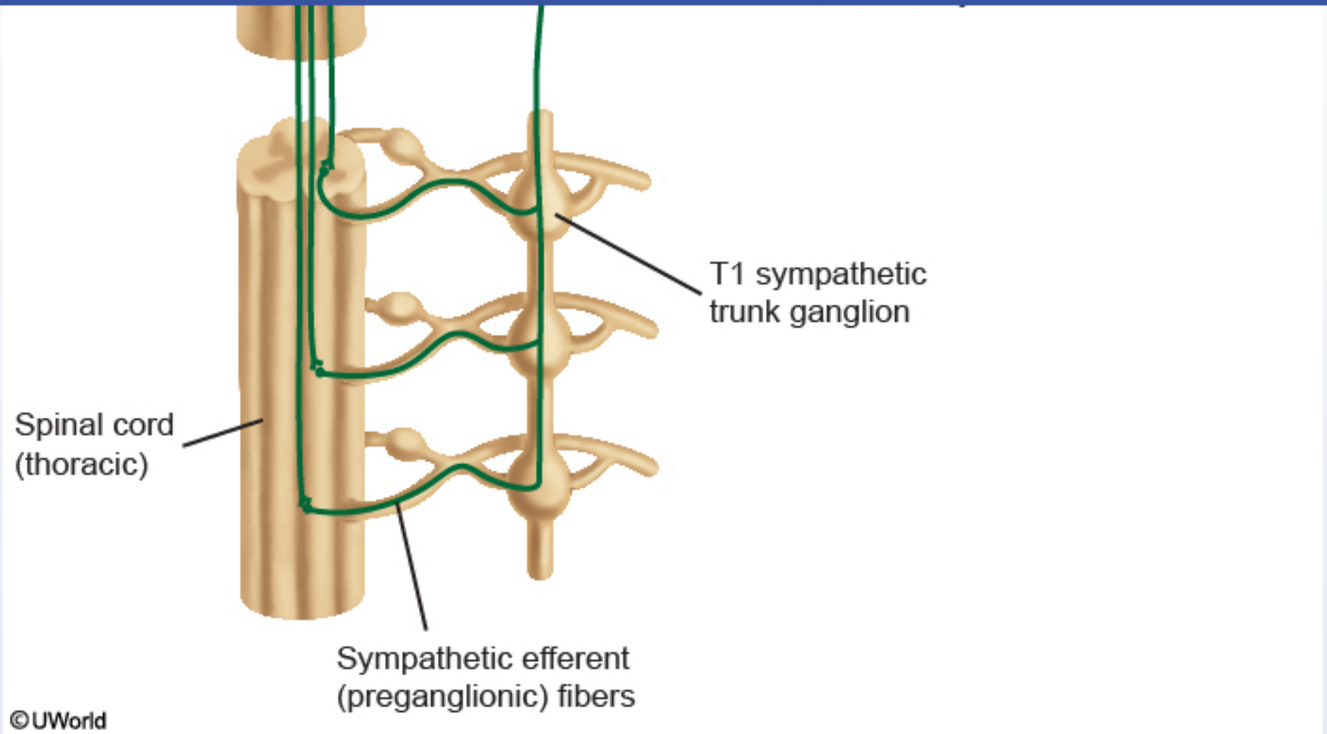

This patient's smoking history, upper limb pain/weakness, and ipsilateral ptosis and miosis are highly suggestive of a Pancoast tumor. Pancoast tumors are usually non-small cell lung cancers (eg, squamous cell carcinoma, adenocarcinoma) that arise near the superior sulcus (the groove produced by the subclavian artery). Clinical manifestations are determined by the extent of local spread. Compression and invasion of the **brachial plexus** can cause ipsilateral shoulder pain, upper limb paresthesias, and areflexic arm weakness. Involvement of the cervical sympathetic ganglia may lead to Horner's syndrome, which is characterized by ipsilateral:

1. **Partial ptosis** (drooping of upper eyelid), due to denervation of the sympathetically controlled superior tarsal muscle of the upper eyelid.
2. **Miosis** (constricted pupil), due to interruption of the sympathetic fibers to the dilator pupillae muscle, which leads to unopposed parasympathetic influence. Pupil asymmetry is more prominent when examined in dim light due to increased sympathetic activity exacerbating the defect.
3. **Anhidrosis** (impaired sweating), due to loss of sympathetic innervation of the facial sweat glands.

(preganglionic) fibers

©UWorld

This patient's smoking history, upper limb pain/weakness, and ipsilateral ptosis and miosis are highly suggestive of a Pancoast tumor. Pancoast tumors are usually non-small cell lung cancers (eg, squamous cell carcinoma, adenocarcinoma) that arise near the superior sulcus (the groove produced by the subclavian artery). Clinical manifestations are determined by the extent of local spread. Compression and invasion of the **brachial plexus** can cause ipsilateral shoulder pain, upper limb paresthesias, and areflexic arm weakness. Involvement of the cervical sympathetic ganglia may lead to Horner's syndrome, which is characterized by ipsilateral:

1. **Partial ptosis** (drooping of upper eyelid), due to denervation of the sympathetically controlled superior tarsal muscle of the upper eyelid.
2. **Miosis** (constricted pupil), due to interruption of the sympathetic fibers to the dilator pupillae muscle, which leads to unopposed parasympathetic influence. Pupil asymmetry is more prominent when examined in dim light due to increased sympathetic activity exacerbating the defect.
3. **Anhidrosis** (impaired sweating), due to loss of sympathetic innervation of the facial sweat glands.

Horner's syndrome can result from disruption at any point along the sympathetic pathway to the eye. First order sympathetic neurons are located in the hypothalamus. Their axons descend through the brainstem to the C8-T2 segments of the spinal cord (ciliospinal center of Budge), where they synapse on second order neurons found in the intermediolateral cell column. Second order axons exit the spinal cord through the anterior nerve roots and white communicating rami to reach third order neurons located in the superior cervical ganglion. From here, postganglionic fibers travel along the carotid arteries to reach target tissues in the face and head.

(Choices B and D) Both brainstem and spinal cord lesions can cause Horner's syndrome, but this patient's unilateral arm pain and weakness are more suggestive of a lesion affecting the brachial plexus/sympathetic ganglia. Brain stem lesions typically result in crossed signs (eg, contralateral hemiparesis or sensory loss) with cranial nerve abnormalities, diplopia, vertigo, and ataxia. Spinal cord lesions can result in ipsilateral spastic hemiparesis and sensory loss below the level of spinal involvement.

(Choices C and E) Damage to the cerebral cortex and basal ganglia is not associated with Horner's syndrome.

(Choice F) A vagus nerve (cranial nerve X) lesion may cause ipsilateral paralysis of the soft palate, pharynx, and larynx, producing hoarseness, dysarthria, dysphagia, and loss of the gag reflex (efferent limb). On examination, the uvula will be deviated away from the side of the lesion due to weakness of the levator veli palatini.

Educational objective:

(preganglionic) fibers

©UWorld

Exhibit Display

Zoom In | Zoom Out | Reset | Add To New Card | Existing Card

Educational objective:

10
11
12
13
14
15
16
17
18
19
20
21
22
23
24
25
26
27
28
29
30
31
32
33
34
35
36
37
38
39
40

10
11
12
13
14
15
16
17
18
19
20
21
22
23
24
25
26
27
28
29
30
31
32
33
34
35
36
37
38
39
40

A 57-year-old man is brought to the emergency department following a generalized tonic-clonic seizure. His wife reports that he has no history of seizures. However, she says that he has been complaining of intermittent headaches, memory loss, and problems with his vision for the past 2 weeks. Brain imaging shows a solitary mass within the right temporal lobe. Which of the following visual field defects is most likely present in this patient?

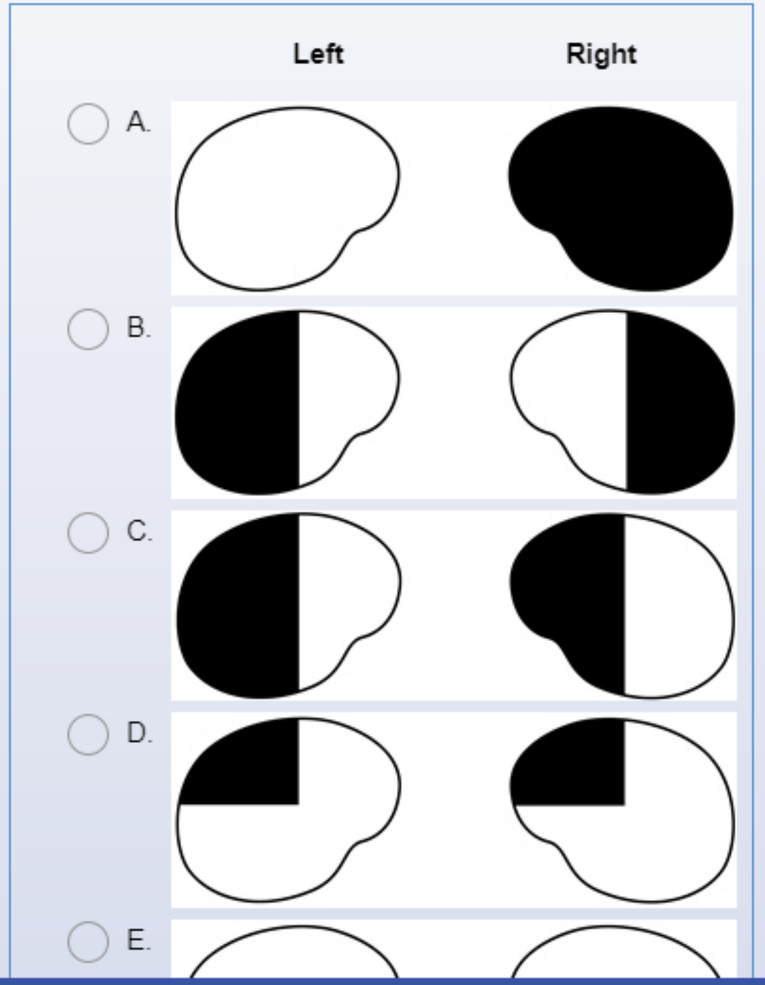

10
11
12
13
14
15
16
17
18
19
20
21
22
23
24
25
26
27
28
29
30
31
32
33
34
35
36
37
38
39
40

A.



B.

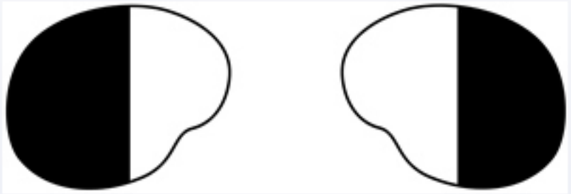

C.



D.

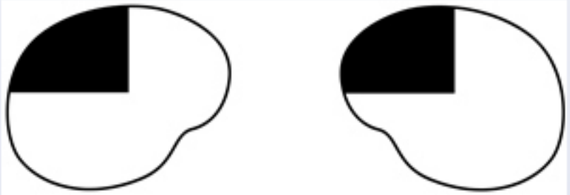

E.

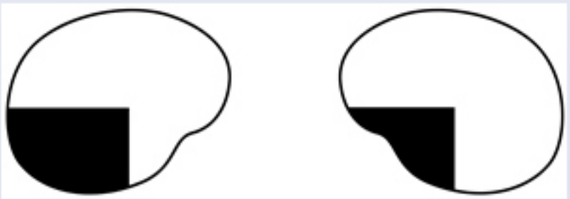

Submit

10
11
12
13
14
15
16
17
18
19
20
21
22
23
24
25
26
27
28
29
30
31
32
33
34
35
36
37
38
39
40

A.  (2%)

B. 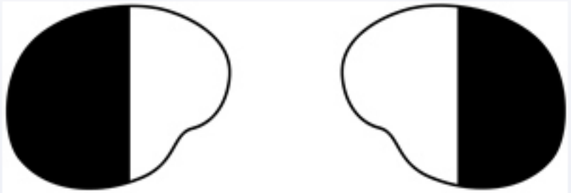 (4%)

C.  (20%)

✓ D. 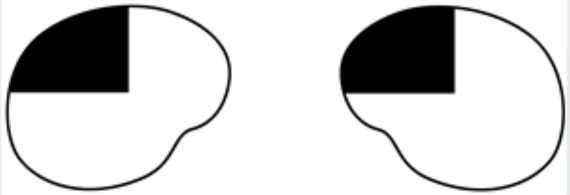 (64%)

E. 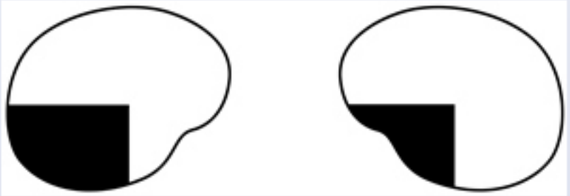 (7%)

Omitted
Correct answer

64%
Answered correctly

05 secs
Time Spent

02/28/2020
Last Updated

10
11
12
13
14
15
16
17
18
19
20
21
22
23
24
25
26
27
28
29
30
31
32
33
34
35
36
37
38
39
40

Visual pathways from above

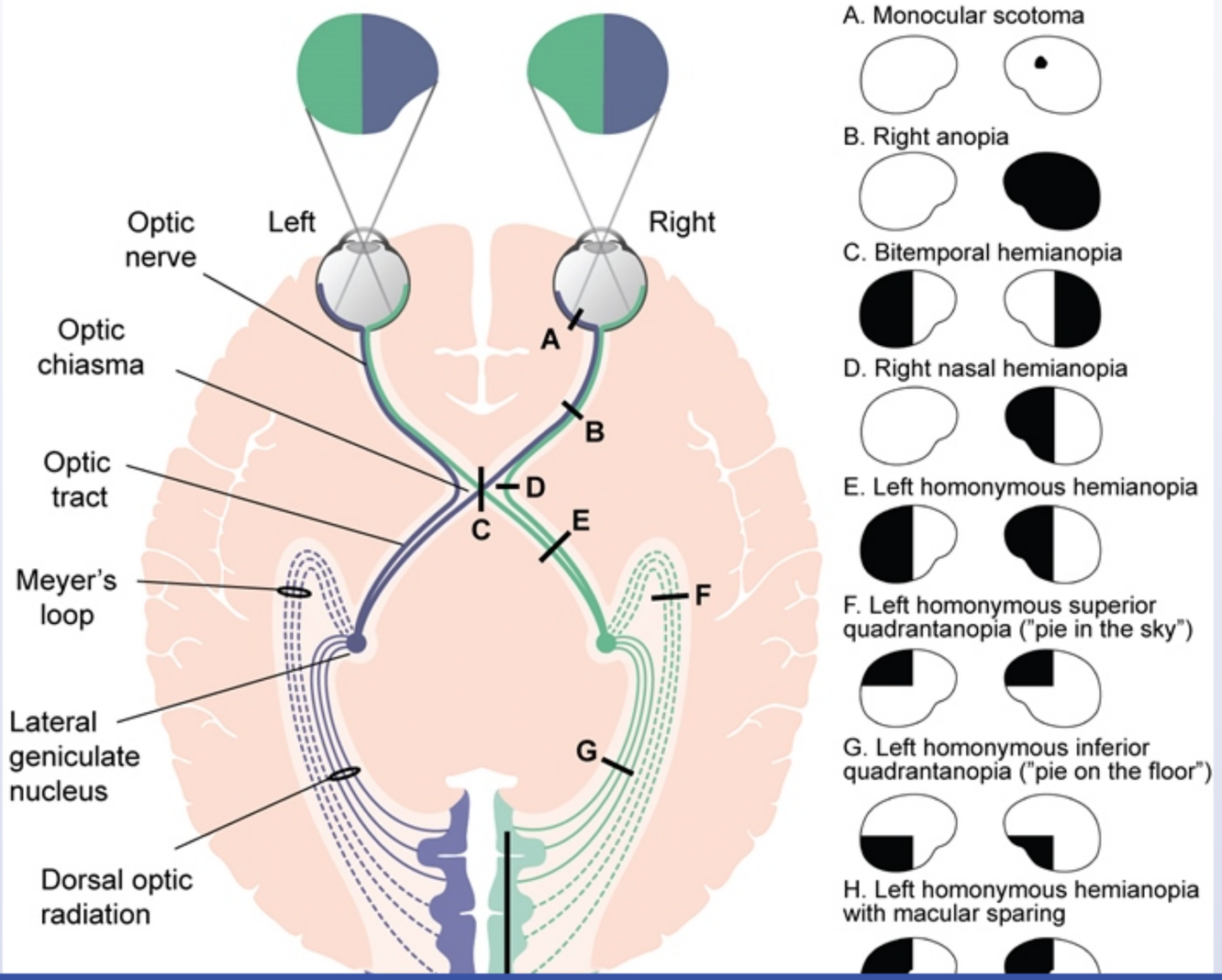

10
11
12
13
14
15
16
17
18
19
20
21
22
23
24
25
26
27
28
29
30
31
32
33
34
35
36
37
38
39
40

Visual pathways from above

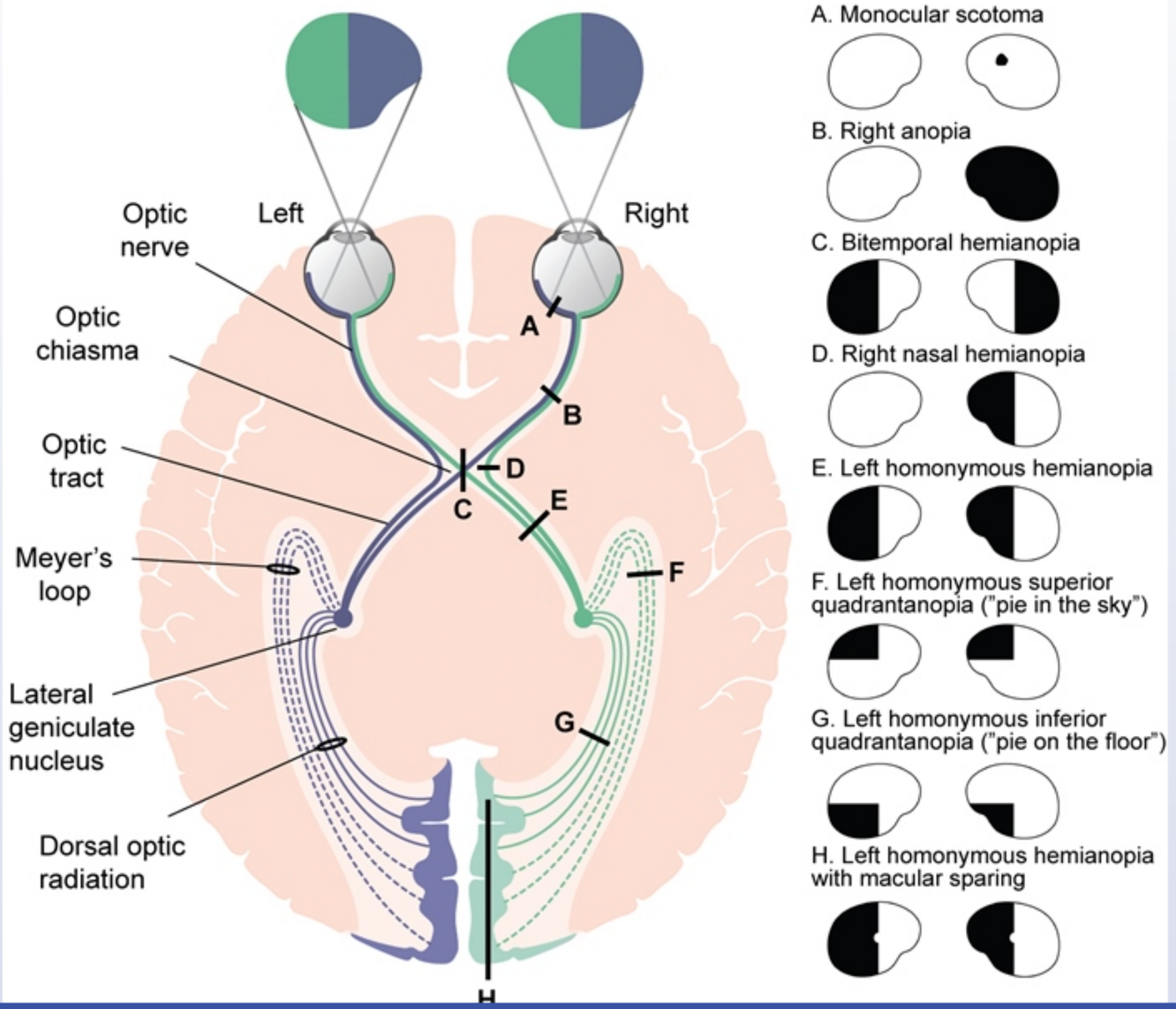

10
11
12
13
14
15
16
17
18
19
20
21
22
23
24
25
26
27
28
29
30
31
32
33
34
35
36
37
38
39
40

©UWorld

Damage to the visual pathway produces distinct types of visual field defects depending on the location of the lesion. Visual perception begins with light from the nasal visual fields striking the temporal side of each retina and light from the temporal visual fields striking the nasal side of each retina. Information from the retina is then transmitted by the optic nerves to the optic chiasm. At the optic chiasm, optic nerve fibers from the nasal half of each retina cross and project into the contralateral optic tract. In contrast, nerve fibers from the temporal parts pass into the ipsilateral optic tract. The optic tract thus contains nerve fibers from the temporal part of the ipsilateral retina and the nasal part of the contralateral retina. Optic tract fibers project mainly to the lateral geniculate nucleus (LGN), but also project to superior colliculus (reflex gaze), pretectal area (light reflex), and the suprachiasmatic nucleus (circadian rhythms).

Axons from the LGN that project to the striate (primary visual) cortex are known as the optic radiation (or geniculocalcarine tract). The lower fibers of the optic radiation carry information from the lower retina (upper contralateral visual field) and take a circuitous route anteriorly into the temporal lobe (Meyer's loop) before reaching the lingual gyrus of the striate cortex. The upper fibers of the optic radiation carry information from the upper retina (lower contralateral visual field) and pass more directly from the LGN through the parietal lobe to reach the cuneus gyrus of the striate cortex.

Lesions in the temporal lobe can disrupt Meyer's loop and produce a contralateral superior quadrantanopia. Temporal lobe lesions can also produce other neurologic manifestations, including aphasia (dominant hemisphere lesions), memory deficits, seizures (complex partial and tonic-clonic), and hallucinations (auditory, olfactory, and visual).

Educational objective:
Injury to Meyer's loop in the temporal lobe results in contralateral superior quadrantanopia.

Anatomy	Nervous System	Visual pathway
Subject	System	Topic

Copyright © UWorld. All rights reserved.

10
11
12
13
14
15
16
17
18
19
20
21
22
23
24
25
26
27
28
29
30
31
32
33
34
35
36
37
38
39
40

A 65-year-old man comes to the emergency department due to acute-onset slurred speech. He also has right-sided weakness but denies any trauma, headache, or loss of consciousness. His medical problems include hypertension and type 2 diabetes mellitus. The patient has smoked 1 pack of cigarettes daily for 20 years. Neurologic examination shows right-sided lower facial droop with sparing of the forehead muscles. Motor strength is 3/5 on the right and 5/5 on the left with a Babinski response on the right. There is also dysmetria and dysdiadochokinesia involving his right upper and lower extremities. MRI of the brain reveals an acute lacunar infarct in the brainstem, as shown in the image below.

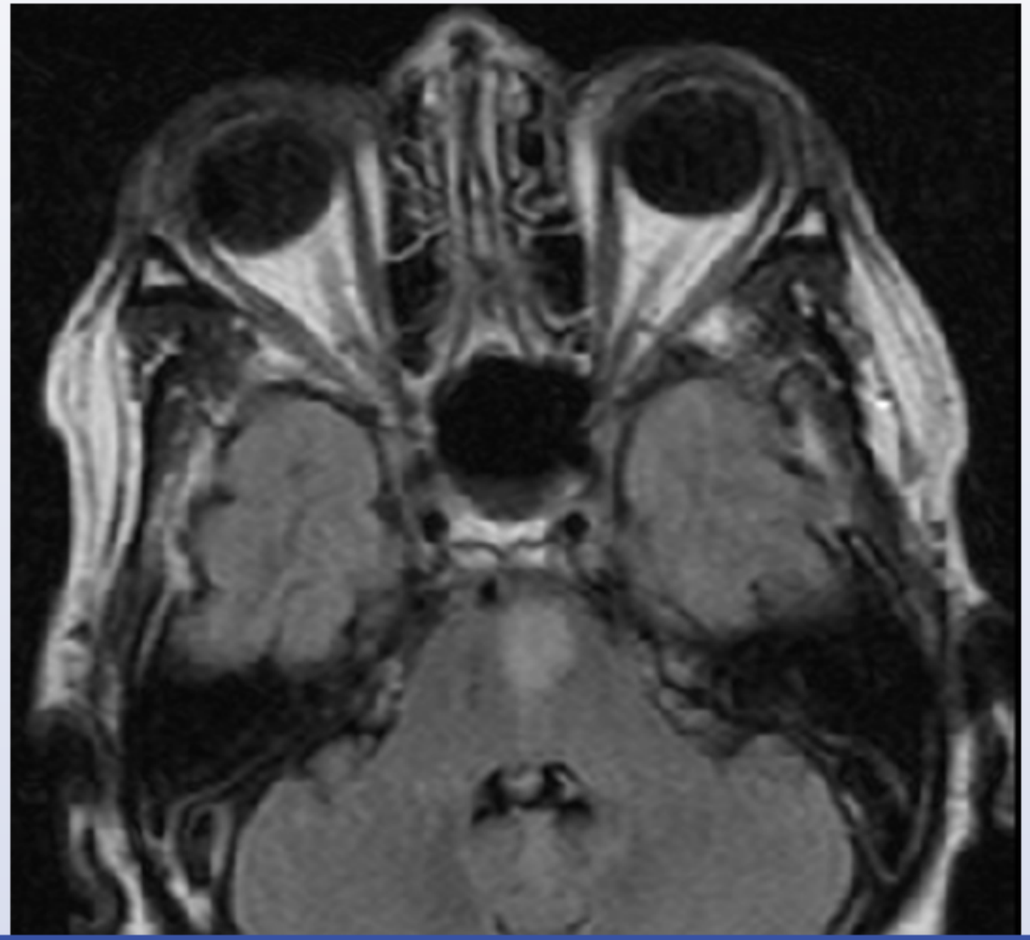

10
11
12
13
14
15
16
17
18
19
20
21
22
23
24
25
26
27
28
29
30
31
32
33
34
35
36
37
38
39
40

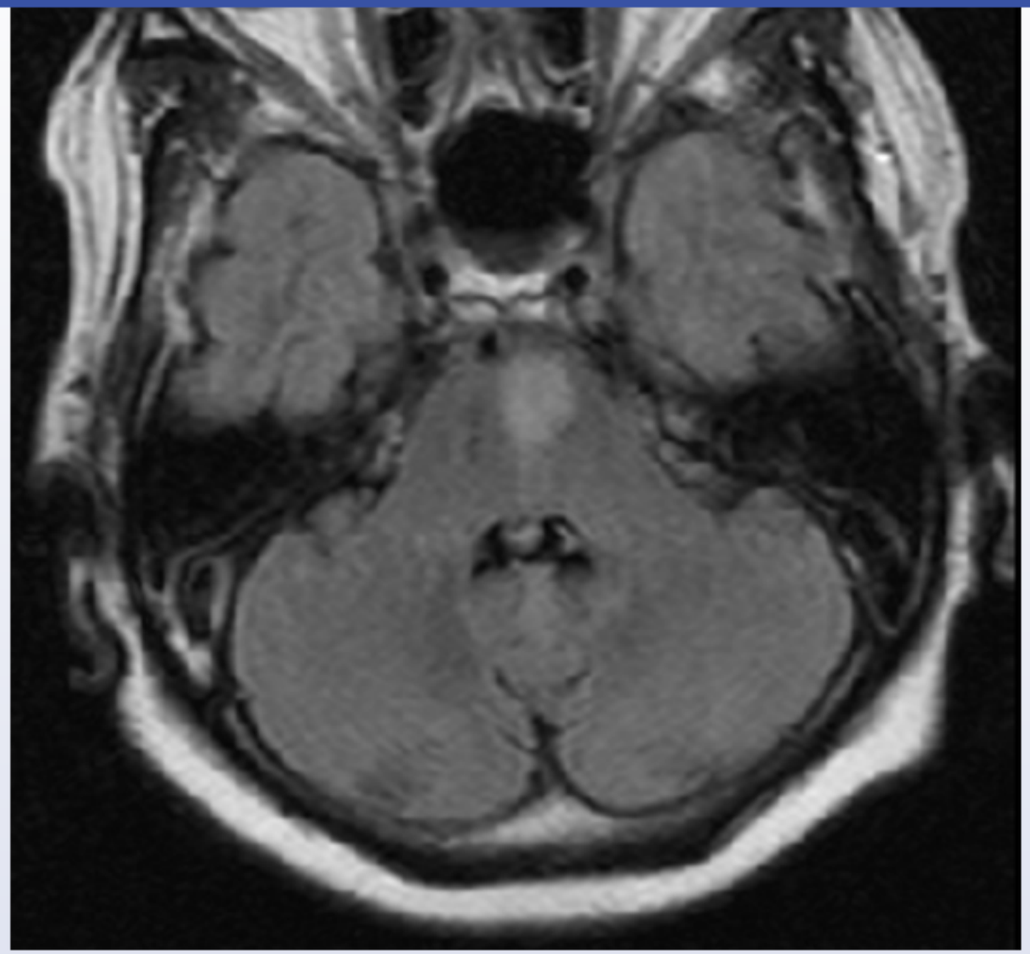

Which of the following cranial nerves exits the brainstem closest to the level affected by this patient's stroke?

A. Facial

B. Hypoglossal

C. Oculomotor

10
11
12
13
14
15
16
17
18
19
20
21
22
23
24
25
26
27
28
29
30
31
32
33
34
35
36
37
38
39
40

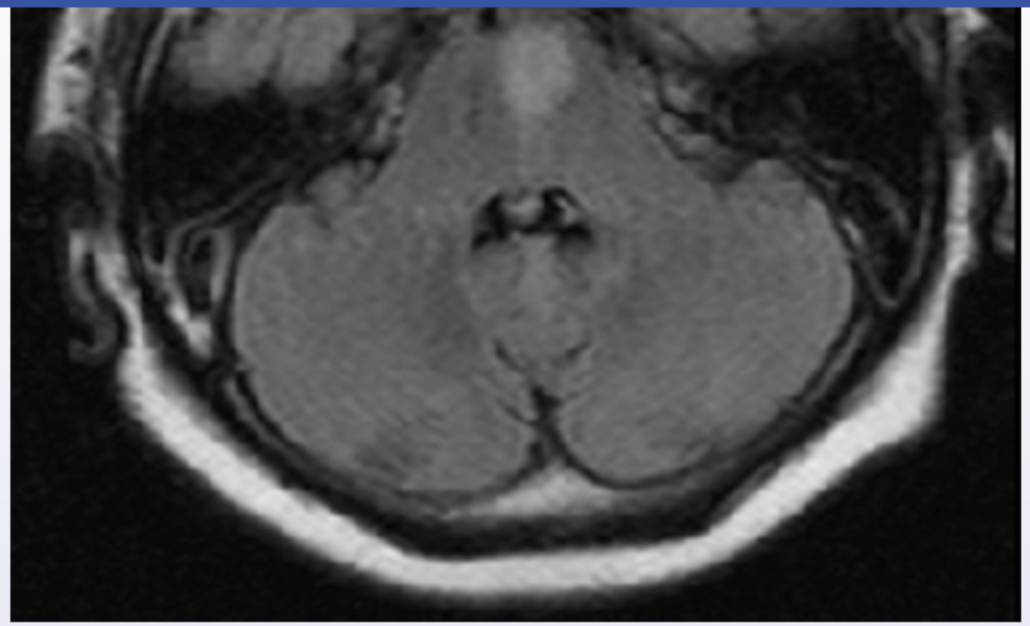

Which of the following cranial nerves exits the brainstem closest to the level affected by this patient's stroke?

A. Facial

B. Hypoglossal

C. Oculomotor

D. Trigeminal

E. Trochlear

Submit

10
11
12
13
14
15
16
17
18
19
20
21
22
23
24
25
26
27
28
29
30
31
32
33
34
35
36
37
38
39
40

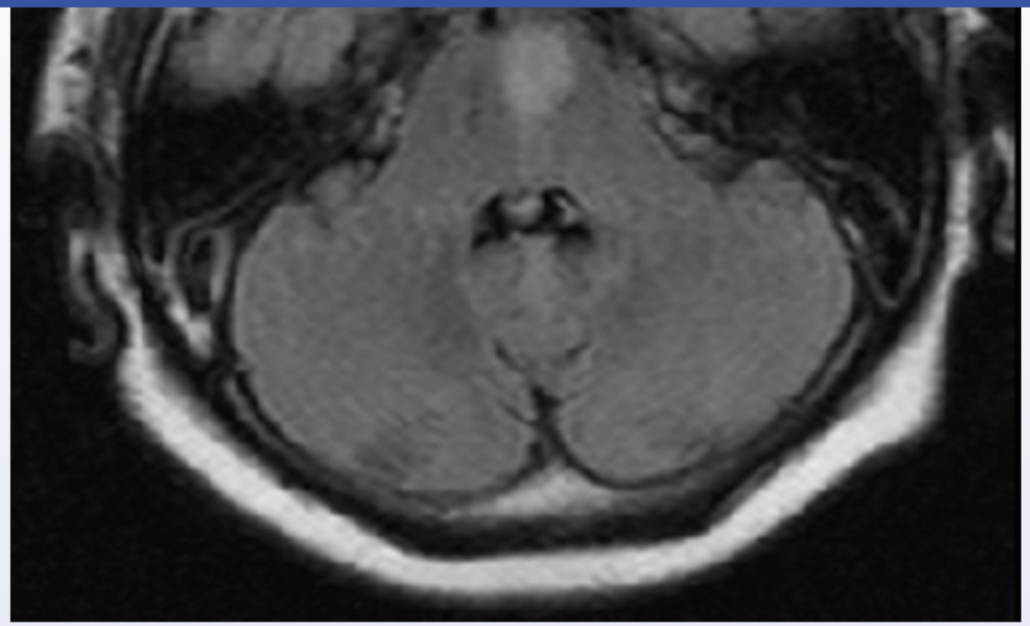

Which of the following cranial nerves exits the brainstem closest to the level affected by this patient's stroke?

A. Facial (42%)

B. Hypoglossal (11%)

C. Oculomotor (15%)

✓ D. Trigeminal (23%)

E. Trochlear (7%)

Omitted
Correct answer

23%
Answered correctly

07 secs
Time Spent

02/22/2020
Last Updated

10
11
12
13
14
15
16
17
18
19
20
21
22
23
24
25
26
27
28
29
30
31
32
33
34
35
36
37
38
39
40

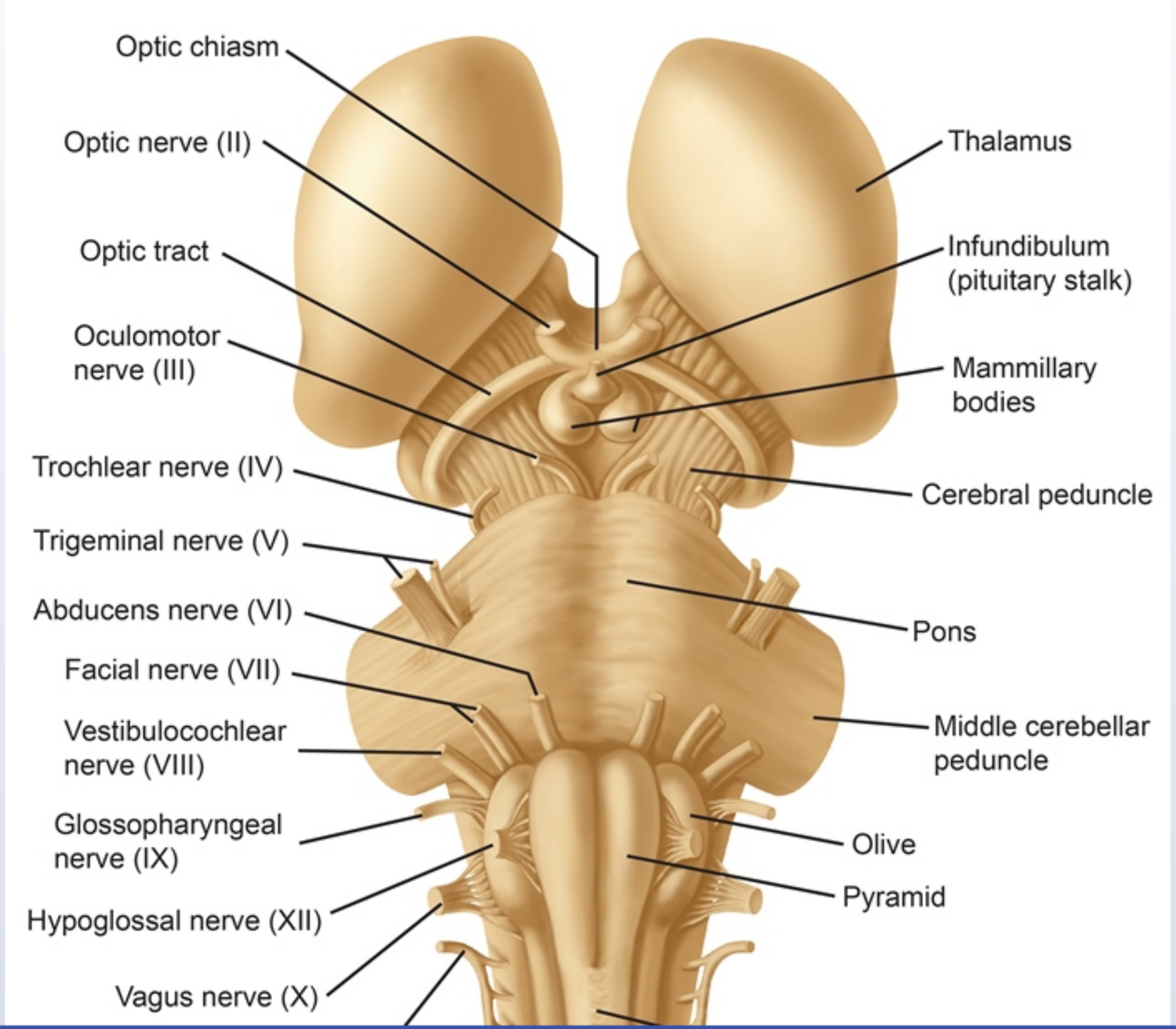

10
11
12
13
14
15
16
17
18
19
20
21
22
23
24
25
26
27
28
29
30
31
32
33
34
35
36
37
38
39
40

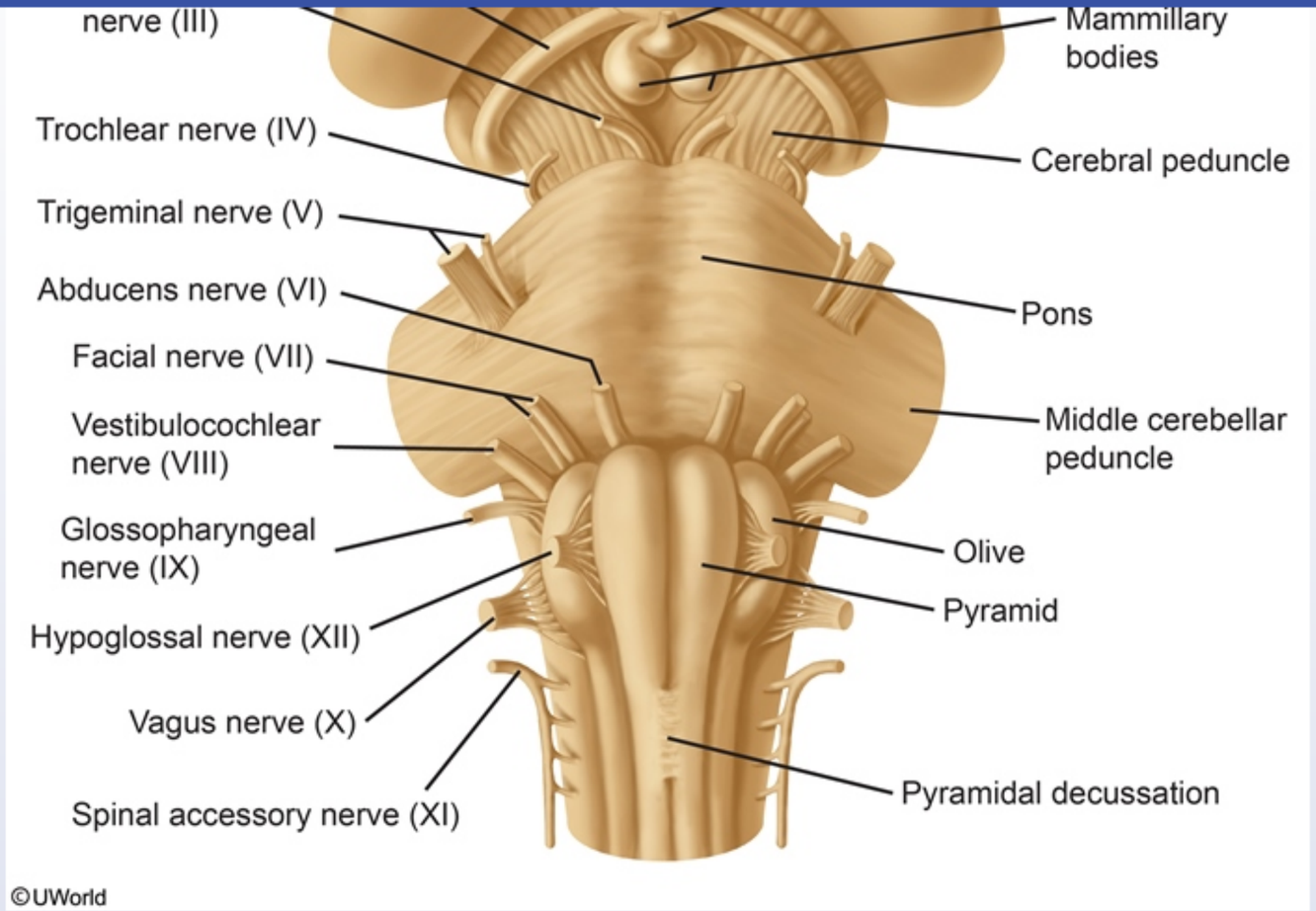

This patient has an acute lacunar ischemic stroke affecting the left medial pons at the level of the middle cerebellar peduncle. The **trigeminal nerve** (CN V) exits the brainstem at the lateral aspect of the **mid-pons** at the level of the **middle cerebellar peduncles** (a key neuroanatomic landmark for locating the nerve). The trigeminal sensory nuclei (eg, principal sensory, spinal, mesencephalic) run from the midbrain to the upper cervical spine and receive afferent signals for facial sensation via all 3 nerve branches (ophthalmic, maxillary, and mandibular). The motor nucleus is located in the lateral mid-pons and sends efferent signals to the muscles of mastication (eg, temporalis, masseter, pterygoids) via the mandibular branch.

This patient has an acute lacunar ischemic stroke affecting the left medial pons at the level of the middle cerebellar peduncle. The **trigeminal nerve** (CN V) exits the brainstem at the lateral aspect of the **mid-pons** at the level of the **middle cerebellar peduncles** (a key neuroanatomic landmark for locating the nerve). The trigeminal sensory nuclei (eg, principal sensory, spinal, mesencephalic) run from the midbrain to the upper cervical spine and receive afferent signals for facial sensation via all 3 nerve branches (ophthalmic, maxillary, and mandibular). The motor nucleus is located in the lateral mid-pons and sends efferent signals to the muscles of mastication (eg, temporalis, masseter, pterygoids) via the mandibular branch.

Infarcts involving the **anterior pons** can affect the corticospinal tract (**contralateral hemiparesis**, Babinski sign) and corticobulbar tract (contralateral **lower facial palsy**, dysarthria). Disruption of the corticopontine fibers that convey motor information from the cortex to the ipsilateral pontine gray matter may also result in contralateral dysmetria and dysdiadochokinesia (**ataxic hemiparesis**). The cerebellar deficits are contralateral to the lesion as the pontocerebellar fibers arising from the pontine gray matter decussate and enter the cerebellum through the contralateral middle cerebellar peduncle.

(Choice A) The facial nucleus is located in the dorsolateral aspect of the caudal pons, and the nerve exits at the ventrolateral pontomedullary junction (below the middle cerebellar peduncles). This patient has **sparing** of the forehead muscles, which indicates that his facial weakness is a result of a central lesion affecting the corticobulbar tract and is not due to direct damage to the facial nucleus/nerve.

(Choice B) The hypoglossal nucleus is located medially on the floor of the fourth ventricle at the level of the medulla, and the nerve exits at the rostral end of the preolivary sulcus.

(Choice C) The oculomotor nucleus is located in the rostral midbrain at the level of the superior colliculus and red nucleus, and the nerve exits at the interpeduncular fossa.

(Choice E) The trochlear nucleus is located in the caudal midbrain, and the nerve exits the dorsal midbrain just below the inferior colliculus (below the red nucleus). The trochlear nerve is the only cranial nerve to decussate before innervating its target (superior oblique muscle).

Educational objective:
Infarcts involving the anterior portion of the medial pons can produce dysarthria and contralateral hemiparesis/lower facial palsy due to disruption of the ipsilateral corticospinal and corticobulbar tracts. The trigeminal nerve arises at the level of the middle cerebellar peduncle at the lateral aspect of the mid-pons.

10
11
12
13
14
15
16
17
18
19
20
21
22
23
24
25
26
27
28
29
30
31
32
33
34
35
36
37
38
39
40

Exhibit Display

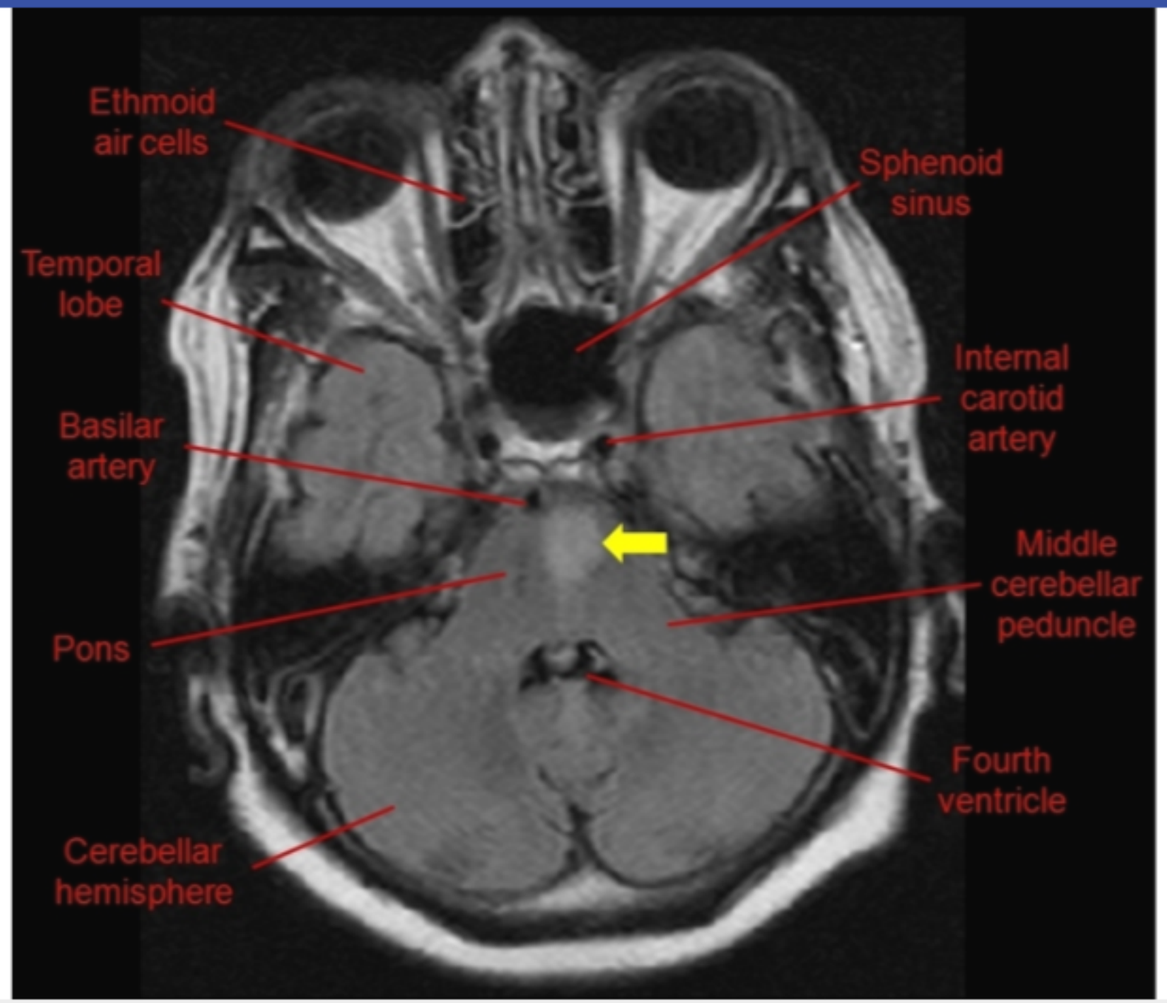

Zoom In | Zoom Out | Reset | Add To New Card | Existing Card

10
11
12
13
14
15
16
17
18
19
20
21
22
23
24
25
26
27
28
29
30
31
32
33
34
35
36
37
38
39
40

Exhibit Display

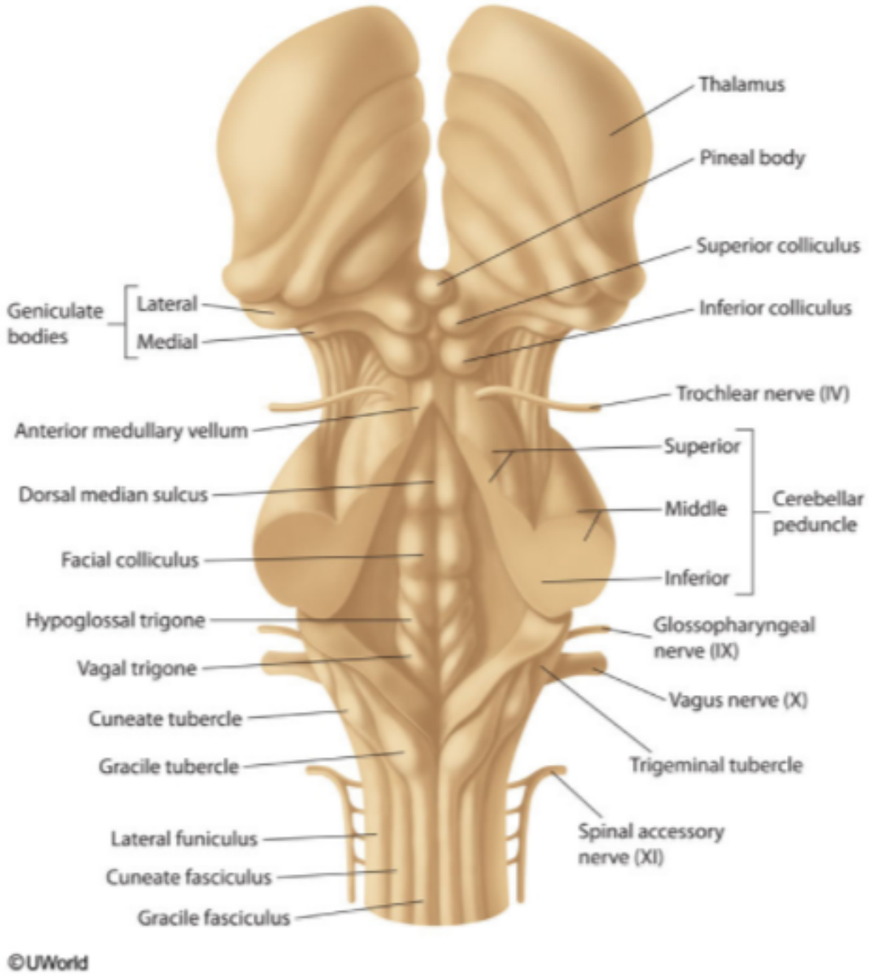

Zoom In | Zoom Out | Reset | Add To New Card | Existing Card

contralateral to the lesion as the pontocerebellar fibers arising from the pontine gray matter decussate and enter the cerebellum through the contralateral middle cerebellar peduncle.

(Choice A) The facial nucleus is located in the dorsolateral aspect of the caudal pons, and the nerve exits at the ventrolateral pontomedullary junction (below the middle cerebellar peduncles). This patient has **sparing** of the forehead muscles, which indicates that his facial weakness is a result of a central lesion affecting the corticobulbar tract and is not due to direct damage to the facial nucleus/nerve.

(Choice B) The hypoglossal nucleus is located medially on the floor of the fourth ventricle at the level of the medulla, and the nerve exits at the rostral end of the preolivary sulcus.

(Choice C) The oculomotor nucleus is located in the rostral midbrain at the level of the superior colliculus and red nucleus, and the nerve exits at the interpeduncular fossa.

(Choice E) The trochlear nucleus is located in the caudal midbrain, and the nerve exits the dorsal midbrain just below the inferior colliculus (below the red nucleus). The trochlear nerve is the only cranial nerve to decussate before innervating its target (superior oblique muscle).

Educational objective:
Infarcts involving the anterior portion of the medial pons can produce dysarthria and contralateral hemiparesis/lower facial palsy due to disruption of the ipsilateral corticospinal and corticobulbar tracts. The trigeminal nerve arises at the level of the middle cerebellar peduncle at the lateral aspect of the mid-pons.

References

- Ataxic hemiparesis: critical appraisal of a lacunar syndrome.
- The trigeminal (V) and facial (VII) cranial nerves: head and face sensation and movement.
- Cranial nerves IX, X, XI, and XII.

Anatomy	Nervous System	Trigeminal nerve
Subject	System	Topic

Copyright © UWorld. All rights reserved.

10
11
12
13
14
15
16
17
18
19
20
21
22
23
24
25
26
27
28
29
30
31
32
33
34
35
36
37
38
39
40

A 28-year-old primigravida is seen in the postpartum clinic a week after spontaneous vaginal delivery under epidural analgesia that was complicated by prolonged second-stage labor. The patient has had frequent fecal incontinence since delivery as well as mild perineal pain relieved by ibuprofen. She reports no other medical problems and that the pregnancy itself was uncomplicated. On examination, a healing perineal laceration is present and shows no signs of infection. Rectal examination reveals decreased anal sphincter tone and loss of anal wink reflex. Bilateral lower extremity reflexes are 2+ with normal tone. Which of the following is the most likely cause of her fecal incontinence?

A. Cauda equina syndrome

B. Cerebral ischemia

C. Lumbosacral plexopathy

D. Pudendal nerve injury

E. Spinal epidural hematoma

Submit

A 28-year-old primigravida is seen in the postpartum clinic a week after spontaneous vaginal delivery under epidural analgesia that was complicated by prolonged second-stage labor. The patient has had frequent fecal incontinence since delivery as well as mild perineal pain relieved by ibuprofen. She reports no other medical problems and that the pregnancy itself was uncomplicated. On examination, a healing perineal laceration is present and shows no signs of infection. Rectal examination reveals decreased anal sphincter tone and loss of anal wink reflex. Bilateral lower extremity reflexes are 2+ with normal tone. Which of the following is the most likely cause of her fecal incontinence?

- A. Cauda equina syndrome (8%)
- B. Cerebral ischemia (0%)
- C. Lumbosacral plexopathy (7%)
- ✓ D. Pudendal nerve injury (78%)
- E. Spinal epidural hematoma (4%)

Omitted
Correct answer
D

78%
Answered correctly

02 secs
Time Spent

03/31/2020
Last Updated

Explanation

The **pudendal nerve** provides motor and sensory innervation to the perineal region. It originates from the ventral rami of S2-S4 and passes between the piriformis and coccygeus muscles as it exits the pelvis through the greater sciatic foramen. It then reenters the pelvis **near the ischial spine** through the lesser sciatic foramen prior to dividing into its terminal branches. Sensory branches innervate the external genitalia as well as the skin around the anus and perineum. Motor branches innervate the pelvic floor muscles as well as the external urethral and **anal sphincters**.

Explanation

The **pudendal nerve** provides motor and sensory innervation to the perineal region. It originates from the ventral rami of S2-S4 and passes between the piriformis and coccygeus muscles as it exits the pelvis through the greater sciatic foramen. It then reenters the pelvis **near the ischial spine** through the lesser sciatic foramen prior to dividing into its terminal branches. Sensory branches innervate the external genitalia as well as the skin around the anus and perineum. Motor branches innervate the pelvic floor muscles as well as the external urethral and **anal sphincters**.

The pudendal nerve is vulnerable to **stretch injury** due to its curved course around the **ischial spine**. Active pushing during prolonged second-stage labor places excess stress on the pelvic floor, creating tension on the pudendal nerve and thereby increasing the likelihood of injury. Pudendal nerve injury may result in denervation and weakness of the voluntary perineal musculature, leading to **fecal incontinence**. Patients may also experience urinary incontinence, perineal pain, and sexual dysfunction.

(Choice A) Cauda equina syndrome is a neurosurgical emergency resulting from compression of spinal cord nerve roots below the level of the conus medullaris. Patients present with severe bilateral radicular pain, saddle anesthesia, and hyporeflexia. Bowel and bladder incontinence are late manifestations of cauda equina syndrome.

(Choice B) Cerebral ischemia results when blood flow to the brain cannot match the metabolic demand of the tissue. Thromboembolism can result in localized cerebral ischemia with focal neurologic findings, and global cerebral hypoperfusion can result in altered mental status, loss of consciousness, and coma.

(Choice C) Lumbosacral plexopathy occurs during fetal descent as a result of direct compression of the lumbosacral trunk. Patients present with foot drop and numbness of the lateral aspect of the leg and the dorsum of the foot. This condition is typically transient; most women experience resolution of symptoms within a year.

(Choice E) Epidural hematoma is a rare complication of epidural anesthesia that typically presents within hours to days following the procedure. Patients often report sudden onset of back pain or radicular pain with progression to complete or partial paralysis of the lower extremities.

Educational objective:
Stretch injury of the pudendal nerve may occur due to stress placed on the pelvic floor during labor. Pudendal nerve injury leads to weakness of the perineal musculature causing fecal and urinary incontinence, perineal pain, and sexual dysfunction.

The pudendal nerve is vulnerable to **stretch injury** due to its curved course around the **ischial spine**. Active pushing during prolonged second-stage labor places excess stress on the pelvic floor, creating tension on the pudendal nerve and thereby increasing the likelihood of injury. Pudendal nerve injury may result in denervation and weakness of the voluntary perineal musculature, leading to **fecal incontinence**. Patients may also experience urinary incontinence, perineal pain, and sexual dysfunction.

(Choice A) Cauda equina syndrome is a neurosurgical emergency resulting from compression of spinal cord nerve roots below the level of the conus medullaris. Patients present with severe bilateral radicular pain, saddle anesthesia, and hyporeflexia. Bowel and bladder incontinence are late manifestations of cauda equina syndrome.

(Choice B) Cerebral ischemia results when blood flow to the brain cannot match the metabolic demand of the tissue. Thromboembolism can result in localized cerebral ischemia with focal neurologic findings, and global cerebral hypoperfusion can result in altered mental status, loss of consciousness, and coma.

(Choice C) Lumbosacral plexopathy occurs during fetal descent as a result of direct compression of the lumbosacral trunk. Patients present with foot drop and numbness of the lateral aspect of the leg and the dorsum of the foot. This condition is typically transient; most women experience resolution of symptoms within a year.

(Choice E) Epidural hematoma is a rare complication of epidural anesthesia that typically presents within hours to days following the procedure. Patients often report sudden onset of back pain or radicular pain with progression to complete or partial paralysis of the lower extremities.

Educational objective:
Stretch injury of the pudendal nerve may occur due to stress placed on the pelvic floor during labor. Pudendal nerve injury leads to weakness of the perineal musculature causing fecal and urinary incontinence, perineal pain, and sexual dysfunction.

References

- Review of the diagnosis, management and treatment of fecal incontinence.

Anatomy	Nervous System	Fecal incontinence
Subject	System	Topic

Copyright © UWorld. All rights reserved.

10
11
12
13
14
15
16
17
18
19
20
21
22
23
24
25
26
27
28
29
30
31
32
33
34
35
36
37
38
39
40

An 18-year-old previously healthy woman is brought to the emergency department with 2 days of fever, headache, and lethargy. She has also had nausea and several episodes of vomiting. Her temperature is 38.9 C (102 F), blood pressure is 110/60 mm Hg, and pulse is 108/min. On physical examination, the patient is diaphoretic, delirious, and has a petechial rash on the trunk and extremities. Signs of meningeal irritation are present. CT scan of the head reveals no mass lesions. She is scheduled for a lumbar puncture for cerebrospinal fluid analysis. During this procedure, which of the following anatomical landmarks helps locate the optimal site for needle insertion?

A. Anterior superior iliac spine

B. Costal margin

C. Iliac crest

D. Inferior angle of the scapula

E. Posterior superior iliac spine

Submit

An 18-year-old previously healthy woman is brought to the emergency department with 2 days of fever, headache, and lethargy. She has also had nausea and several episodes of vomiting. Her temperature is 38.9 C (102 F), blood pressure is 110/60 mm Hg, and pulse is 108/min. On physical examination, the patient is diaphoretic, delirious, and has a petechial rash on the trunk and extremities. Signs of meningeal irritation are present. CT scan of the head reveals no mass lesions. She is scheduled for a lumbar puncture for cerebrospinal fluid analysis. During this procedure, which of the following anatomical landmarks helps locate the optimal site for needle insertion?

A. Anterior superior iliac spine (13%)

B. Costal margin (2%)

✓ C. Iliac crest (61%)

D. Inferior angle of the scapula (0%)

E. Posterior superior iliac spine (21%)

Omitted
Correct answer
C

61%
Answered correctly

01 sec
Time Spent

06/09/2020
Last Updated

Explanation

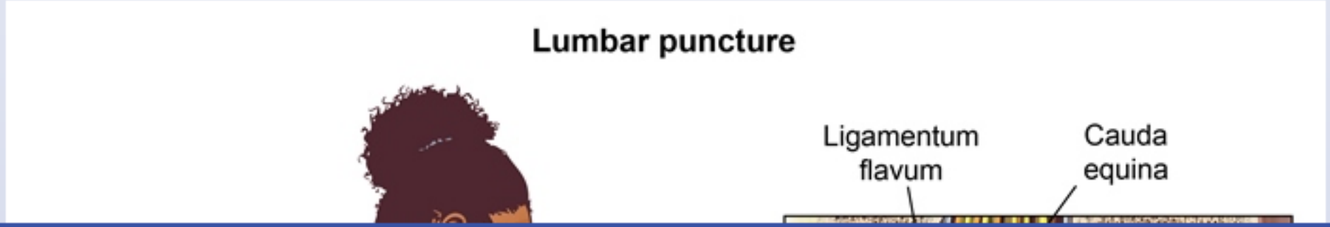

10
11
12
13
14
15
16
17
18
19
20
21
22
23
24
25
26
27
28
29
30
31
32
33
34
35
36
37
38
39
40

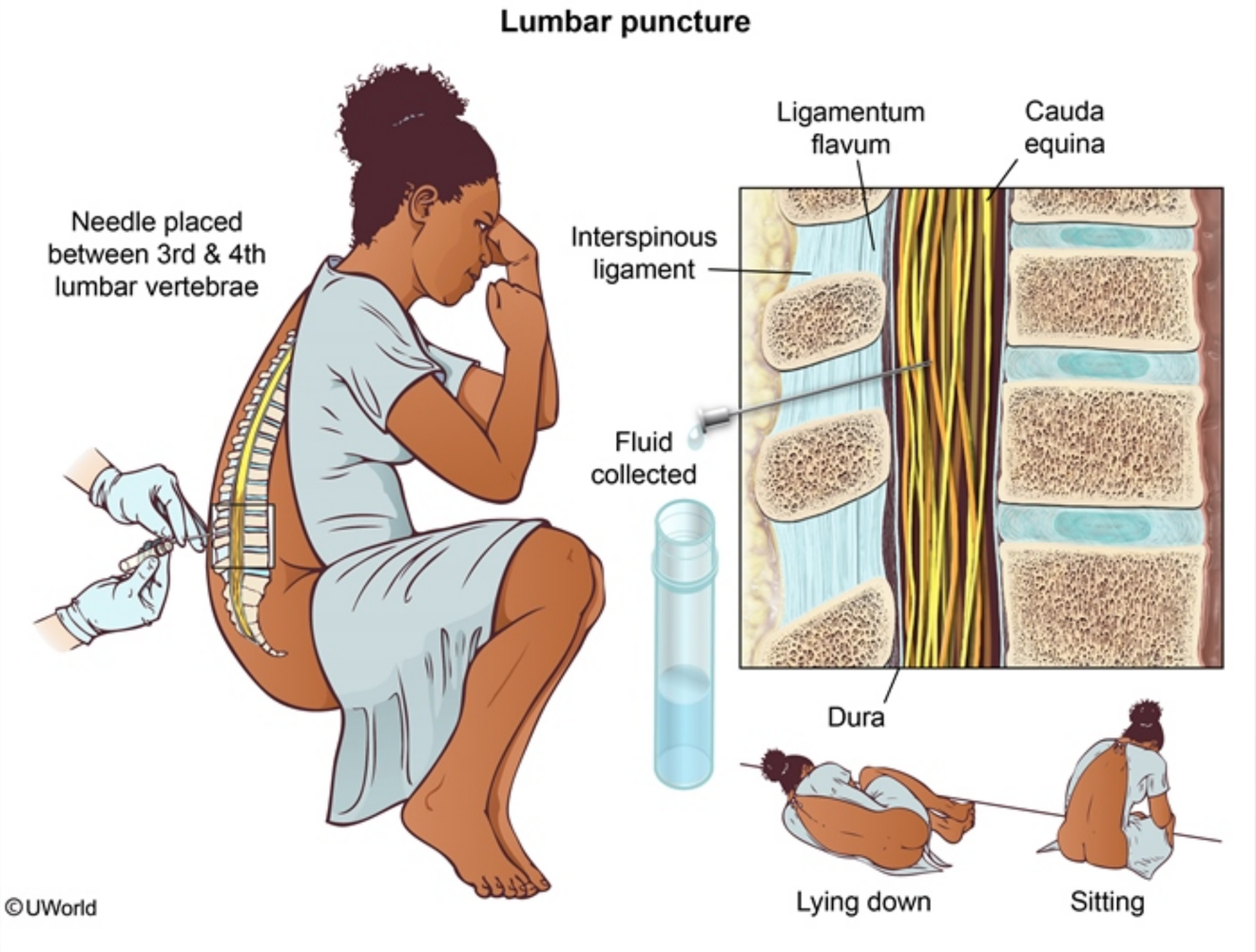

This patient with fever, headache, delirium, petechial rash, and meningismus likely has meningococcal meningitis. The diagnosis is typically confirmed with lumbar puncture and cerebrospinal fluid (CSF) analysis after neuroimaging excludes a mass lesion.

The spinal cord extends from the medulla to the inferior border of the L1 vertebra in adults (L2/L3 in neonates and infants). The conus medullaris

This patient with fever, headache, delirium, petechial rash, and meningismus likely has meningococcal meningitis. The diagnosis is typically confirmed with lumbar puncture and cerebrospinal fluid (CSF) analysis after neuroimaging excludes a mass lesion.

The spinal cord extends from the medulla to the inferior border of the L1 vertebra in adults (L2/L3 in neonates and infants). The conus medullaris is the tapered lower part of the spinal cord, which subsequently branches out into spinal nerves forming the cauda equina. The pia mater surrounding the spinal cord projects downward to form the filum terminale, which is a filament connecting the conus medullaris to the posterior coccyx. The dura extends below the spinal cord termination level to form a sac containing the CSF, nerve roots, and cauda equina. The dura ends at S2 and fuses with the filum terminale to connect to the coccyx.

Lumbar puncture is performed with the patient in the recumbent (preferred for accurate opening pressure measurement) or sitting position. The optimal location for needle insertion is the **L3/L4 or L4/L5 space** as this is well below the spinal cord termination site. The **L4 vertebral body** lies on a line drawn between the highest points of the iliac crests, which can be visually identified and confirmed by palpation.

(Choice A) The anterior superior iliac spine is a bony projection of the iliac bone that can be used as a landmark for surface anatomy of the abdomen. This structure serves as the attachment site for the sartorius muscle.

(Choice B) The costal margin is the lower edge of the thorax formed by the anterior ends of the 7th-10th costal cartilages.

(Choice D) The inferior angle of the scapula is formed by the medial and lateral borders of the scapula and serves as the origin of the teres major muscle. This scapular region aligns with the spinous processes of T7/T8.

(Choice E) The posterior superior iliac spine is the attachment site for the sacrotuberous and posterior sacroiliac ligaments in the iliac crest. The sacral dimples in the skin overlie the posterior superior iliac spine and correspond to the S2 vertebral level.

Educational objective:
The optimal location for needle insertion during a lumbar puncture is the L3/L4 or L4/L5 space as this is well below the spinal cord termination site (L1 in adults). The L4 vertebral body lies on a line drawn between the highest points of the iliac crests.

References

- Diagnostic lumbar puncture.

is the tapered lower part of the spinal cord, which subsequently branches out into spinal nerves forming the cauda equina. The pia mater surrounding the spinal cord projects downward to form the filum terminale, which is a filament connecting the conus medullaris to the posterior coccyx. The dura extends below the spinal cord termination level to form a sac containing the CSF, nerve roots, and cauda equina. The dura ends at S2 and fuses with the filum terminale to connect to the coccyx.

Lumbar puncture is performed with the patient in the recumbent (preferred for accurate opening pressure measurement) or sitting position. The optimal location for needle insertion is the **L3/L4 or L4/L5 space** as this is well below the spinal cord termination site. The **L4 vertebral body** lies on a line drawn between the highest points of the iliac crests, which can be visually identified and confirmed by palpation.

(Choice A) The anterior superior iliac spine is a bony projection of the iliac bone that can be used as a landmark for surface anatomy of the abdomen. This structure serves as the attachment site for the sartorius muscle.

(Choice B) The costal margin is the lower edge of the thorax formed by the anterior ends of the 7th-10th costal cartilages.

(Choice D) The inferior angle of the scapula is formed by the medial and lateral borders of the scapula and serves as the origin of the teres major muscle. This scapular region aligns with the spinous processes of T7/T8.

(Choice E) The posterior superior iliac spine is the attachment site for the sacrotuberous and posterior sacroiliac ligaments in the iliac crest. The sacral dimples in the skin overlie the posterior superior iliac spine and correspond to the S2 vertebral level.

Educational objective:
The optimal location for needle insertion during a lumbar puncture is the L3/L4 or L4/L5 space as this is well below the spinal cord termination site (L1 in adults). The L4 vertebral body lies on a line drawn between the highest points of the iliac crests.

References

- Diagnostic lumbar puncture.

Anatomy	Nervous System	Spinal anatomy
Subject	System	Topic

Copyright © UWorld. All rights reserved.

10
11
12
13
14
15
16
17
18
19
20
21
22
23
24
25
26
27
28
29
30
31
32
33
34
35
36
37
38
39
40

Exhibit Display

Sectional anatomy of spinal cord

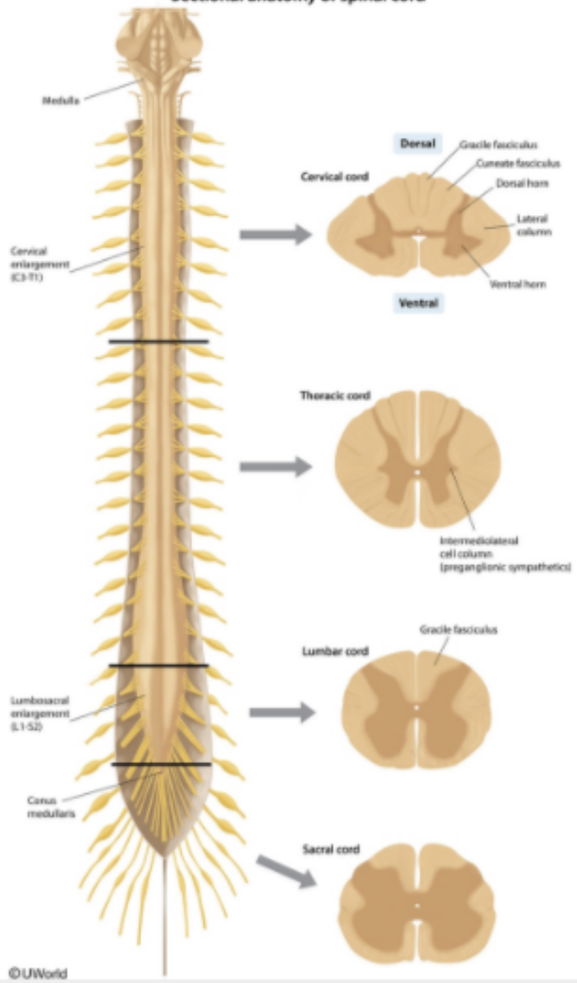

Zoom In | Zoom Out | Reset | Add To New Card | Existing Card

The optimal location for needle insertion during a lumbar puncture is the L3/L4 or L4/L5 space as this is well below the spinal cord termination site

10
11
12
13
14
15
16
17
18
19
20
21
22
23
24
25
26
27
28
29
30
31
32
33
34
35
36
37
38
39
40

Exhibit Display

Female pelvis

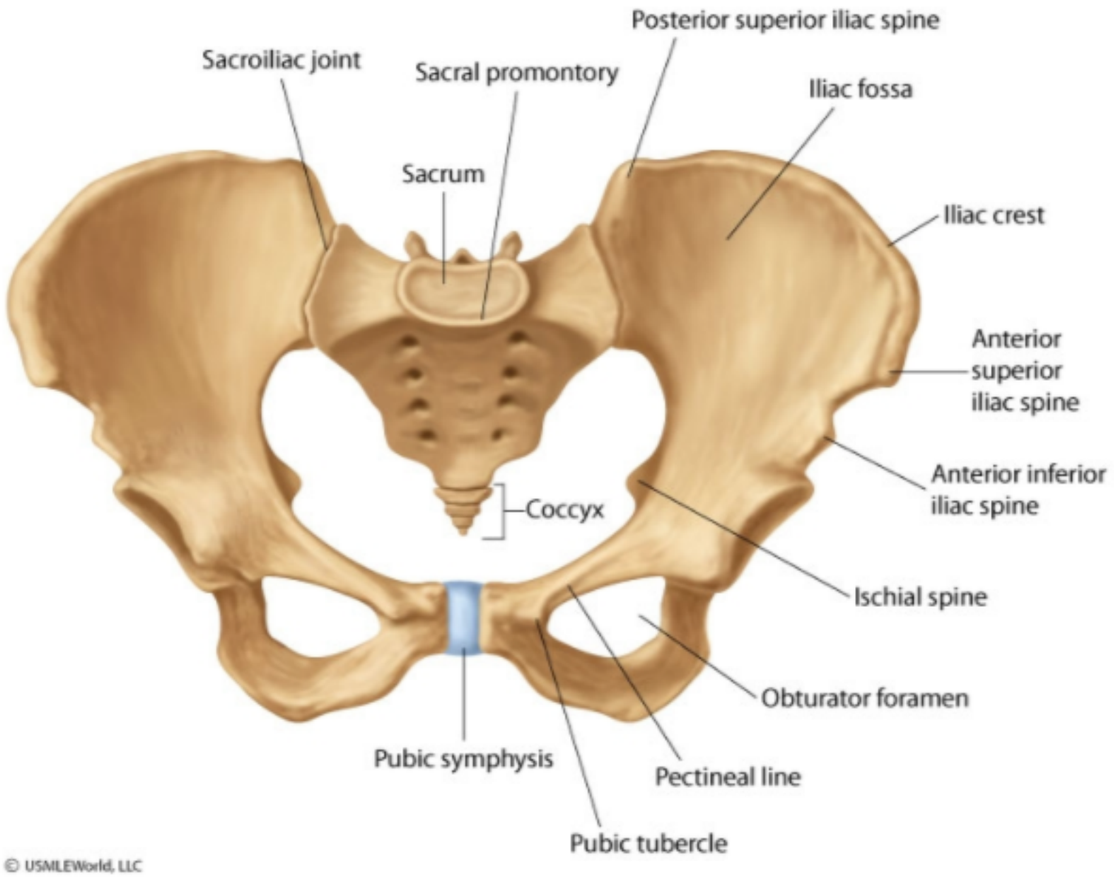

© USMLEWorld, LLC

Zoom In | Zoom Out | Reset | Add To New Card | Existing Card

The optimal location for needle insertion during a lumbar puncture is the L3/L4 or L4/L5 space as this is well below the spinal cord termination site

10
11
12
13
14
15
16
17
18
19
20
21
22
23
24
25
26
27
28
29
30
31
32
33
34
35
36
37
38
39
40

A 56-year-old woman is brought to the emergency department with sudden onset of headache and partial loss of vision. She has a 3-year history of atrial fibrillation. Physical examination shows a visual field defect involving the black areas illustrated below.

This patient most likely has occlusion of which of the following arteries?

A. Anterior cerebral
B. Central retinal
C. Middle cerebral
D. Posterior cerebral
E. Posterior inferior cerebellar

Submit

10
11
12
13
14
15
16
17
18
19
20
21
22
23
24
25
26
27
28
29
30
31
32
33
34
35
36
37
38
39
40

A 56-year-old woman is brought to the emergency department with sudden onset of headache and partial loss of vision. She has a 3-year history of atrial fibrillation. Physical examination shows a visual field defect involving the black areas illustrated below.

This patient most likely has occlusion of which of the following arteries?

A. Anterior cerebral (3%)
B. Central retinal (1%)
C. Middle cerebral (11%)
✓ D. Posterior cerebral (78%)
E. Posterior inferior cerebellar (4%)

Omitted
Correct answer
D

78%
Answered correctly

02 secs
Time Spent

01/15/2020
Last Updated

Explanation

10
11
12
13
14
15
16
17
18
19
20
21
22
23
24
25
26
27
28
29
30
31
32
33
34
35
36
37
38
39
40

Visual pathways from above

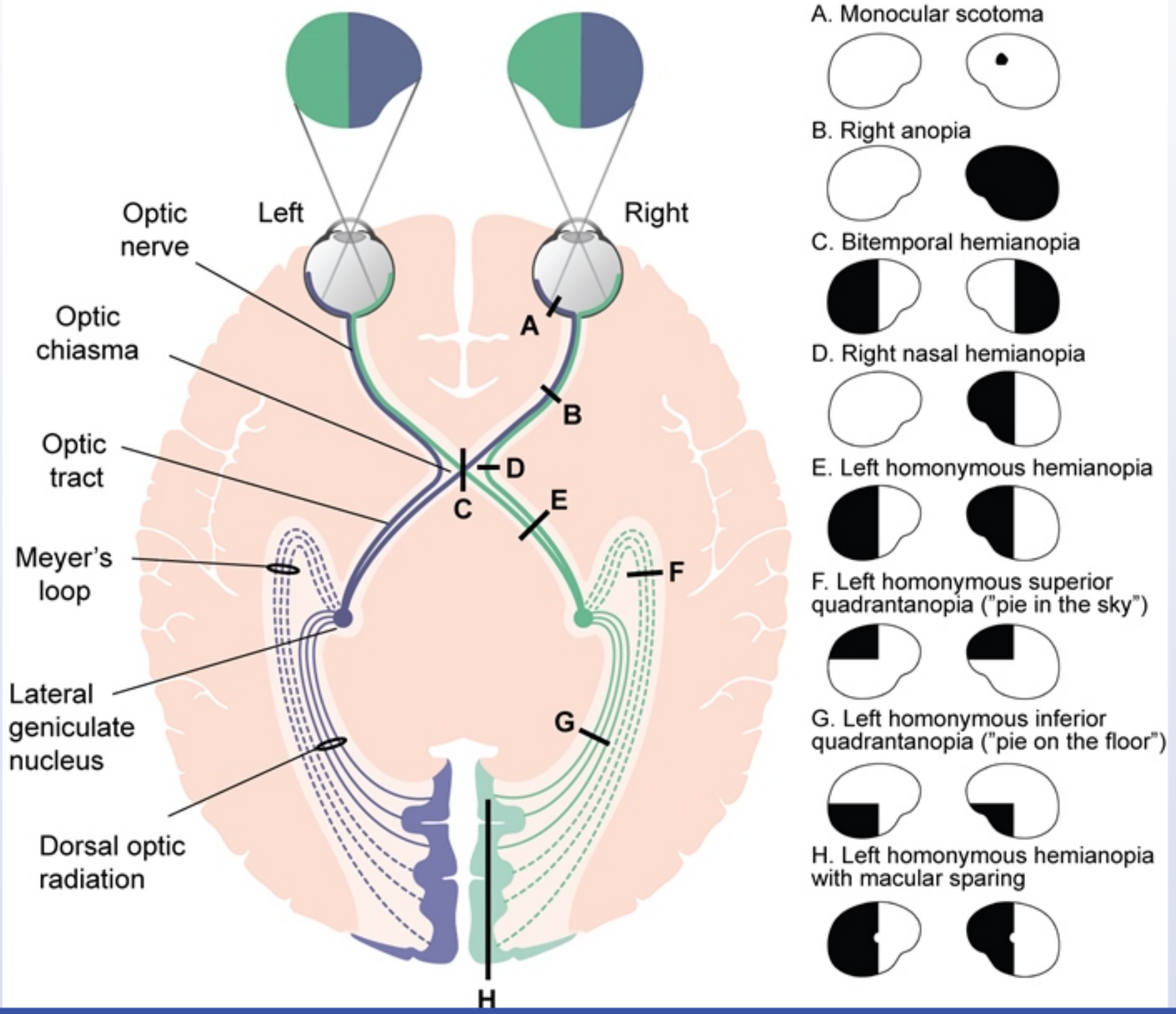

10
11
12
13
14
15
16
17
18
19
20
21
22
23
24
25
26
27
28
29
30
31
32
33
34
35
36
37
38
39
40

H

©UWorld

The described vision defect is consistent with an occlusion of the posterior cerebral artery (PCA), most likely from an embolic event given this patient's history of atrial fibrillation. The PCA supplies the occipital lobe, which contains the striate or primary visual cortex. The striate cortex of each hemisphere receives information about the contralateral visual field from the ipsilateral lateral geniculate nucleus via the optic radiation. Specifically, the cuneus gyrus of the striate cortex receives information from the upper retina (lower visual field), while the lingual gyrus of the striate cortex receives information from the lower retina (upper visual field).

Occlusion of the PCA leads to ischemic injury to the ipsilateral striate cortex, producing a contralateral homonymous hemianopia with macular sparing. The macula is spared because collateral blood is supplied by the middle cerebral artery to the occipital pole, which processes central visual information. Unilateral infarcts involving only the cuneus gyrus or the lingual gyrus will produce a lower or upper quadrantanopia, respectively.

(Choice A) Anterior cerebral artery occlusion manifests as contralateral weakness that predominantly affects the lower extremity.

(Choice B) Occlusion of the central retinal artery leads to sudden, painless, and complete loss of vision in the affected eye.

(Choice C) Middle cerebral artery stroke is characterized by contralateral motor and sensory deficits (more pronounced in the upper than lower limb) and homonymous hemianopia **with macular involvement**.

(Choice E) Occlusion of the posterior inferior cerebellar artery leads to lateral medullary (Wallenberg) syndrome. It is characterized by contralateral loss of pain and temperature sensation; ipsilateral deficits of CN V, VIII, IX, X, and XI; and Horner's syndrome.

Educational objective:
Lesions of the occipital cortex (eg, posterior cerebral artery occlusion) can produce contralateral homonymous hemianopia with macular sparing.

Anatomy	Nervous System	Visual pathway
Subject	System	Topic

Copyright © UWorld. All rights reserved.

10
11
12
13
14
15
16
17
18
19
20
21
22
23
24
25
26
27
28
29
30
31
32
33
34
35
36
37
38
39
40

A 7-year-old boy is brought to the emergency department after injuring his right knee in a bicycle accident. Physical examination shows a swollen right knee with abrasion of the overlying skin. Distal motor and sensory innervation are intact, and popliteal and pedal pulses are normal. No other significant trauma is noted. X-ray reveals a nondisplaced patellar fracture. The patient is referred to orthopedics and placed in a leg cylinder cast. On follow-up a week after cast placement, he has paresthesia and numbness of the dorsum of the right foot, as along with weakness in foot dorsiflexion and eversion. Which of the following is the most likely site of nerve compression in this patient?

A. Anterior compartment of the leg
B. Fibular neck
C. Lateral compartment of the leg
D. Medial malleolus
E. Popliteal fossa

Submit

A 7-year-old boy is brought to the emergency department after injuring his right knee in a bicycle accident. Physical examination shows a swollen right knee with abrasion of the overlying skin. Distal motor and sensory innervation are intact, and popliteal and pedal pulses are normal. No other significant trauma is noted. X-ray reveals a nondisplaced patellar fracture. The patient is referred to orthopedics and placed in a leg cylinder cast. On follow-up a week after cast placement, he has paresthesia and numbness of the dorsum of the right foot, as along with weakness in foot dorsiflexion and eversion. Which of the following is the most likely site of nerve compression in this patient?

- A. Anterior compartment of the leg (14%)
- ✓ B. Fibular neck (60%)
- C. Lateral compartment of the leg (18%)
- D. Medial malleolus (2%)
- E. Popliteal fossa (4%)

Omitted
Correct answer
B

60%
Answered correctly

03 secs
Time Spent

02/18/2020
Last Updated

Explanation

10
11
12
13
14
15
16
17
18
19
20
21
22
23
24
25
26
27
28
29
30
31
32
33
34
35
36
37
38
39
40

Sciatic nerve

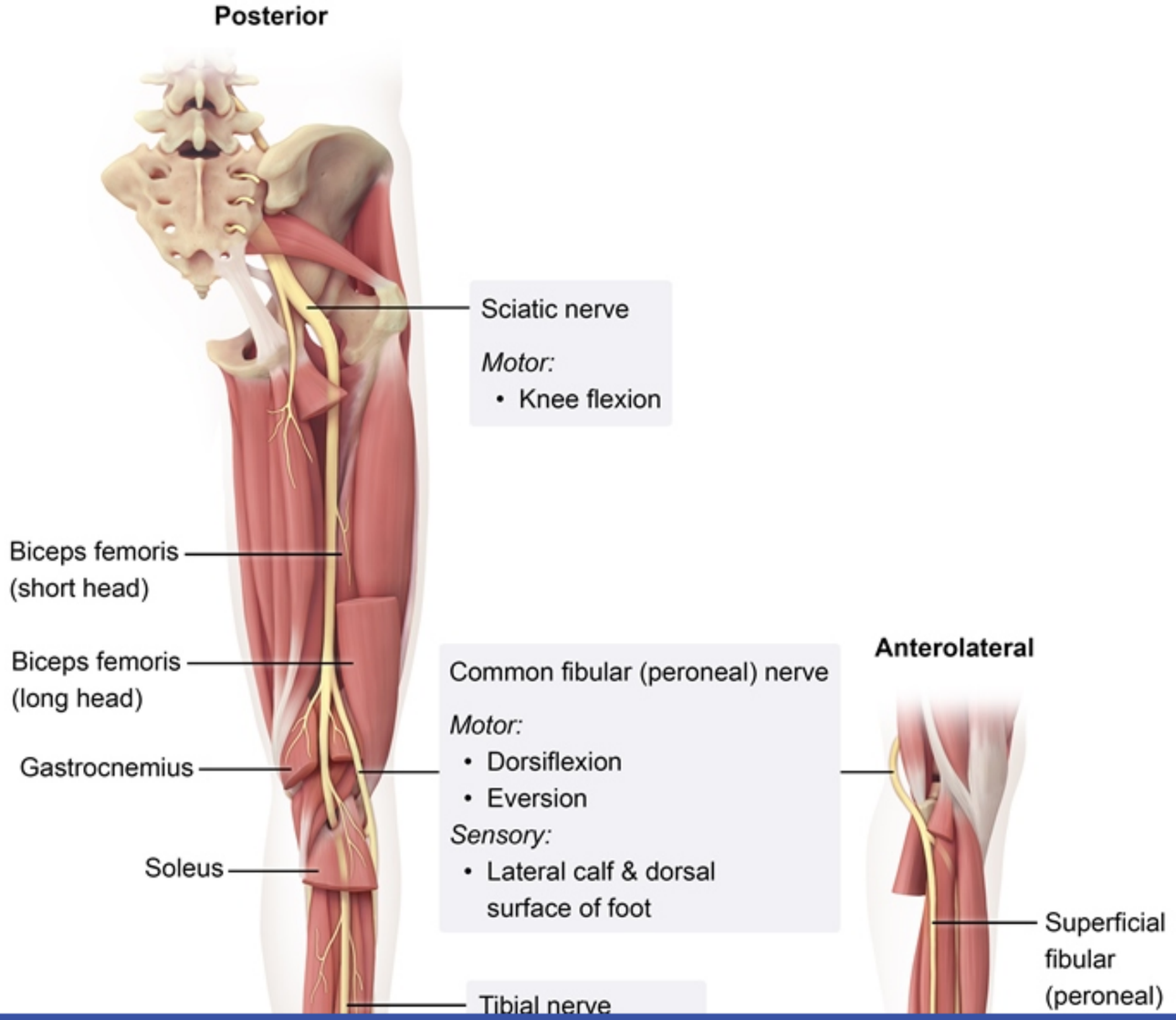

10
11
12
13
14
15
16
17
18
19
20
21
22
23
24
25
26
27
28
29
30
31
32
33
34
35
36
37
38
39
40

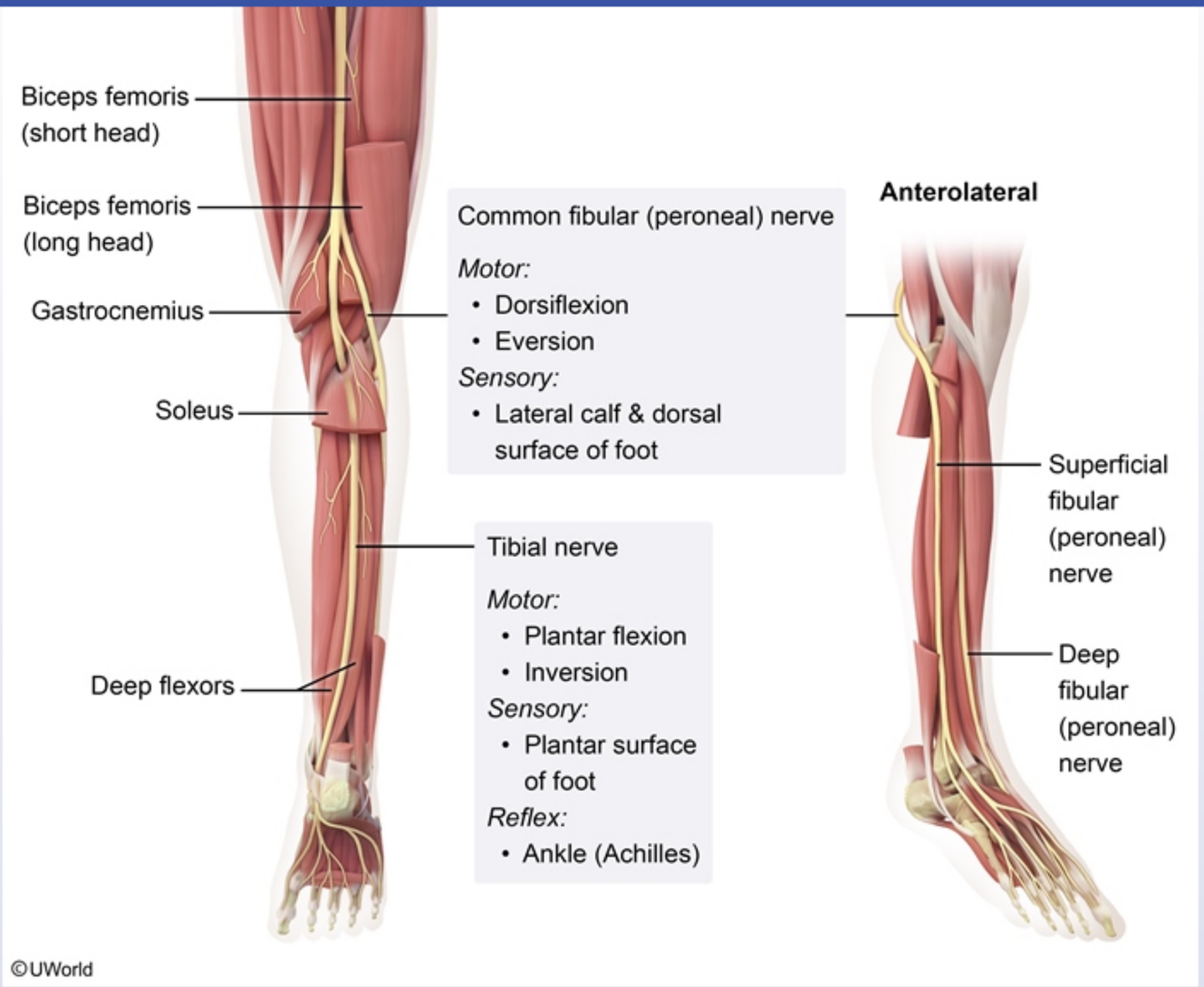

The sciatic nerve branches into the **common fibular (peroneal) nerve** and the tibial nerve just proximal to the popliteal fossa. After coursing around the neck of the fibula, the common fibular nerve divides into deep and superficial branches. The deep branch innervates the anterior compartment muscles of the leg (foot and toe dorsiflexion) and provides sensation to the webspace between the first and second toes. The

©UWorld

The sciatic nerve branches into the **common fibular (peroneal) nerve** and the tibial nerve just proximal to the popliteal fossa. After coursing around the neck of the fibula, the common fibular nerve divides into deep and superficial branches. The deep branch innervates the anterior compartment muscles of the leg (foot and toe dorsiflexion) and provides sensation to the webspace between the first and second toes. The superficial branch innervates the lateral compartment muscles (foot eversion) and provides sensation to the dorsum of the foot and lateral shin.

The common fibular nerve is frequently injured by trauma (eg, lateral blows to the knee, tightly applied plaster casts) due to its superficial location at the **neck of the fibula**. Common fibular nerve injury can cause weakness on foot dorsiflexion (ie, **foot drop**) and eversion, as well as **impaired sensation** over the lateral shin and **dorsal foot** and between the first and second toes.

(Choice A) Compartment syndrome can occur with fracture/casting of the extremities because increased pressure in a confined space can compromise blood flow. Patients initially have severe pain out of proportion to the degree of injury, followed by weakness and sensory loss. Anterior compartment syndrome can injure the deep branch of the fibular nerve, causing impaired foot dorsiflexion and sensory loss between the first and second toes, but it would not affect foot eversion or sensation to the dorsal surface of the foot.

(Choice C) Lateral compartment syndrome can injure the superficial branch of the fibular nerve, causing impaired foot eversion and sensory loss over the lateral shin and dorsum of the foot; weakness in foot dorsiflexion would not be expected.

(Choices D and E) After coursing through the popliteal fossa, the tibial nerve innervates the posterior compartment muscles of the leg. It then passes through the tarsal tunnel below the medial malleolus and provides sensory innervation over the sole and motor innervation to the intrinsic foot muscles. Tibial nerve injury at the popliteal fossa can cause weakness on foot plantar flexion, foot inversion, and toe flexion, whereas injury at the tarsal tunnel can cause sensory loss over the sole with intrinsic foot muscle weakness.

Educational objective:
Trauma/sustained pressure to the neck of the fibula can injure the common fibular nerve, causing weakness on foot dorsiflexion and eversion along with impaired sensation over the lateral shin, dorsal foot, and between the first and second toes.

References

- Evaluation and treatment of peroneal neuropathy.

Anatomy Nervous System Peroneal neuropathy

©UWorld

Exhibit Display

Right leg - cross section

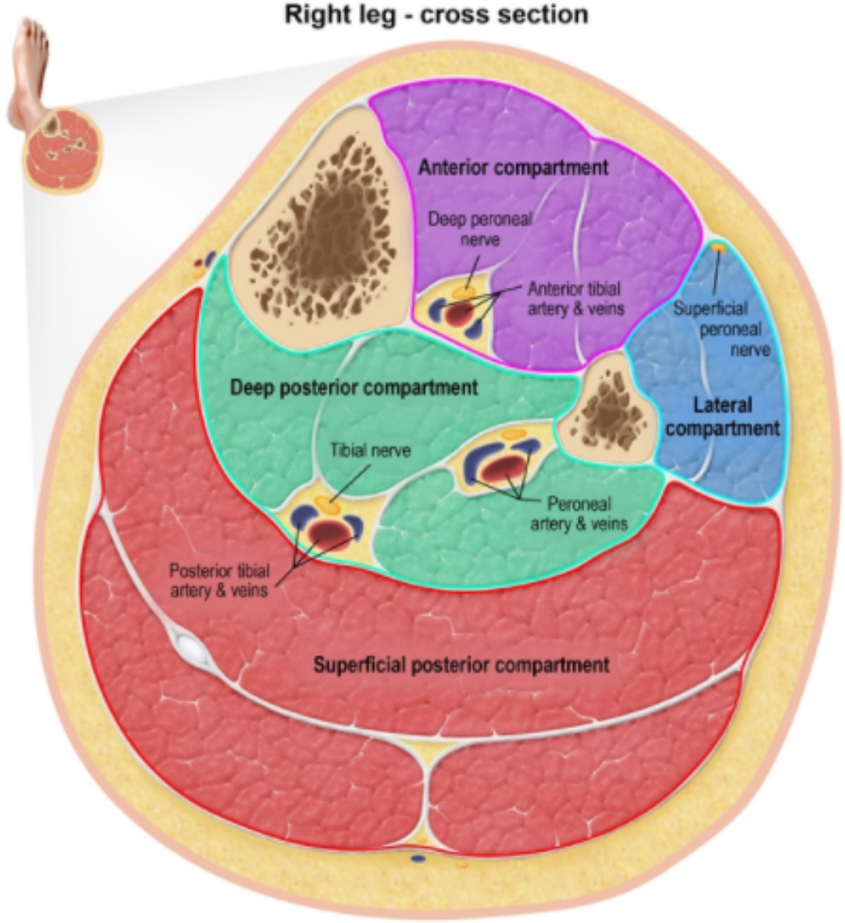

©UWorld

Zoom In | Zoom Out | Reset | Add To New Card | Existing Card

Anatomy | Nervous System | Peroneal neuropathy

10
11
12
13
14
15
16
17
18
19
20
21
22
23
24
25
26
27
28
29
30
31
32
33
34
35
36
37
38
39
40

compartment muscles of the leg (foot and toe dorsiflexion) and provides sensation to the webspace between the first and second toes. The superficial branch innervates the lateral compartment muscles (foot eversion) and provides sensation to the dorsum of the foot and lateral shin.

The common fibular nerve is frequently injured by trauma (eg, lateral blows to the knee, tightly applied plaster casts) due to its superficial location at the **neck of the fibula**. Common fibular nerve injury can cause weakness on foot dorsiflexion (ie, **foot drop**) and eversion, as well as **impaired sensation** over the lateral shin and **dorsal foot** and between the first and second toes.

(Choice A) Compartment syndrome can occur with fracture/casting of the extremities because increased pressure in a confined space can compromise blood flow. Patients initially have severe pain out of proportion to the degree of injury, followed by weakness and sensory loss. Anterior compartment syndrome can injure the deep branch of the fibular nerve, causing impaired foot dorsiflexion and sensory loss between the first and second toes, but it would not affect foot eversion or sensation to the dorsal surface of the foot.

(Choice C) Lateral compartment syndrome can injure the superficial branch of the fibular nerve, causing impaired foot eversion and sensory loss over the lateral shin and dorsum of the foot; weakness in foot dorsiflexion would not be expected.

(Choices D and E) After coursing through the popliteal fossa, the tibial nerve innervates the posterior compartment muscles of the leg. It then passes through the tarsal tunnel below the medial malleolus and provides sensory innervation over the sole and motor innervation to the intrinsic foot muscles. Tibial nerve injury at the popliteal fossa can cause weakness on foot plantar flexion, foot inversion, and toe flexion, whereas injury at the tarsal tunnel can cause sensory loss over the sole with intrinsic foot muscle weakness.

Educational objective:
Trauma/sustained pressure to the neck of the fibula can injure the common fibular nerve, causing weakness on foot dorsiflexion and eversion along with impaired sensation over the lateral shin, dorsal foot, and between the first and second toes.

References

- Evaluation and treatment of peroneal neuropathy.

Anatomy	Nervous System	Peroneal neuropathy
Subject	System	Topic

Copyright © UWorld. All rights reserved.

10
11
12
13
14
15
16
17
18
19
20
21
22
23
24
25
26
27
28
29
30
31
32
33
34
35
36
37
38
39
40

A 66-year-old, right-handed man is brought to the emergency department due to left-sided numbness and weakness. The patient woke with left-hand clumsiness that rapidly progressed to profound left-sided weakness, affecting the left arm more than the left leg. He has a history of hypertension and has smoked a pack of cigarettes daily for the past 40 years. Blood pressure is 175/90 mm Hg and pulse is 82/min and regular. Neurologic examination reveals impaired touch discrimination in the left arm with left facial weakness sparing the forehead, 2/5 muscle strength in the left upper limb, and 4/5 muscle strength in the left lower limb. Right-sided strength and visual field examinations are normal. Which of the following labeled arteries is most likely occluded in this patient?

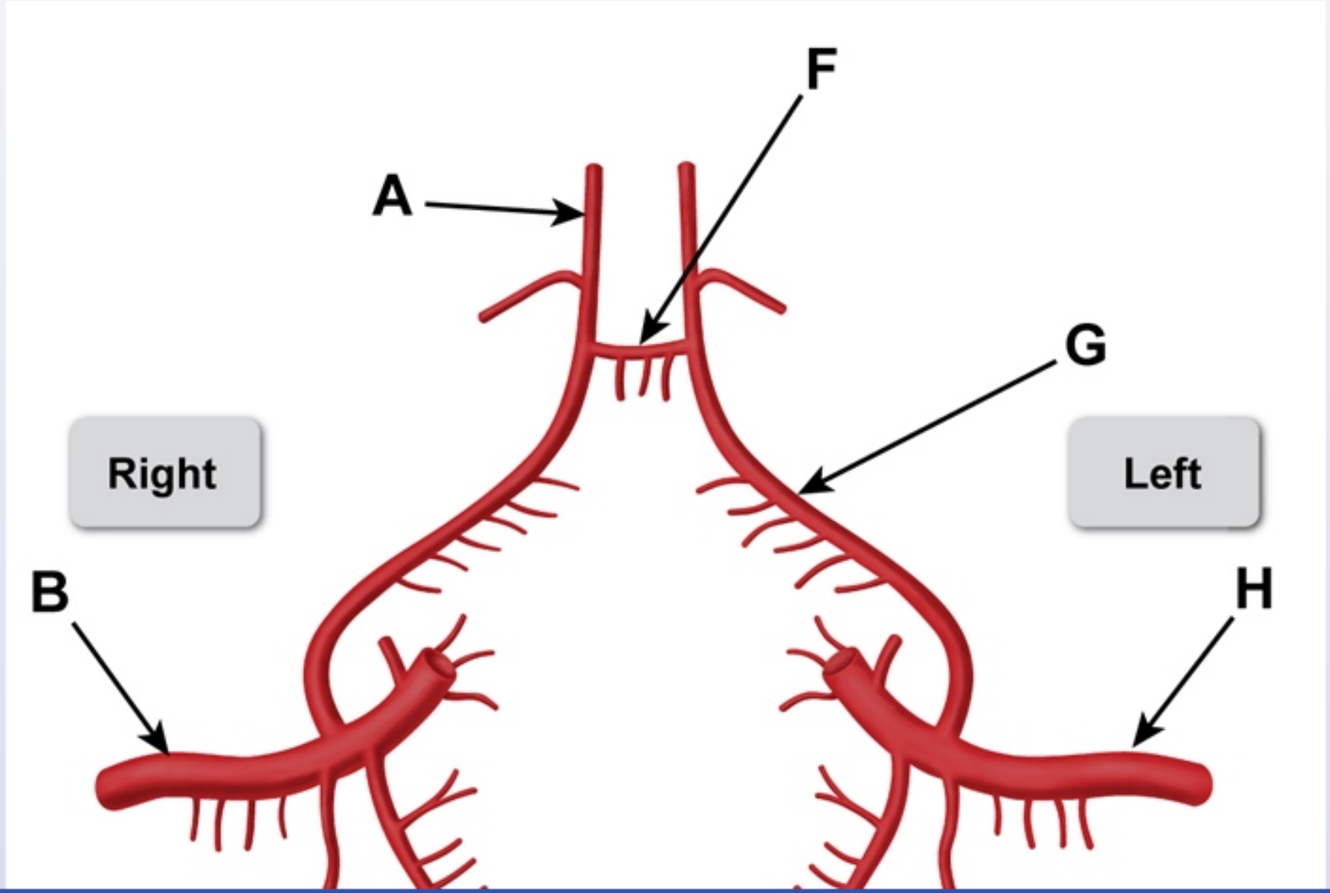

10
11
12
13
14
15
16
17
18
19
20
21
22
23
24
25
26
27
28
29
30
31
32
33
34
35
36
37
38
39
40

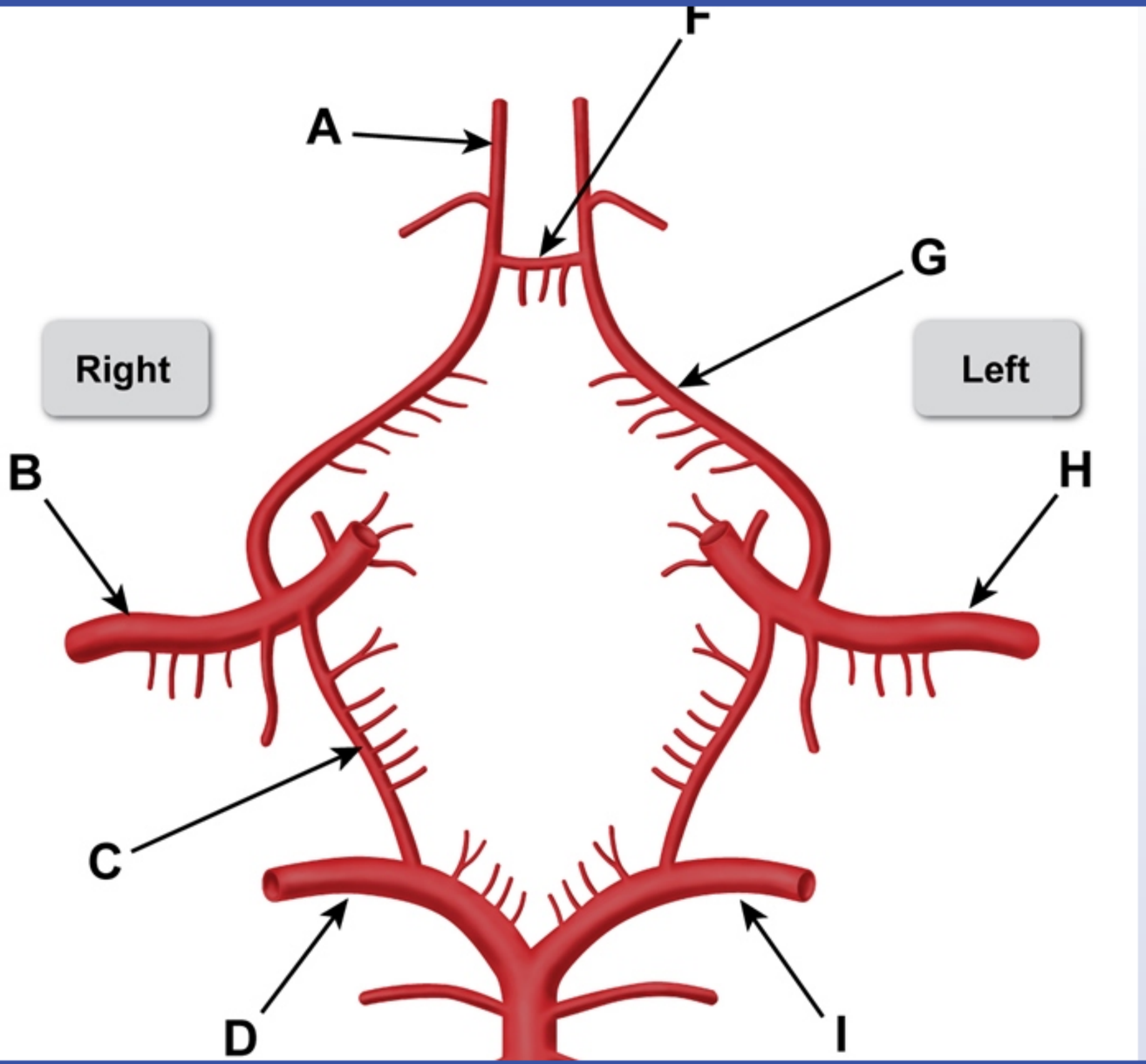

10
11
12
13
14
15
16
17
18
19
20
21
22
23
24
25
26
27
28
29
30
31
32
33
34
35
36
37
38
39
40

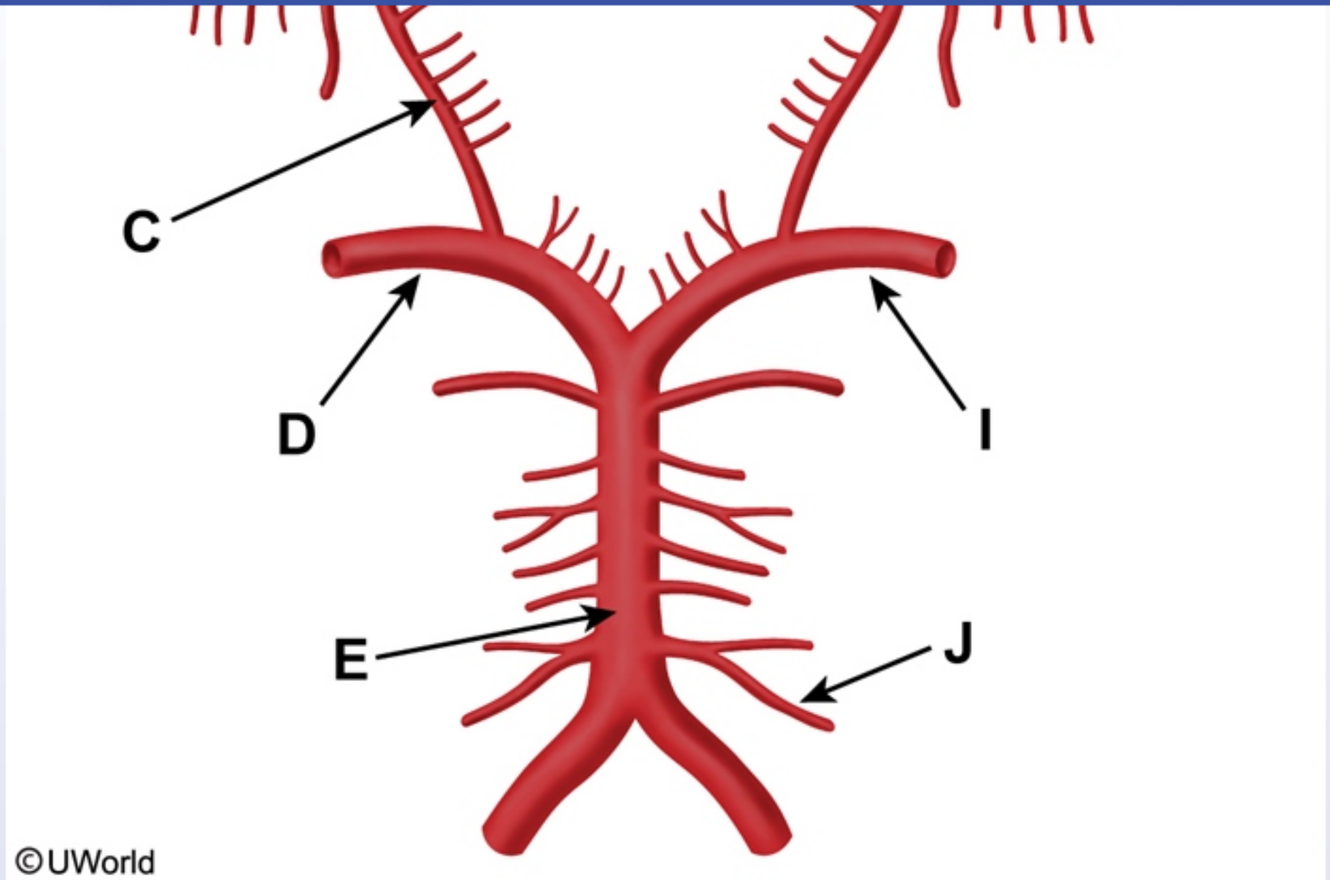

A. A

B. B

C. C

D. D

E. E

10
11
12
13
14
15
16
17
18
19
20
21
22
23
24
25
26
27
28
29
30
31
32
33
34
35
36
37
38
39
40

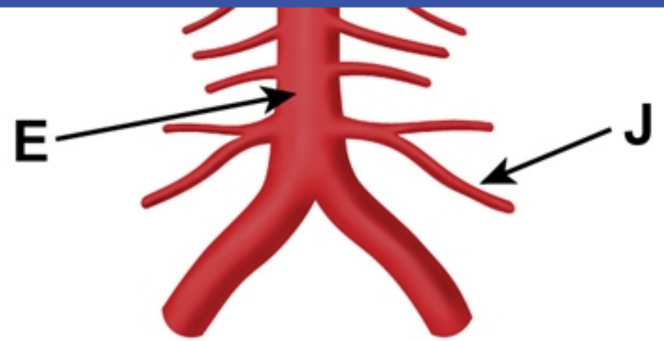

©UWorld

A. A
B. B
C. C
D. D
E. E
F. F
G. G
H. H
I. I
J. J

Submit

10
11
12
13
14
15
16
17
18
19
20
21
22
23
24
25
26
27
28
29
30
31
32
33
34
35
36
37
38
39
40

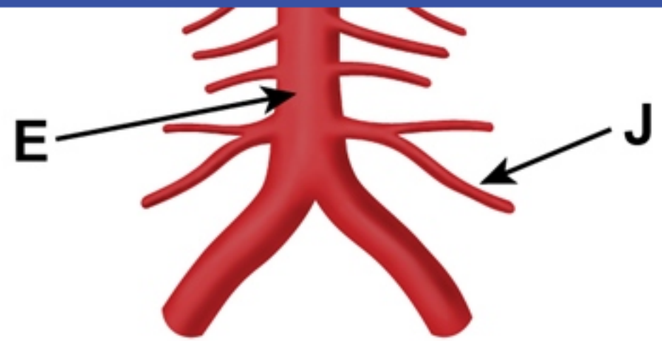

©UWorld

A. A (6%)
✓ B. B (69%)
C. C (4%)
D. D (3%)
E. E (1%)
F. F (0%)
G. G (2%)
H. H (7%)
I. I (1%)
J. J (2%)

Omitted
Correct answer

69%
Answered correctly

08 secs
Time Spent

05/24/2020
Last Updated

10
11
12
13
14
15
16
17
18
19
20
21
22
23
24
25
26
27
28
29
30
31
32
33
34
35
36
37
38
39
40

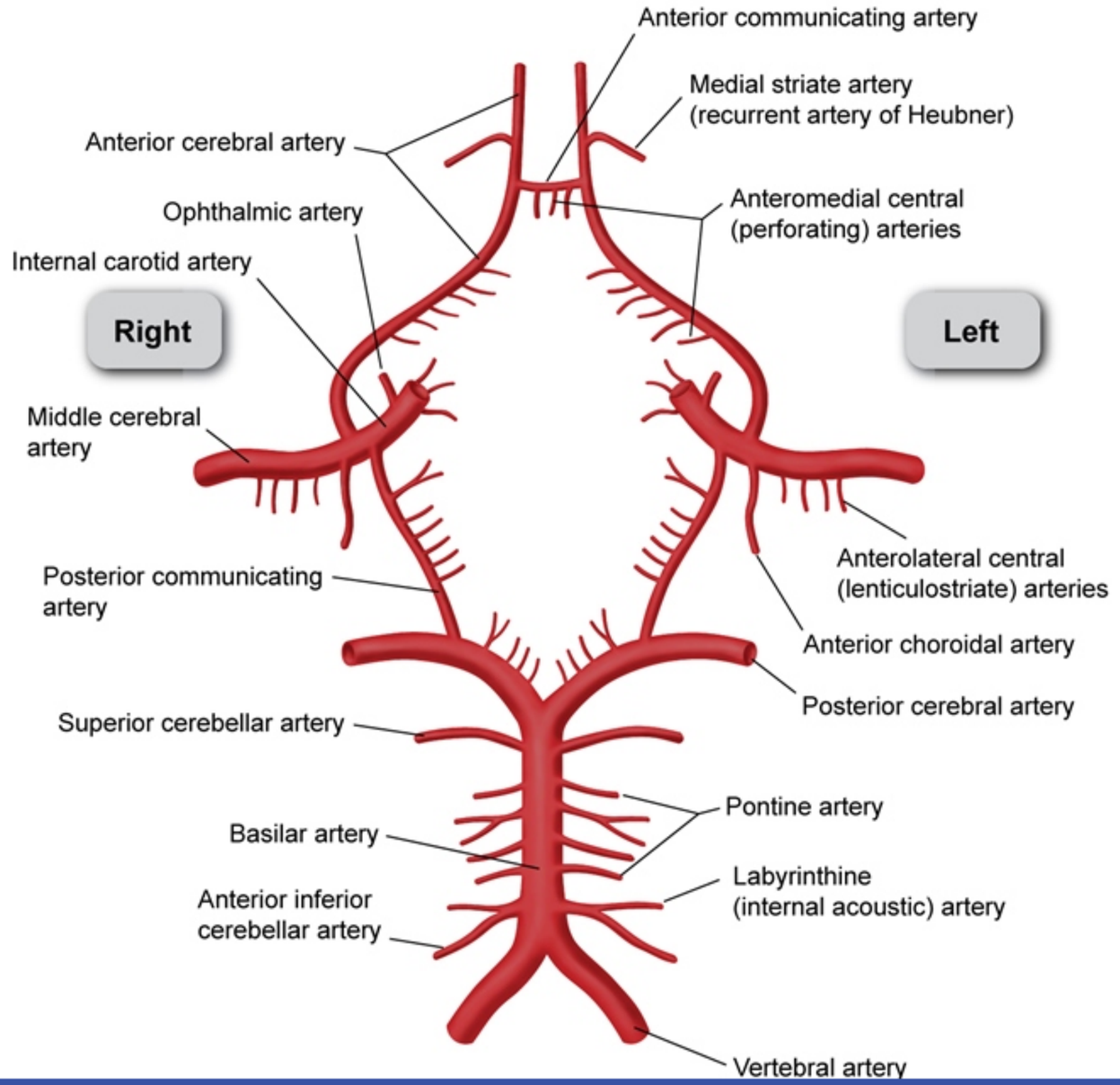

This patient has most likely had an acute ischemic stroke involving the territory supplied by the right middle cerebral artery (MCA). Patients with **MCA occlusion** usually present with **contralateral hemiparesis** and **hemisensory loss** involving the **face and upper limb** due to infarction of the corresponding motor and sensory cortices. The contralateral lower limb is typically less affected. Other features may include spatial neglect of the contralateral side (damage to the nondominant parietal lobe) and contralateral homonymous quadrantanopia (damage to the optic radiations in the subcortical temporoparietal lobe).

If the stroke affects the dominant (usually left) hemisphere, the speech areas of the brain can be damaged. Consequently, patients with left MCA stroke (right-sided motor and sensory deficits) also often have expressive or receptive aphasia due to infarction of the Broca and Wernicke areas, respectively **(Choice H)**.

(Choices A and G) Occlusion of the anterior cerebral artery causes contralateral motor and sensory deficits, with the lower limb being affected more than the upper limb. Bilateral anterior cerebral artery occlusion can cause significant behavioral symptoms (eg, abulia), primitive reflexes (eg, Moro, grasp), and urinary incontinence due to damage of the prefrontal cortex.

(Choices C and F) Saccular aneurysms often affect the anterior and posterior communicating arteries in the circle of Willis. Anterior communicating artery aneurysms can compress the central optic chiasm, causing bitemporal hemianopia. Posterior communicating artery aneurysm frequently compresses the oculomotor nerve, producing ipsilateral mydriasis, ptosis, and "down and out" eye deviation.

(Choices D and I) Posterior cerebral artery territory infarction typically results in contralateral hemianopia due to infarction of the visual cortex. The macula is often spared due to collateral circulation from the MCA.

(Choice E) Basilar artery occlusion usually damages the base of the pons, which contains the corticospinal and corticobulbar tracts, and the paramedian tegmentum. Consequently, patients typically have quadriplegia, bulbar dysfunction (eg, facial weakness, dysarthria), and oculomotor deficits (eg, horizontal gaze palsy).

(Choice J) Occlusion of the anterior inferior cerebellar artery causes lateral pontine syndrome. Patients with this condition typically have ipsilateral loss of pain or temperature in the face (trigeminal nucleus), ipsilateral facial weakness (facial nucleus), ipsilateral hearing impairment (cochlear nucleus), contralateral loss of pain and temperature in the trunk and extremities (lateral spinothalamic tract), and cerebellar dysfunction (eg, ataxia, dysmetria).

Educational objective:
Occlusion of the middle cerebral artery (MCA) typically results in contralateral hemiparesis and hemisensory loss of the face and upper limb with

This patient has most likely had an acute ischemic stroke involving the territory supplied by the right middle cerebral artery (MCA). Patients with

Exhibit Display

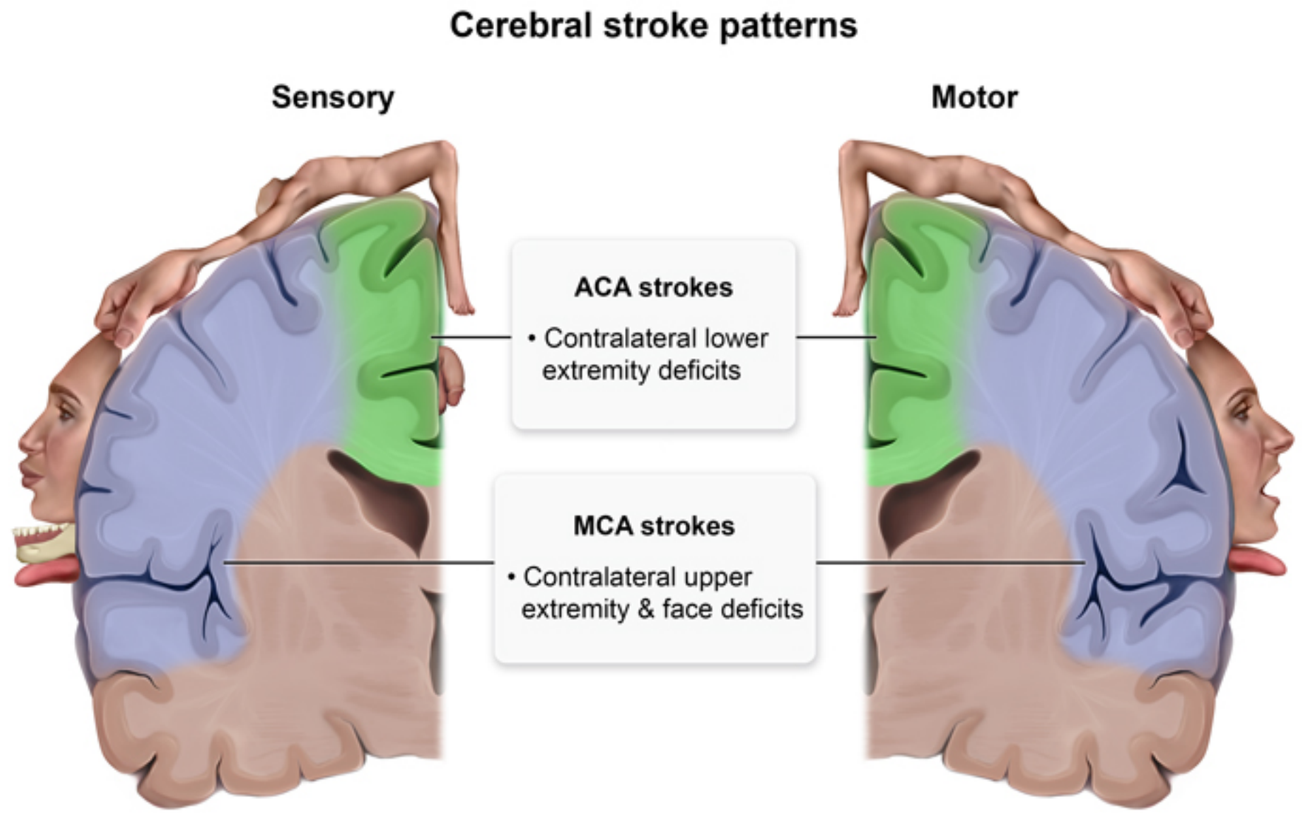

ACA = anterior cerebral artery; **MCA** = middle cerebral artery.

©UWorld

Zoom In | Zoom Out | Reset | Add To New Card | Existing Card

Occlusion of the middle cerebral artery (MCA) typically results in contralateral hemiparesis and hemisensory loss of the face and upper limb with

This patient has most likely had an acute ischemic stroke involving the territory supplied by the right middle cerebral artery (MCA). Patients with

Exhibit Display

Blood supply to regions of cerebral cortex

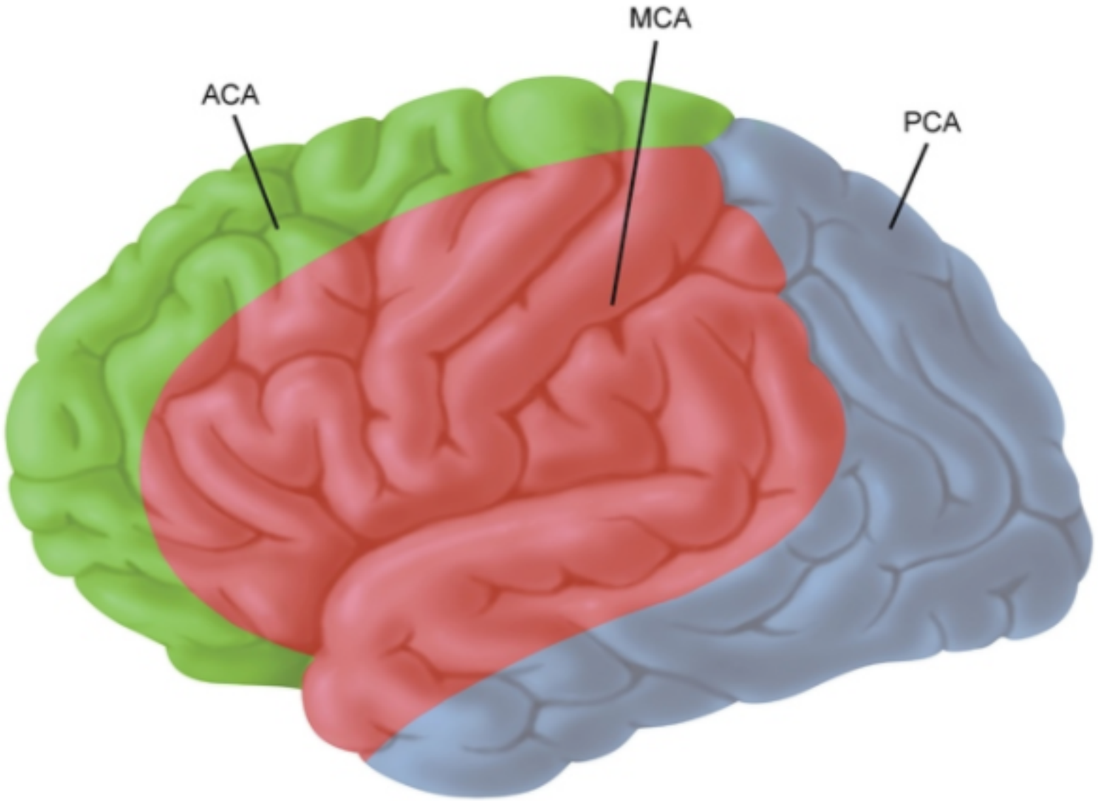

ACA = anterior cerebral artery; **MCA** = middle cerebral artery; **PCA** = posterior cerebral artery.
©UWorld

Zoom In | Zoom Out | Reset | Add To New Card | Existing Card

Occlusion of the middle cerebral artery (MCA) typically results in contralateral hemiparesis and hemisensory loss of the face and upper limb with

This patient has most likely had an acute ischemic stroke involving the territory supplied by the right middle cerebral artery (MCA). Patients with

Exhibit Display

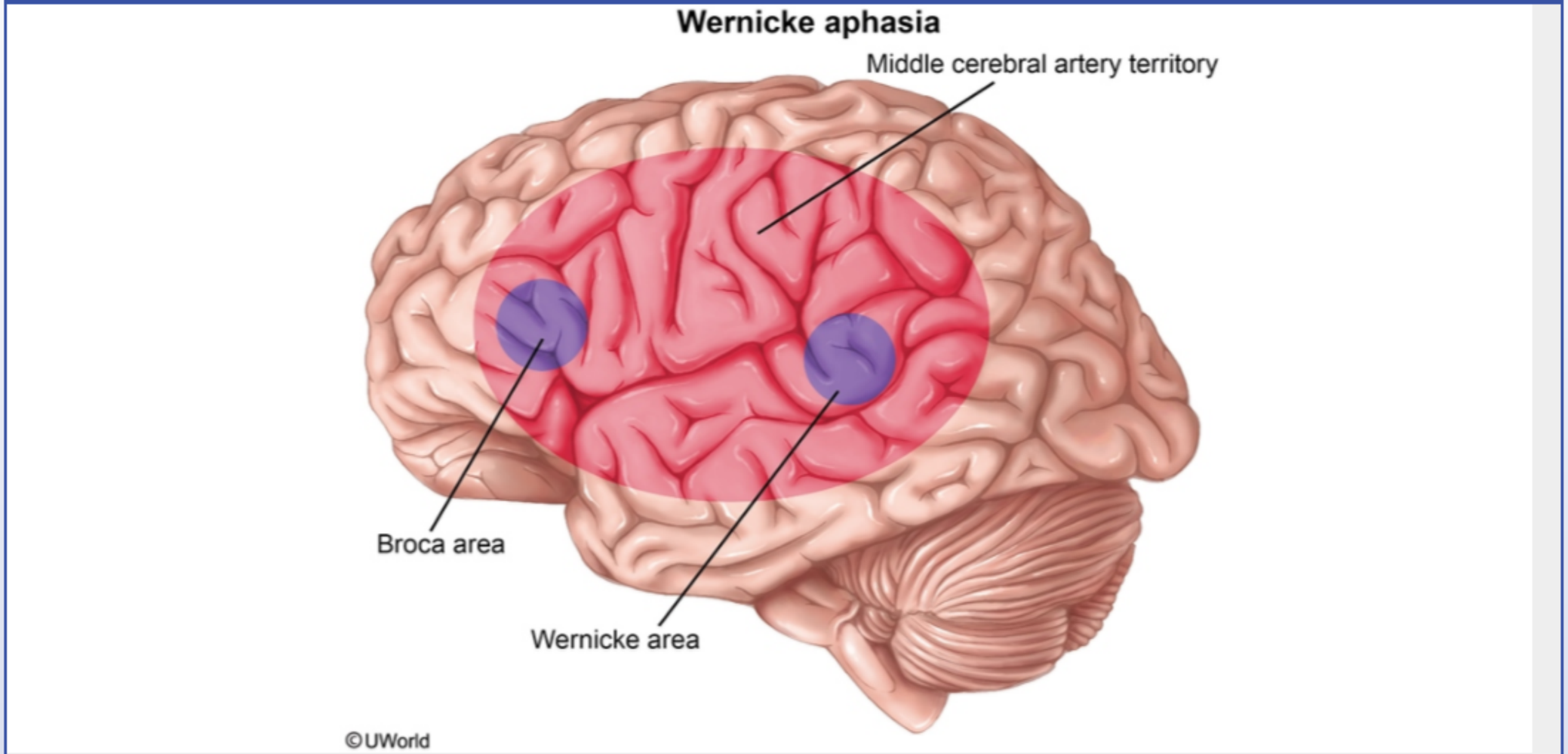

Zoom In | Zoom Out | Reset | Add To New Card | Existing Card

Occlusion of the middle cerebral artery (MCA) typically results in contralateral hemiparesis and hemisensory loss of the face and upper limb with

This patient has most likely had an acute ischemic stroke involving the territory supplied by the right middle cerebral artery (MCA). Patients with

Exhibit Display

Berry (saccular) aneurysms

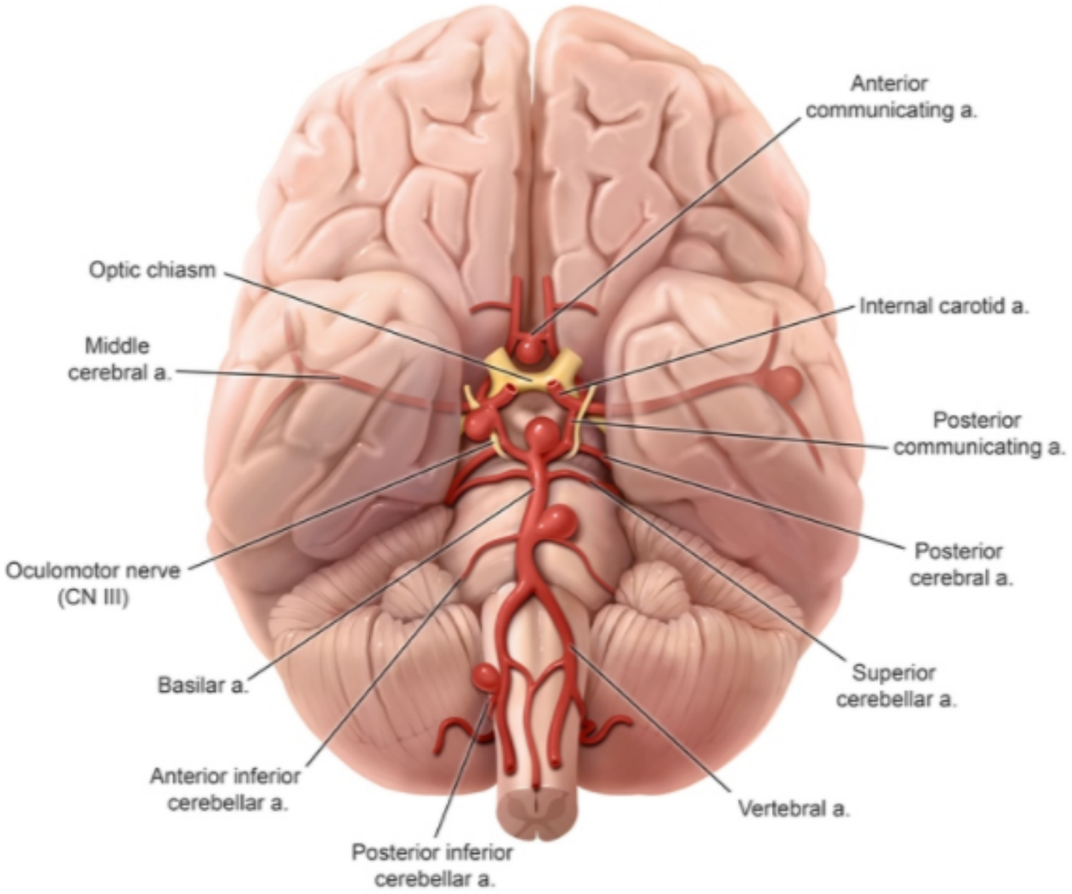

©UWorld

Zoom In | Zoom Out | Reset | Add To New Card | Existing Card

Occlusion of the middle cerebral artery (MCA) typically results in contralateral hemiparesis and hemisensory loss of the face and upper limb with

(Choices A and G) Occlusion of the anterior cerebral artery causes contralateral motor and sensory deficits, with the lower limb being affected more than the upper limb. Bilateral anterior cerebral artery occlusion can cause significant behavioral symptoms (eg, abulia), primitive reflexes (eg, Moro, grasp), and urinary incontinence due to damage of the prefrontal cortex.

(Choices C and F) Saccular aneurysms often affect the anterior and posterior communicating arteries in the circle of Willis. Anterior communicating artery aneurysms can compress the central optic chiasm, causing bitemporal hemianopia. Posterior communicating artery aneurysm frequently compresses the oculomotor nerve, producing ipsilateral mydriasis, ptosis, and "down and out" eye deviation.

(Choices D and I) Posterior cerebral artery territory infarction typically results in contralateral hemianopia due to infarction of the visual cortex. The macula is often spared due to collateral circulation from the MCA.

(Choice E) Basilar artery occlusion usually damages the base of the pons, which contains the corticospinal and corticobulbar tracts, and the paramedian tegmentum. Consequently, patients typically have quadriplegia, bulbar dysfunction (eg, facial weakness, dysarthria), and oculomotor deficits (eg, horizontal gaze palsy).

(Choice J) Occlusion of the anterior inferior cerebellar artery causes lateral pontine syndrome. Patients with this condition typically have ipsilateral loss of pain or temperature in the face (trigeminal nucleus), ipsilateral facial weakness (facial nucleus), ipsilateral hearing impairment (cochlear nucleus), contralateral loss of pain and temperature in the trunk and extremities (lateral spinothalamic tract), and cerebellar dysfunction (eg, ataxia, dysmetria).

Educational objective:
Occlusion of the middle cerebral artery (MCA) typically results in contralateral hemiparesis and hemisensory loss of the face and upper limb with relative preservation of lower limb function. If the occluded MCA is in the dominant (usually left) hemisphere, aphasia may also occur.

References

- Stroke syndromes and clinical management.

Anatomy	Nervous System	Ischemic stroke
Subject	System	Topic

Copyright © UWorld. All rights reserved.

10
11
12
13
14
15
16
17
18
19
20
21
22
23
24
25
26
27
28
29
30
31
32
33
34
35
36
37
38
39
40

A 19-year-old man comes to the emergency department after being stabbed in the right arm during a fight. The patient has no chronic medical conditions. Vital signs are within normal limits. Examination of the right upper extremity shows a 4-cm laceration oriented transversely over the volar (flexor) surface of the proximal forearm. The patient is taken to the operating room for surgical repair. While exploring the wound, a nerve that courses between the flexor digitorum superficialis and profundus muscles is found to be transected. Which of the following movements is most likely to be impaired in this patient?

A. Adduction of the third and fourth digits
B. Adduction of the thumb
C. Extension of the metacarpophalangeal joints
D. Extension of the wrist
E. Opposition of the thumb
F. Supination of the forearm

Submit

10
11
12
13
14
15
16
17
18
19
20
21
22
23
24
25
26
27
28
29
30
31
32
33
34
35
36
37
38
39
40

A 19-year-old man comes to the emergency department after being stabbed in the right arm during a fight. The patient has no chronic medical conditions. Vital signs are within normal limits. Examination of the right upper extremity shows a 4-cm laceration oriented transversely over the volar (flexor) surface of the proximal forearm. The patient is taken to the operating room for surgical repair. While exploring the wound, a nerve that courses between the flexor digitorum superficialis and profundus muscles is found to be transected. Which of the following movements is most likely to be impaired in this patient?

- A. Adduction of the third and fourth digits (13%)
- B. Adduction of the thumb (13%)
- C. Extension of the metacarpophalangeal joints (5%)
- D. Extension of the wrist (6%)
- ✓ E. Opposition of the thumb (49%)
- F. Supination of the forearm (11%)

Omitted
Correct answer
E

49%
Answered correctly

02 secs
Time Spent

01/31/2020
Last Updated

Explanation

10
11
12
13
14
15
16
17
18
19
20
21
22
23
24
25
26
27
28
29
30
31
32
33
34
35
36
37
38
39
40

Median nerve
(anterior view)

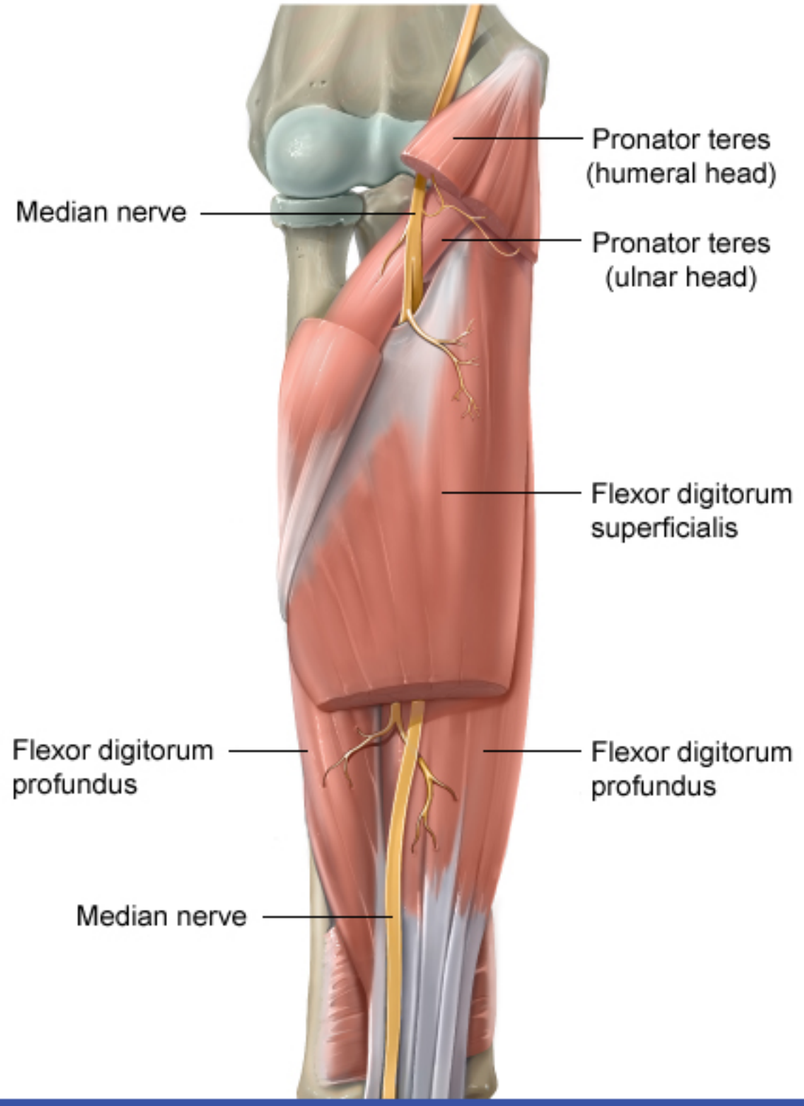

10
11
12
13
14
15
16
17
18
19
20
21
22
23
24
25
26
27
28
29
30
31
32
33
34
35
36
37
38
39
40

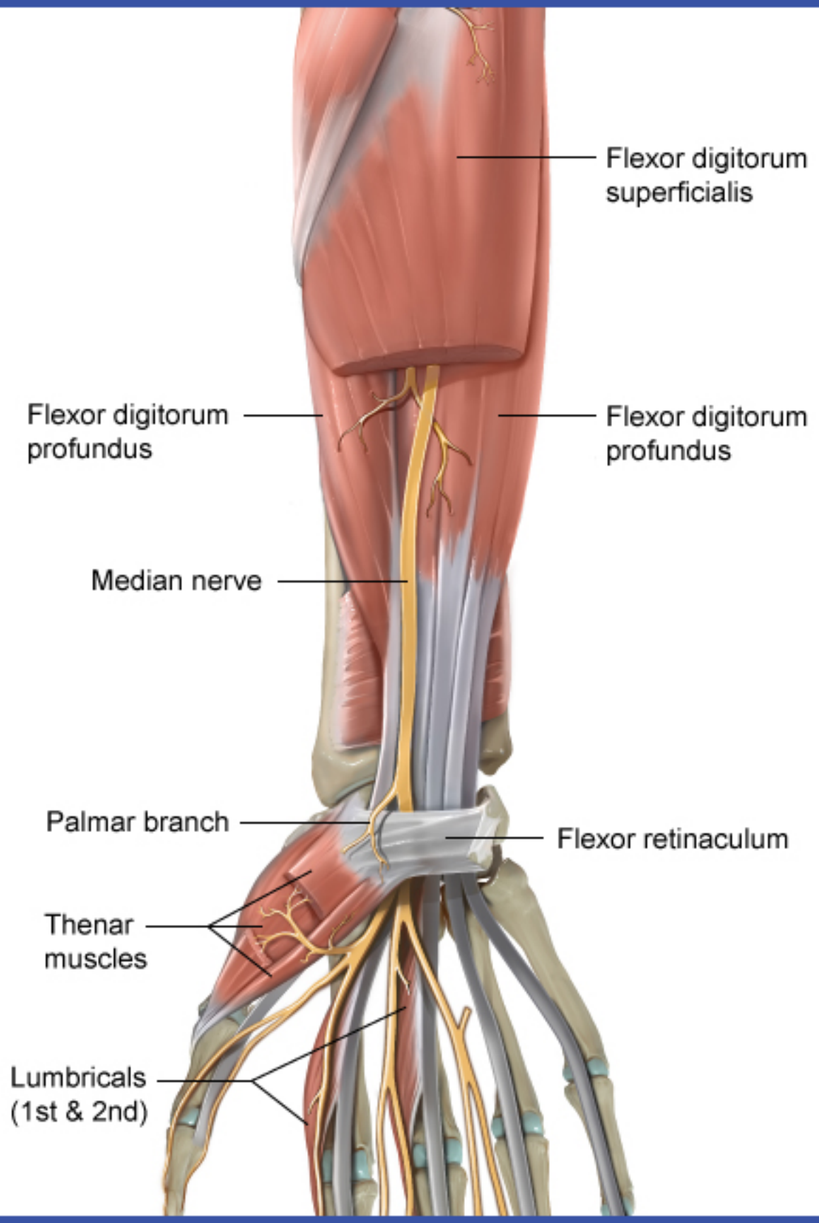

10
11
12
13
14
15
16
17
18
19
20
21
22
23
24
25
26
27
28
29
30
31
32
33
34
35
36
37
38
39
40

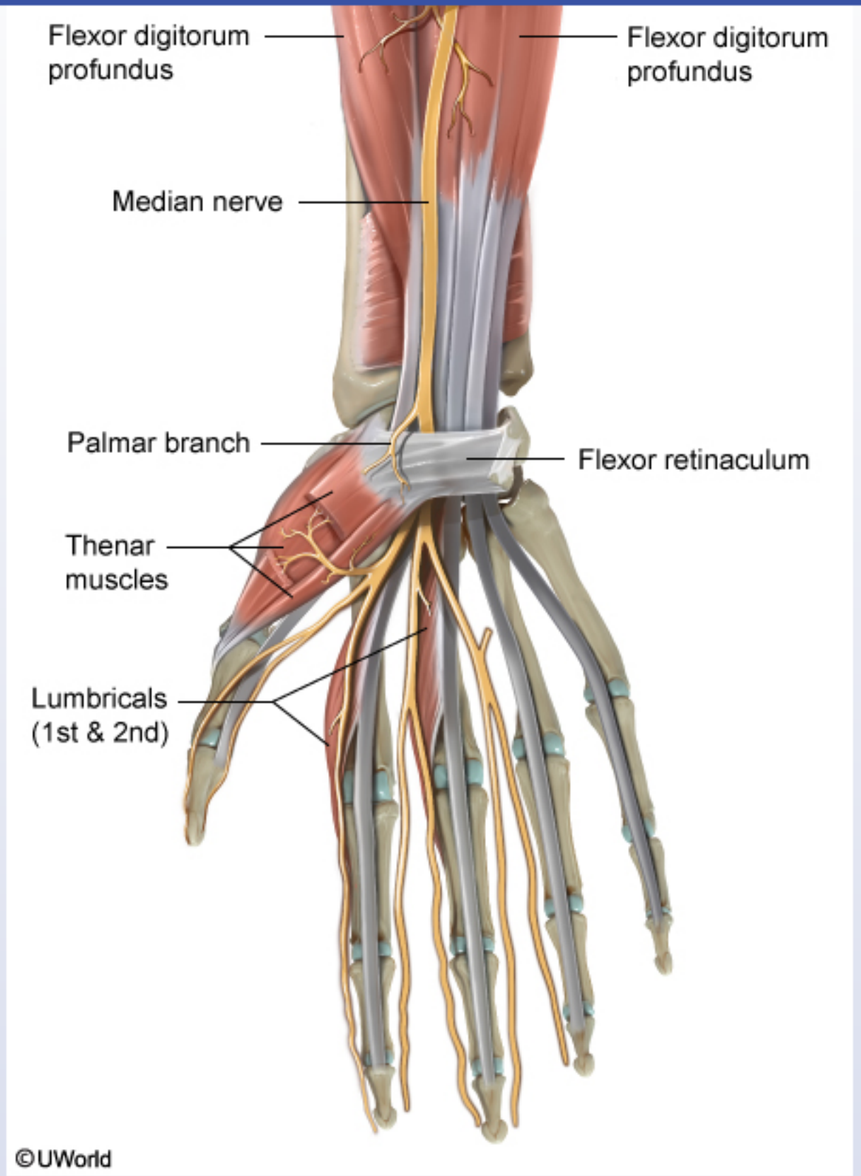

The **median nerve** is formed from spinal nerves C5-T1 via the medial and lateral cords of the brachial plexus. It courses with the brachial artery

©UWorld

The **median nerve** is formed from spinal nerves C5-T1 via the medial and lateral cords of the brachial plexus. It courses with the brachial artery between the biceps brachii and brachialis muscles before entering the forearm. In the anterior (volar) forearm, the median nerve passes between the heads of the pronator teres before coursing **between the flexor digitorum superficialis and profundus** muscles. It ultimately passes into the hand through the carpal tunnel beneath the flexor retinaculum.

The median nerve is most commonly injured by compression within the carpal tunnel (ie, carpal tunnel syndrome), leading to pain and numbness in the first 3 digits and lateral half of the fourth, along with **weakness of thumb flexion and opposition**. However, the nerve can be injured more proximally by penetrating trauma to the upper forearm, supracondylar fracture, or entrapment between the heads of pronator teres. In addition to the above symptoms, proximal injury causes decreased sensation over the thenar eminence and weakness of flexion in the wrist and second and third digits (ie, preacher or **benediction hand**).

(Choices A and B) The adductor pollicis muscle (adduction of the thumb) and palmar interossei (adduction of the third and fourth digits) are innervated by the deep branch of the ulnar nerve. The ulnar nerve courses between the flexor digitorum profundus and flexor carpi ulnaris in the medial forearm.

(Choices C and F) The extensor digitorum (extension of digits at metacarpophalangeal joints) and supinator (supination of forearm) are innervated by the deep branch of the radial nerve (posterior interosseous nerve). This nerve runs in the posterior forearm between the deep and superficial extensor muscles.

(Choice D) Extension of the wrist is largely performed by extensor carpi ulnaris and extensor carpi radialis longus and brevis, which are innervated by the radial nerve. The radial nerve courses between the medial and lateral heads of the triceps brachii in the upper arm before splitting into deep and superficial branches.

Educational objective:
The median nerve is most commonly injured within the carpal tunnel, leading to pain and numbness in the first 3 digits and lateral half of the fourth, as well as weakness of thumb flexion and opposition. More proximal injury (in the forearm) additionally causes decreased sensation over the thenar eminence and weakness of flexion in the wrist and second and third digits.

References

- High median nerve injuries.

©UWorld

The **median nerve** is formed from spinal nerves C5-T1 via the medial and lateral cords of the brachial plexus. It courses with the brachial artery between the biceps brachii and brachialis muscles before entering the forearm. In the anterior (volar) forearm, the median nerve passes between the heads of the pronator teres before coursing **between the flexor digitorum superficialis and profundus** muscles. It ultimately passes into the hand through the carpal tunnel beneath the flexor retinaculum.

The median nerve is most commonly injured by compression within the carpal tunnel (ie, carpal tunnel syndrome), leading to pain and numbness in the first 3 digits and lateral half of the fourth, along with **weakness of thumb flexion and opposition**. However, the nerve can be injured more proximally by penetrating trauma to the upper forearm, supracondylar fracture, or entrapment between the heads of pronator teres. In addition to the above symptoms, proximal injury causes decreased sensation over the thenar eminence and weakness of flexion in the wrist and second and third digits (ie, preacher or **benediction hand**).

(Choices A and B) The adductor pollicis muscle (adduction of the thumb) and palmar interossei (adduction of the third and fourth digits) are innervated by the deep branch of the ulnar nerve. The ulnar nerve courses between the flexor digitorum profundus and flexor carpi ulnaris in the medial forearm.

(Choices C and F) The extensor digitorum (extension of digits at metacarpophalangeal joints) and supinator (supination of forearm) are innervated by the deep branch of the radial nerve (posterior interosseous nerve). This nerve runs in the posterior forearm between the deep and superficial extensor muscles.

(Choice D) Extension of the wrist is largely performed by extensor carpi ulnaris and extensor carpi radialis longus and brevis, which are innervated by the radial nerve. The radial nerve courses between the medial and lateral heads of the triceps brachii in the upper arm before splitting into deep and superficial branches.

Educational objective:
The median nerve is most commonly injured within the carpal tunnel, leading to pain and numbness in the first 3 digits and lateral half of the fourth, as well as weakness of thumb flexion and opposition. More proximal injury (in the forearm) additionally causes decreased sensation over the thenar eminence and weakness of flexion in the wrist and second and third digits.

References

- High median nerve injuries.

©UWorld

Exhibit Display

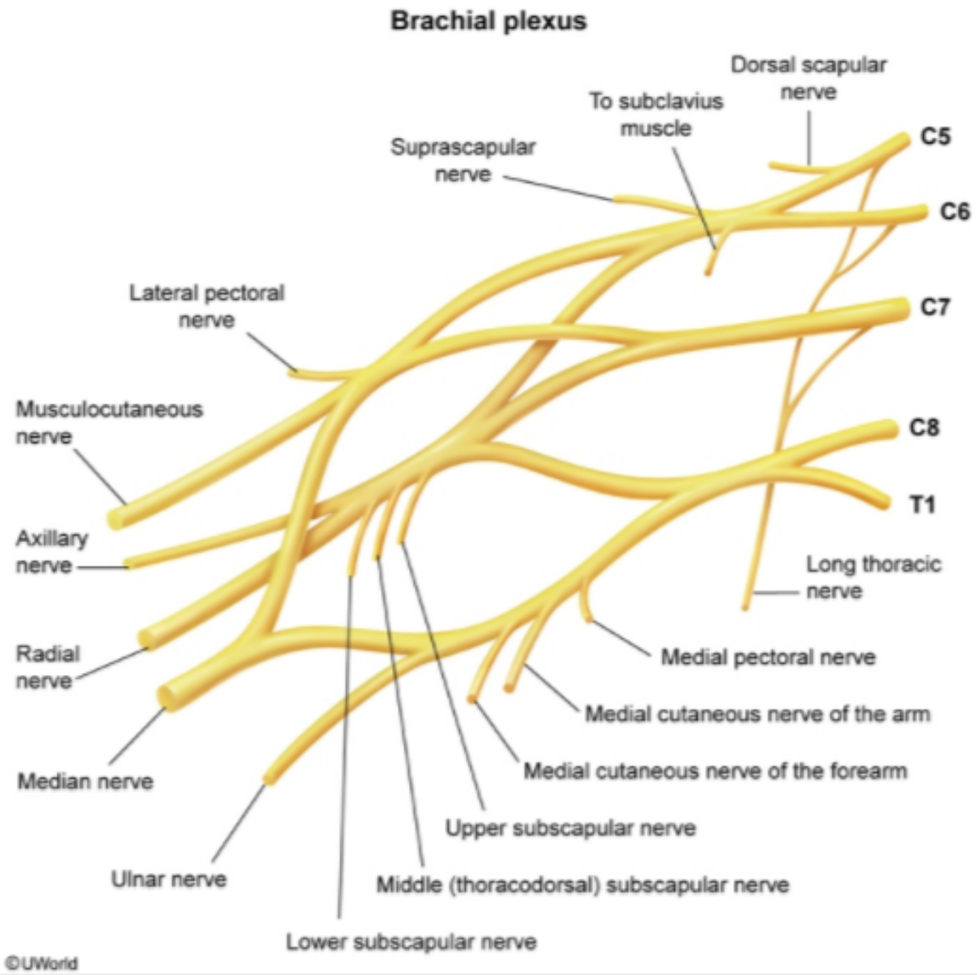

Zoom In | Zoom Out | Reset | Add To New Card | Existing Card

- High median nerve injuries.

©UWorld

Exhibit Display

Carpal tunnel, palmar view

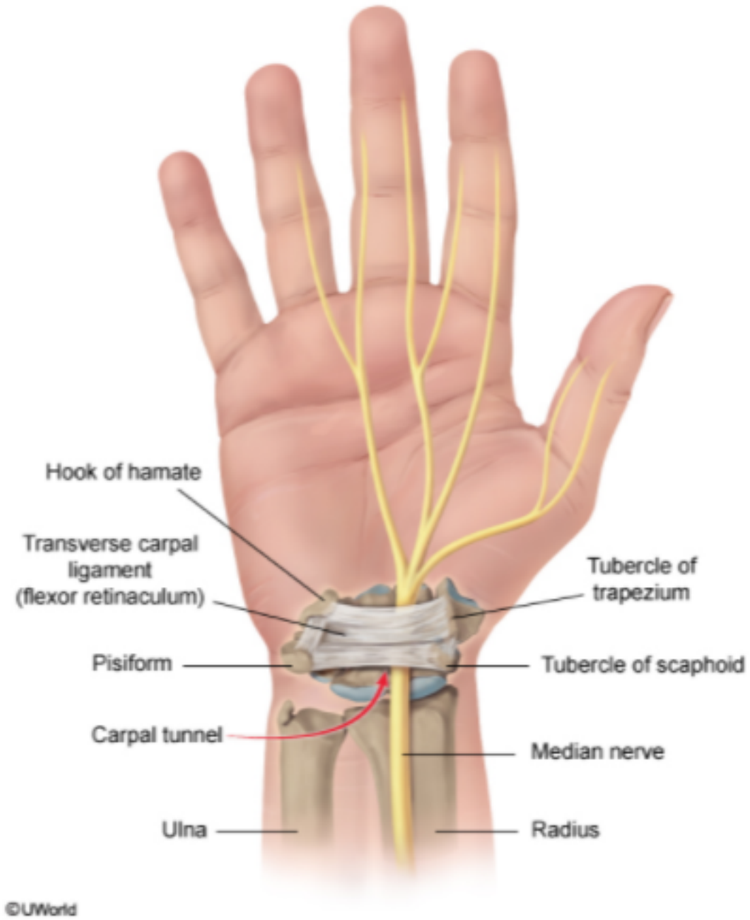

Zoom In | Zoom Out | Reset | Add To New Card | Existing Card

- High median nerve injuries.

©UWorld

Exhibit Display

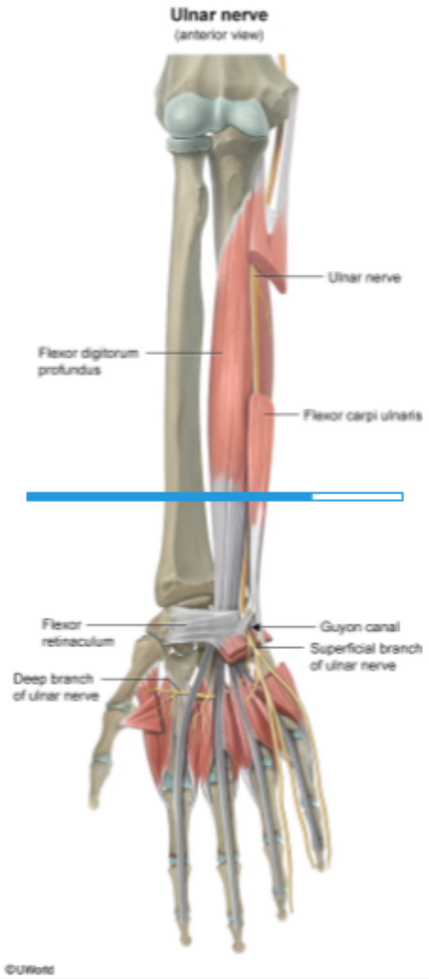

Zoom In | Zoom Out | Reset | Add To New Card | Existing Card

- High median nerve injuries.

©UWorld

The **median nerve** is formed from spinal nerves C5-T1 via the medial and lateral cords of the brachial plexus. It courses with the brachial artery between the b
the heads of t
the hand throu

The median n
in the first 3 di
proximally by
the above sym
third digits (ie,

(Choices A a
innervated by
medial forearm

(Ch
innervated by
superficial ext

(Choice D) E
innervated by
splitting into d

Educational
The median n
fourth, as well
the thenar emi

References

- High medi

Exhibit Display

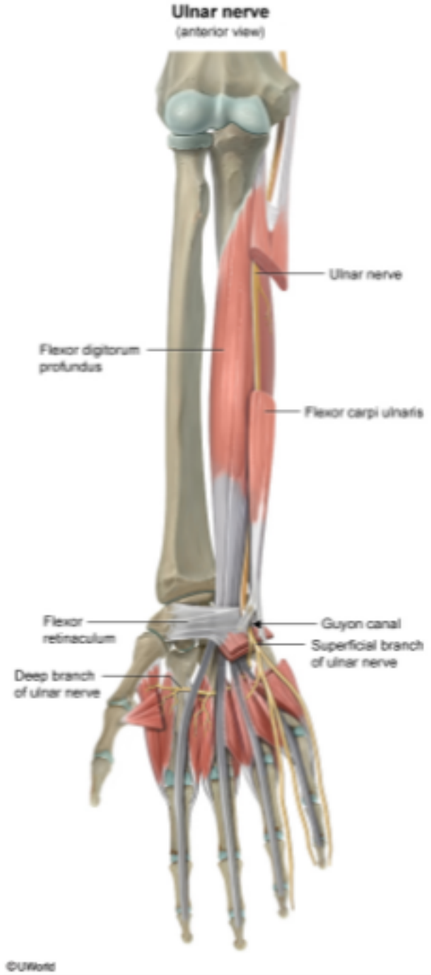

Zoom In | Zoom Out | Reset | Add To New Card | Existing Card

©UWorld

Exhibit Display

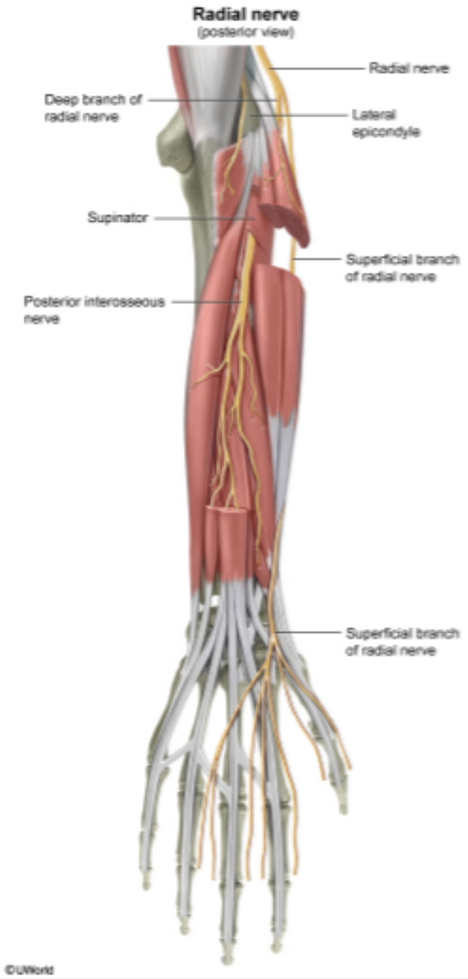

Zoom In | Zoom Out | Reset | Add To New Card | Existing Card

- High median nerve injuries.

10
11
12
13
14
15
16
17
18
19
20
21
22
23
24
25
26
27
28
29
30
31
32
33
34
35
36
37
38
39
40

©UWorld

Exhibit Display

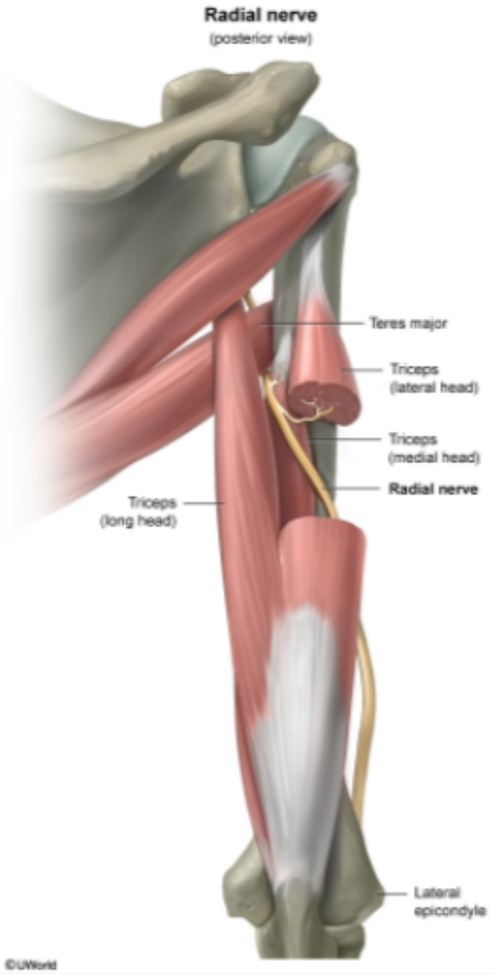

Zoom In | Zoom Out | Reset | Add To New Card | Existing Card

- High median nerve injuries.

A 51-year-old woman comes to the physician complaining that the right side of her face has felt "funny" for the past 12 hours. Her past medical history is significant for type 2 diabetes mellitus. Physical examination reveals asymmetry of her face when she smiles, puffs out her cheeks, and closes her eyes tightly. There is also effacement of the right nasolabial fold, and her mouth is drawn toward the left side. Which of the following additional findings is most likely associated with this patient's condition?

A. Attenuated sense of touch on the right side of face

B. Decreased tearing from the right eye

C. Failure to elevate the palate when saying "ah"

D. Inability to sweat on the right side of face

E. Loss of taste sensation from the posterior 1/3 of the tongue

Submit

A 51-year-old woman comes to the physician complaining that the right side of her face has felt "funny" for the past 12 hours. Her past medical history is significant for type 2 diabetes mellitus. Physical examination reveals asymmetry of her face when she smiles, puffs out her cheeks, and closes her eyes tightly. There is also effacement of the right nasolabial fold, and her mouth is drawn toward the left side. Which of the following additional findings is most likely associated with this patient's condition?

- A. Attenuated sense of touch on the right side of face (13%)
- ✓ B. Decreased tearing from the right eye (57%)
- C. Failure to elevate the palate when saying "ah" (7%)
- D. Inability to sweat on the right side of face (14%)
- E. Loss of taste sensation from the posterior 1/3 of the tongue (7%)

Omitted
Correct answer
B

57%
Answered correctly

03 secs
Time Spent

06/02/2020
Last Updated

Explanation

This patient's presentation is consistent with Bell's palsy, an idiopathic paresis of the facial nerve. To understand the pathophysiology of Bell's palsy, it is important to understand the function of the facial nerve (CN VII). The facial nerve is a mixed nerve, consisting of the following:

1. Motor output to the facial muscles
2. Parasympathetic innervation to the lacrimal, submandibular, and sublingual salivary glands
3. Special afferent fibers for taste from the anterior 2/3 of the tongue
4. Somatic afferents from the pinna and external auditory canal

This patient's presentation is consistent with Bell's palsy, an idiopathic paresis of the facial nerve. To understand the pathophysiology of Bell's palsy, it is important to understand the function of the facial nerve (CN VII). The facial nerve is a mixed nerve, consisting of the following:

1. Motor output to the facial muscles
2. Parasympathetic innervation to the lacrimal, submandibular, and sublingual salivary glands
3. Special afferent fibers for taste from the anterior 2/3 of the tongue
4. Somatic afferents from the pinna and external auditory canal

Patients with Bell's palsy typically present with sudden onset of unilateral facial paralysis. Specific findings include impaired eye closure, eyebrow sagging, inability to smile and frown on the affected side, disappearance of the nasolabial fold, and the mouth being drawn to the non-affected side. Patients afflicted with Bell's palsy may also have decreased tearing, hyperacusis, and/or loss of taste sensation over the anterior two-thirds of the tongue.

(Choice A) Trigeminal nerve (CN V) somatic afferents are responsible for providing general sensation over the face; the motor branch of the trigeminal nerve (V_3) innervates the muscles of mastication and the tensor tympani.

(Choice C) Palate elevation and the gag reflex involve the glossopharyngeal (CN IX) and vagus (CN X) nerves.

(Choice D) Horner's syndrome occurs due to interruption of sympathetic innervation and clinically presents with ptosis, miosis, anhydrosis, and enophthalmos. Post-synaptic sympathetic axons travel in a perivascular plexus along the carotid arteries to reach and innervate the face.

(Choice E) Taste sensation from the posterior 1/3 of the tongue is provided by the glossopharyngeal nerve (CN IX).

Educational objective:
In addition to unilateral facial paralysis, patients with Bell's palsy may experience decreased tearing, hyperacusis, and/or loss of taste sensation over the anterior two-thirds of the tongue.

References

- Seventh cranial neuropathy.

Anatomy	Nervous System	Bell's palsy
Subject	System	Topic

A 58-year-old man undergoes operative repair of a descending thoracic aortic aneurysm. There are no intraoperative complications, but postoperatively the patient is found to have new-onset neurologic deficits. Imaging of the brain is normal, but MRI of the lower thoracic spinal cord reveals ischemic infarct of the areas shown in the exhibit below:

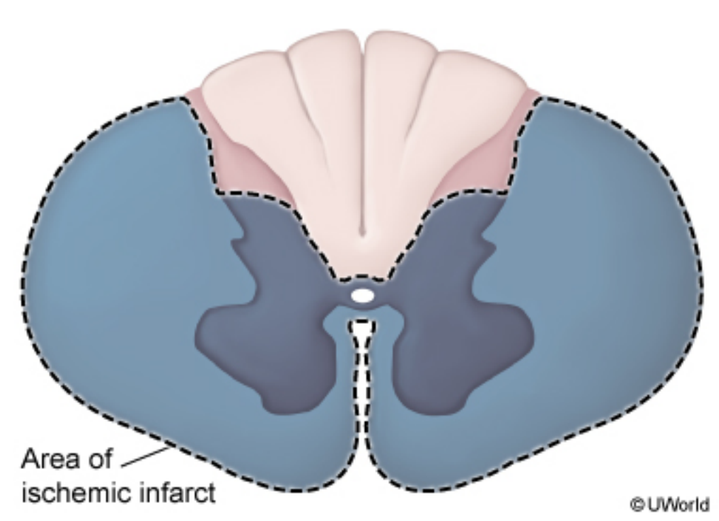

Lower extremity examination of this patient is most likely to show which of the following neurologic findings?

	Crude touch	Pain sensation	Proprioception	Motor function
A.	↓	↓	Normal	↓
B.	↓	↓	↓	↓
C.	↓	Normal	Normal	Normal
D.	Normal	Normal	↓	↓
E.	Normal	↓	Normal	Normal

10
11
12
13
14
15
16
17
18
19
20
21
22
23
24
25
26
27
28
29
30
31
32
33
34
35
36
37
38
39
40

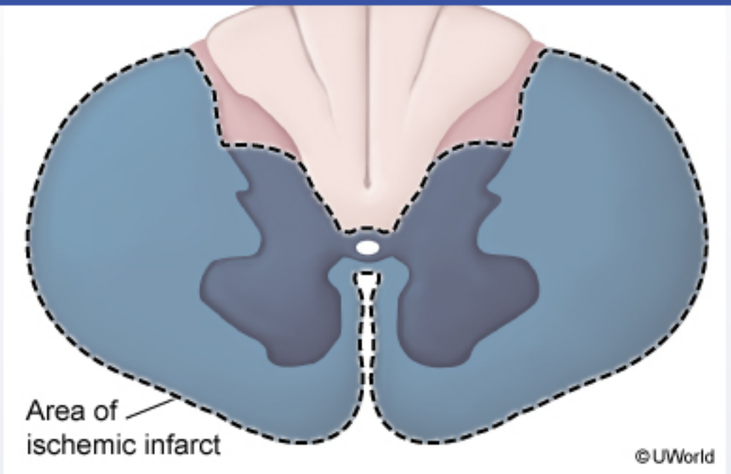

Lower extremity examination of this patient is most likely to show which of the following neurologic findings?

	Crude touch	Pain sensation	Proprioception	Motor function
A.	↓	↓	Normal	↓
B.	↓	↓	↓	↓
C.	↓	Normal	Normal	Normal
D.	Normal	Normal	↓	↓
E.	Normal	↓	Normal	Normal
F.	Normal	Normal	↓	Normal

Submit

10
11
12
13
14
15
16
17
18
19
20
21
22
23
24
25
26
27
28
29
30
31
32
33
34
35
36
37
38
39
40

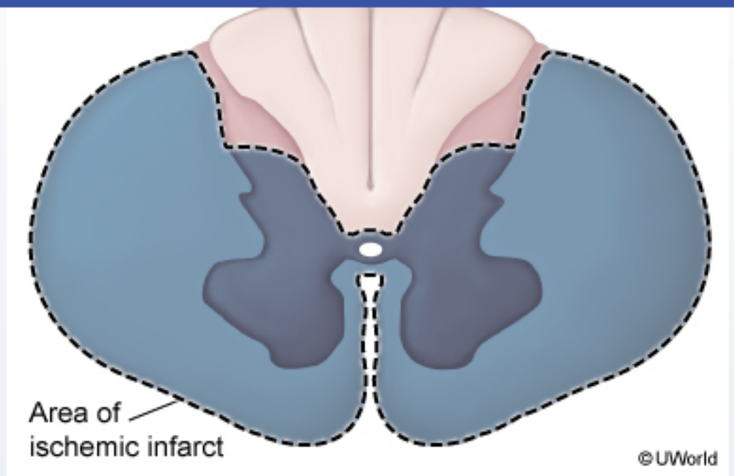

Lower extremity examination of this patient is most likely to show which of the following neurologic findings?

	Crude touch	Pain sensation	Proprioception	Motor function
A. (86%)	↓	↓	Normal	↓
B. (4%)	↓	↓	↓	↓
C. (0%)	↓	Normal	Normal	Normal
D. (4%)	Normal	Normal	↓	↓
E. (3%)	Normal	↓	Normal	Normal
F. (0%)	Normal	Normal	↓	Normal

10
11
12
13
14
15
16
17
18
19
20
21
22
23
24
25
26
27
28
29
30
31
32
33
34
35
36
37
38
39
40

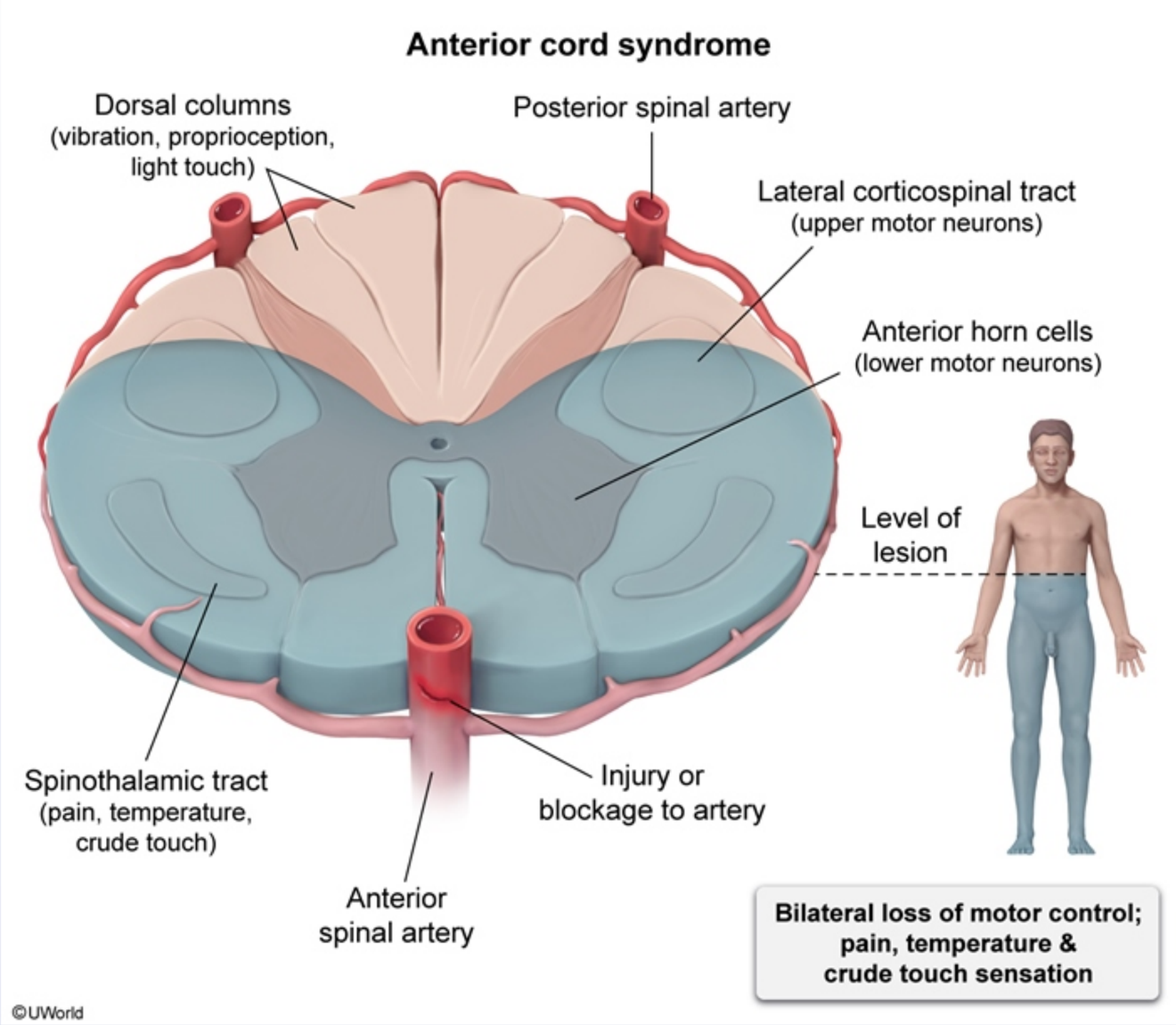

This patient's thoracic aortic aneurysm repair has been complicated by **ischemic injury** to the **anterior two-thirds** of the spinal cord (SC). This area is perfused by the **anterior spinal artery**, which receives blood flow from segmental arteries (eg, intercostal arteries) arising off the thoracic aorta. Disruption of circulation to this area classically results in **anterior cord syndrome**, characterized by the following bilateral tract lesions and clinical signs:

- Spinothalamic tract (STT): **loss** of **pain/temperature** (lateral spinothalamic) and **crude touch** (anterior spinothalamic) sensation 1-2 levels below the lesion
- Anterior horn (lower motor neuron): flaccid paralysis and muscle atrophy at the level of the lesion
- Lateral corticospinal tract (CST) (upper motor neuron): **paralysis** below the level of the lesion. Flaccid paralysis from spinal shock (ie, temporary loss of all distal SC function) occurs initially, but upper motor neuron signs (eg, spasticity, hyperreflexia) subsequently develop over days to weeks

As in this patient, the dorsal columns are typically spared (due to intact circulation from the posterior spinal arteries), preserving proprioceptive, vibratory, and light touch sensation below the level of the lesion.

(Choice B) Complete loss of all lower extremity sensation (due to injury of the STTs and dorsal columns) and motor function (due to injury of the CSTs) may be seen in complete SC injury, as can occur in SC transection.

(Choices C and E) An isolated defect of crude touch sensation or pain/temperature sensation could occur only with isolated injury to the anterior or lateral STT, respectively. Because the anterior spinal artery also supplies the tracts (eg, CSTs) surrounding the STTs, it is extremely uncommon to have bilateral injury to only the anterior or lateral STT.

(Choice D) Diminished proprioception and motor function can occur with simultaneous injury to the dorsal columns and CSTs. A classic cause is subacute combined degeneration of the dorsal and lateral SC white matter, which is seen in vitamin B_{12} deficiency.

(Choice F) Selective loss of proprioceptive (along with vibratory and light touch) sensation occurs with isolated injury of the bilateral dorsal columns. A classic example is tabes dorsalis, a form of tertiary neurosyphilis that causes damage to the dorsal columns and dorsal nerve roots.

Educational objective:
Ischemia of the anterior two-thirds of the spinal cord can occur with disruption of the anterior spinal artery blood supply. The resulting anterior cord syndrome causes bilateral distal loss of pain, temperature, and crude touch sensation (from injury to the spinothalamic tracts) and paralysis (from

over days to weeks

As in this patient, the dorsal columns are typically spared (due to intact circulation from the posterior spinal arteries), preserving proprioceptive, vibratory, and light touch sensation below the level of the lesion.

(Choice B) Complete loss of all lower extremity sensation (due to injury of the STTs and dorsal columns) and motor function (due to injury of the CSTs) may be seen in complete SC injury, as can occur in SC transection.

(Choices C and E) An isolated defect of crude touch sensation or pain/temperature sensation could occur only with isolated injury to the anterior or lateral STT, respectively. Because the anterior spinal artery also supplies the tracts (eg, CSTs) surrounding the STTs, it is extremely uncommon to have bilateral injury to only the anterior or lateral STT.

(Choice D) Diminished proprioception and motor function can occur with simultaneous injury to the dorsal columns and CSTs. A classic cause is subacute combined degeneration of the dorsal and lateral SC white matter, which is seen in vitamin B_{12} deficiency.

(Choice F) Selective loss of proprioceptive (along with vibratory and light touch) sensation occurs with isolated injury of the bilateral dorsal columns. A classic example is tabes dorsalis, a form of tertiary neurosyphilis that causes damage to the dorsal columns and dorsal nerve roots.

Educational objective:
Ischemia of the anterior two-thirds of the spinal cord can occur with disruption of the anterior spinal artery blood supply. The resulting anterior cord syndrome causes bilateral distal loss of pain, temperature, and crude touch sensation (from injury to the spinothalamic tracts) and paralysis (from injury to the lateral corticospinal tracts).

References

- Incomplete cord syndromes: clinical and imaging review.
- Spinal cord injury following thoracic and thoracoabdominal repairs.

Anatomy	Nervous System	Spinal cord injury
Subject	System	Topic

Copyright © UWorld. All rights reserved.

over days to weeks

Exhibit Display

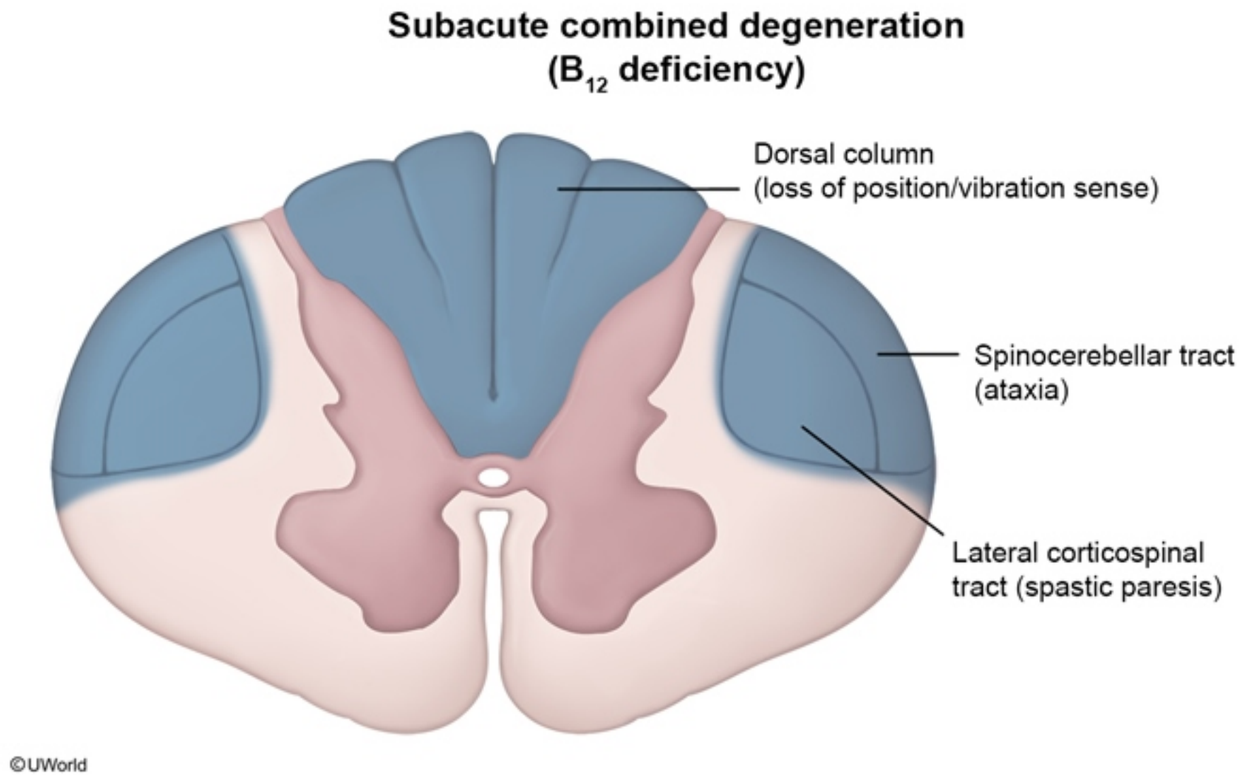

Zoom In Zoom Out Reset Add To Flash Card

over days to weeks

Exhibit Display

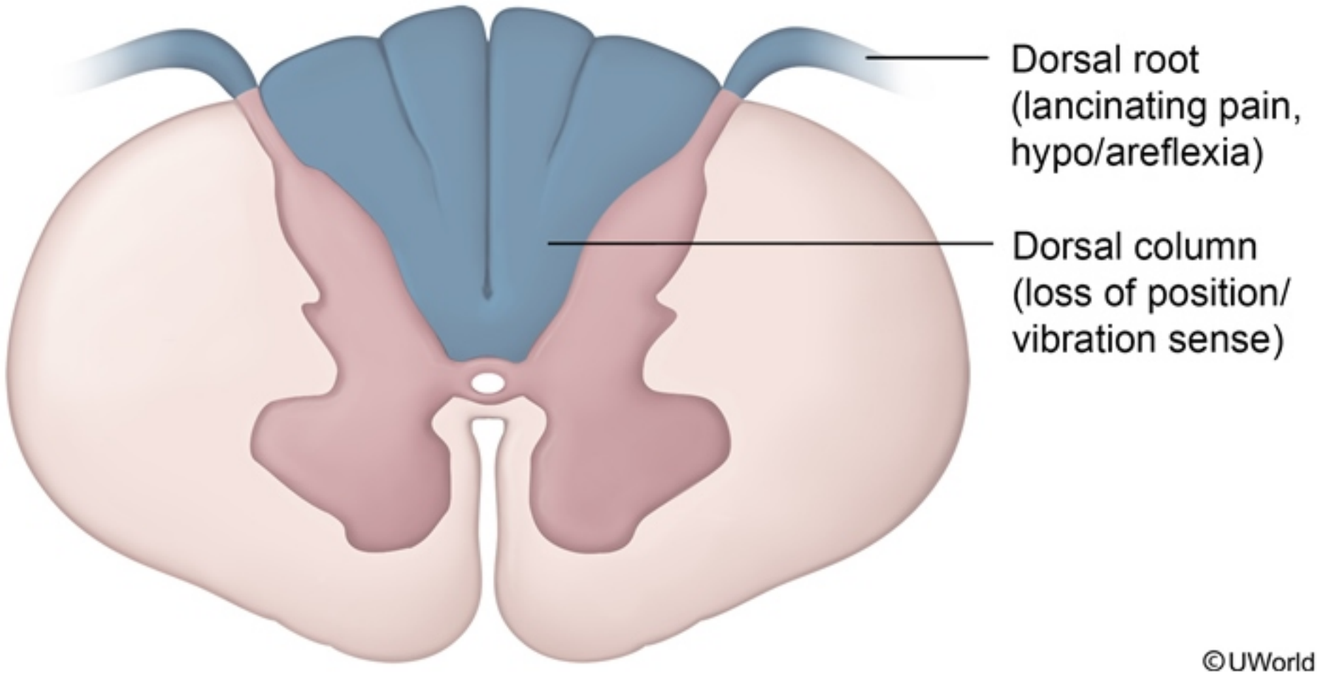

Zoom In Zoom Out Reset Add To Flash Card

spinal artery

Bilateral loss of motor control; pain, temperature &

©UWorld

This patient's thoracic aortic aneurysm repair has been complicated by **ischemic inj** area is perfused by the **anterior spinal artery**, which receives blood flow from segm aorta. Disruption of circulation to this area classically results in **anterior cord syndr** clinical signs:

- Spinothalamic tract (STT): **loss** of **pain/temperature** (lateral spinothalamic) a below the lesion
- Anterior horn (lower motor neuron): flaccid paralysis and muscle atrophy at th
- Lateral corticospinal tract (CST) (upper motor neuron): **paralysis** below the le temporary loss of all distal SC function) occurs initially, but upper motor neuro over days to weeks

As in this patient, the dorsal columns are typically spared (due to intact circulation fr vibratory, and light touch sensation below the level of the lesion.

(Choice B) Complete loss of all lower extremity sensation (due to injury of the STTs CSTs) may be seen in complete SC injury, as can occur in SC transection.

(Choices C and E) An isolated defect of crude touch sensation or pain/temperature or lateral STT, respectively. Because the anterior spinal artery also supplies the trac to have bilateral injury to only the anterior or lateral STT.

(Choice D) Diminished proprioception and motor function can occur with simultane subacute combined degeneration of the dorsal and lateral SC white matter, which is

(Choice F) Selective loss of proprioceptive (along with vibratory and light touch) se columns. A classic example is tabes dorsalis, a form of tertiary neurosyphilis that causes damage to the dorsal columns and dorsal nerve roots.

Exhibit Display

Blood supply of the spinal cord

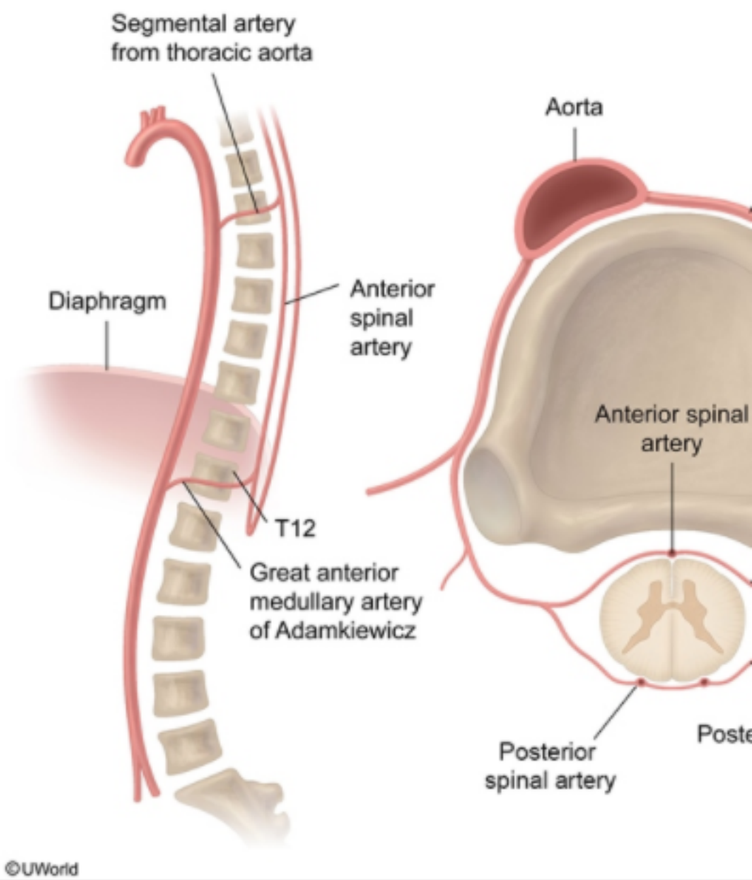

©UWorld

Zoom In
Zoom Out
Reset
Add T

spinal artery

Bilateral loss of motor control; pain, temperature & crude touch sensation

This patient's thorac
area is perfused by
aorta. Disruption of
clinical signs:

- Spinothalamic
  below the lesi
- Anterior horn
- Lateral cortico
  temporary los
  over days to w

As in this patient, th
vibratory, and light t

(Choice B) Comple
CSTs) may be seen

(Choices C and E)
or lateral STT, respe
to have bilateral inju

(Choice D) Diminis
subacute combined

(Choice F) Selectiv
columns. A classic

Exhibit Display

Blood supply of the spinal cord

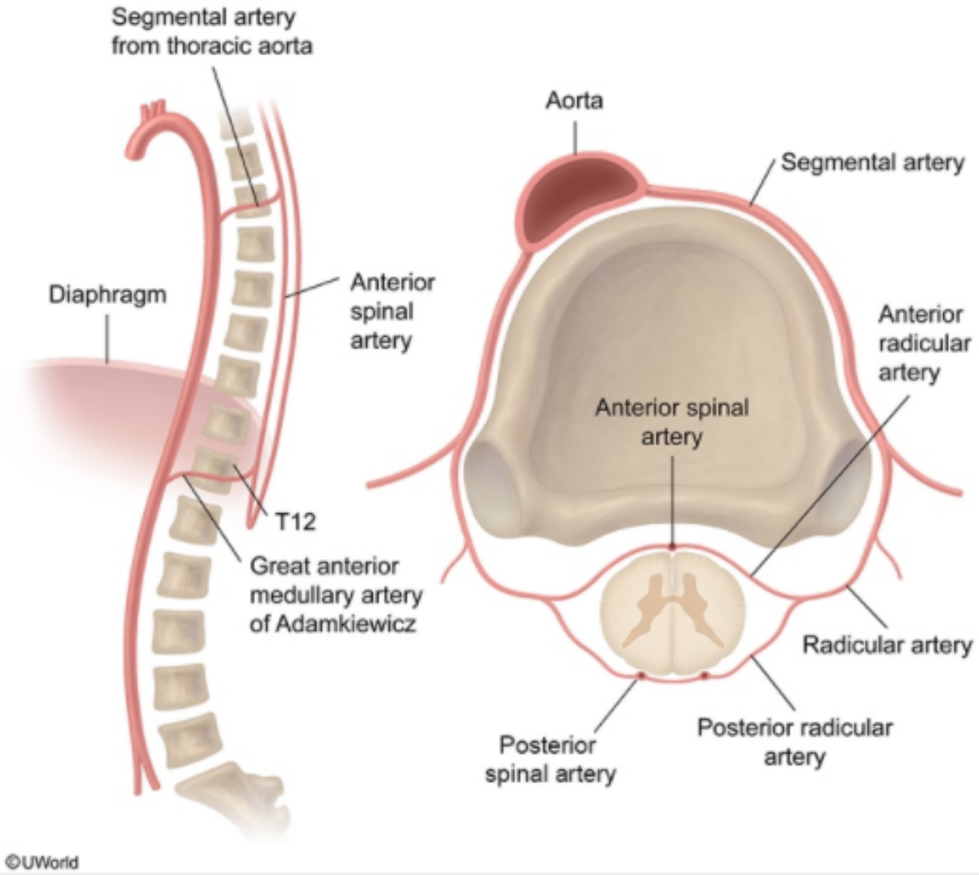

©UWorld

Zoom In
Zoom Out
Reset
Add To Flash Card

over days to weeks

As in this patient, the dorsal columns are typically spared (due to intact circulation from the posterior spinal arteries), preserving proprioceptive, vibratory, and light touch sensation below the level of the lesion.

(Choice B) Complete loss of all lower extremity sensation (due to injury of the STTs and dorsal columns) and motor function (due to injury of the CSTs) may be seen in complete SC injury, as can occur in SC transection.

(Choices C and E) An isolated defect of crude touch sensation or pain/temperature sensation could occur only with isolated injury to the anterior or lateral STT, respectively. Because the anterior spinal artery also supplies the tracts (eg, CSTs) surrounding the STTs, it is extremely uncommon to have bilateral injury to only the anterior or lateral STT.

(Choice D) Diminished proprioception and motor function can occur with simultaneous injury to the dorsal columns and CSTs. A classic cause is subacute combined degeneration of the dorsal and lateral SC white matter, which is seen in vitamin B_{12} deficiency.

(Choice F) Selective loss of proprioceptive (along with vibratory and light touch) sensation occurs with isolated injury of the bilateral dorsal columns. A classic example is tabes dorsalis, a form of tertiary neurosyphilis that causes damage to the dorsal columns and dorsal nerve roots.

Educational objective:
Ischemia of the anterior two-thirds of the spinal cord can occur with disruption of the anterior spinal artery blood supply. The resulting anterior cord syndrome causes bilateral distal loss of pain, temperature, and crude touch sensation (from injury to the spinothalamic tracts) and paralysis (from injury to the lateral corticospinal tracts).

References

- Incomplete cord syndromes: clinical and imaging review.
- Spinal cord injury following thoracic and thoracoabdominal repairs.

Anatomy	Nervous System	Spinal cord injury
Subject	System	Topic

Copyright © UWorld. All rights reserved.

A 49-year-old woman comes to the office due to muscle weakness. For the past 3 months, the patient has had worsening weakness in her right hand. She has also been tripping. The patient experiences twitching and cramping in her arms and legs. She has no sensory deficits. On examination, there is increased tone and fasciculations in the lower extremity muscles. Atrophy of the interosseus muscles of the right hand and the bilateral intrinsic muscles of the feet is present. When the physician taps on the chin while the mouth is slightly open, the jaw jerks forward briskly. Which of the following cranial nerves mediate this reflex?

	Afferent	Efferent
A.	Glossopharyngeal	Trigeminal
B.	Glossopharyngeal	Vagus
C.	Trigeminal	Facial
D.	Trigeminal	Trigeminal
E.	Vagus	Vagus

Submit

A 49-year-old woman comes to the office due to muscle weakness. For the past 3 months, the patient has had worsening weakness in her right hand. She has also been tripping. The patient experiences twitching and cramping in her arms and legs. She has no sensory deficits. On examination, there is increased tone and fasciculations in the lower extremity muscles. Atrophy of the interosseus muscles of the right hand and the bilateral intrinsic muscles of the feet is present. When the physician taps on the chin while the mouth is slightly open, the jaw jerks forward briskly. Which of the following cranial nerves mediate this reflex?

	Afferent	Efferent
A. (2%)	Glossopharyngeal	Trigeminal
B. (1%)	Glossopharyngeal	Vagus
C. (28%)	Trigeminal	Facial
✓ D. (67%)	Trigeminal	Trigeminal
E. (0%)	Vagus	Vagus

Omitted
Correct answer
D

67%
Answered correctly

02 secs
Time Spent

02/19/2020
Last Updated

Explanation

Cranial nerve reflexes			
Reflex	**Effect**	**Afferent**	**Efferent**
Pupillary light reflex	Light-induced pupil constriction	II	III
Corneal reflex	Corneal stimulation causing orbicularis oculi to contract eyelids	V1 (ophthalmic branch)	VII
Jaw jerk reflex	Stretch reflex stimulating masseter contraction	V3 (sensory from muscle spindles)	V3
Vestibuloocular reflex	Compensatory eye movements that provide image stabilization when head/body moves	VIII (vestibular component)	III, IV, VI
Carotid sinus reflex	Increased carotid sinus pressure that causes decreased heart rate & blood pressure	IX	X (sympathetic tone also inhibited)
Cough reflex	Cough induced by upper respiratory tract irritation	X	X
Gag reflex	Reflex contraction of pharyngeal constrictor muscles evoked by touching back of throat	IX	X

This patient with findings of both upper (spasticity, increased tone) and lower (atrophy, fasciculations) motor neuron lesions most likely has amyotrophic lateral sclerosis (ALS). Tapping on the chin with the mouth slightly open causes the jaw to briskly close, which represents a positive (ie, pathologic) **jaw jerk reflex**. This reflex is **normally absent** or very weak but is present in patients with bilateral upper motor neuron lesions such as ALS.

The jaw jerk reflex begins with **afferent** signals from muscle spindles of the masseter that are carried along the mandibular division of the **trigeminal nerve** (CN V3) to the trigeminal mesencephalic nucleus, which is involved with reflex proprioception of the muscles of mastication. This center then coordinates with the trigeminal motor nucleus to send motor **(efferent)** signals back along CN V3 to the muscles of mastication.

10
11
12
13
14
15
16
17
18
19
20
21
22
23
24
25
26
27
28
29
30
31
32
33
34
35
36
37
38
39
40

	touching back of throat		

This patient with findings of both upper (spasticity, increased tone) and lower (atrophy, fasciculations) motor neuron lesions most likely has amyotrophic lateral sclerosis (ALS). Tapping on the chin with the mouth slightly open causes the jaw to briskly close, which represents a positive (ie, pathologic) **jaw jerk reflex**. This reflex is **normally absent** or very weak but is present in patients with bilateral upper motor neuron lesions such as ALS.

The jaw jerk reflex begins with **afferent** signals from muscle spindles of the masseter that are carried along the mandibular division of the **trigeminal nerve** (CN V3) to the trigeminal mesencephalic nucleus, which is involved with reflex proprioception of the muscles of mastication. This center then coordinates with the trigeminal motor nucleus to send motor **(efferent)** signals back along CN V3 to the muscles of mastication, causing the jaw to close.

The jaw jerk reflex is the only tendon reflex mediated above the plane of the foramen magnum. Therefore, the pathologic presence of this reflex suggests **bilateral lesions of the upper motor neuron** pathways **above** the level of the **pons** (eg, ALS, multiple sclerosis, pseudobulbar palsy).

(Choices A and B) Sensory fibers of the glossopharyngeal nerve (CN IX) are involved in both the gag and the carotid sinus reflexes. The gag reflex is mediated via afferent information from the glossopharyngeal nerve (CN IX), and efferent information from the vagus nerve (CN X). The carotid sinus reflex is mediated by afferent signals from arterial baroreceptors which are carried to the brainstem by CN IX and CN X; efferent signals are then carried by parasympathetic fibers to the sinoatrial and atrioventricular nodes.

(Choice C) The corneal reflex is mediated by afferent fibers from the ophthalmic division of the trigeminal nerve (CN V1) and efferent fibers of the facial nerve (CN VII) projecting to the orbicularis oculi muscle, causing a blink.

(Choice E) Both the afferent and the efferent limbs of the cough reflex are mediated by the vagus nerve (CN X).

Educational objective:
The jaw jerk reflex is a pathologic cranial nerve reflex present in patients with bilateral upper motor neuron lesions, such as amyotrophic lateral sclerosis. Both the afferent and efferent pathways are mediated by the mandibular division of the trigeminal nerve (CN V3).

References

- The history of examination of reflexes.

This patient with findings of both upper (spasticity, increased tone) and lower (atrophy, fasciculations) motor neuron lesions most likely has

Exhibit Display

Carotid sinus & aortic arch baroreceptors

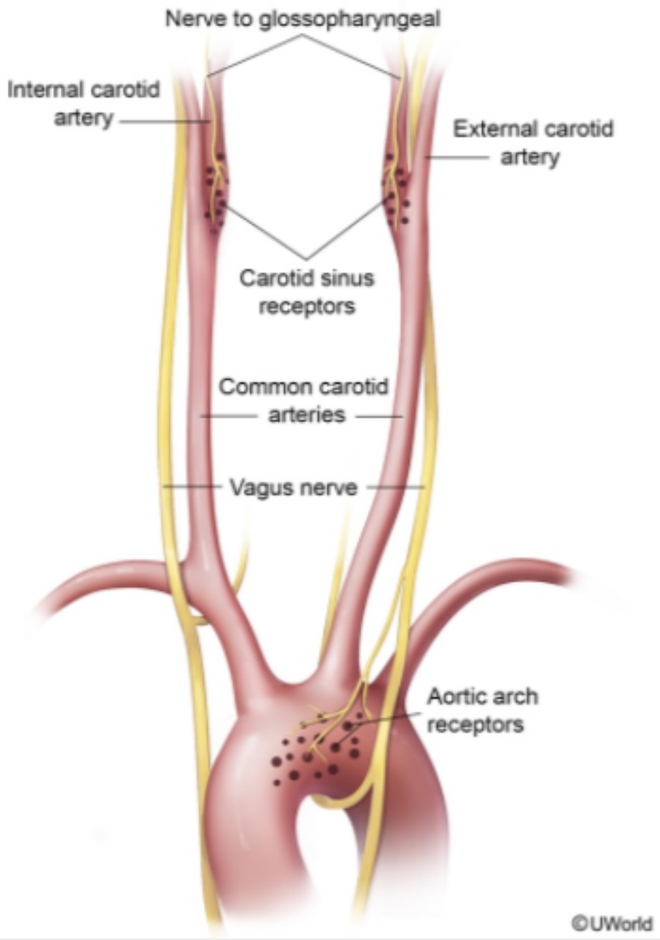

Zoom In Zoom Out Reset Add To Flash Card

Subject System Topic

10 11 12 13 14 15 16 17 18 19 20 21 22 23 24 25 26 27 28 29 30 31 32 33 34 35 36 37 38 39 40

10
11
12
13
14
15
16
17
18
19
20
21
22
23
24
25
26
27
28
29
30
31
32
33
34
35
36
37
38
39
40

A 65-year-old man comes to the emergency department due to sudden-onset headache. The patient has had no recent falls or head trauma. Medical history includes hypertension and lung adenocarcinoma with abdominal metastasis. Initial noncontrast head CT scan reveals a small temporal lobe hemorrhage. Over the next 24 hours, the patient becomes progressively obtunded and develops generalized tonic-clonic seizures. Blood pressure is 190/96 mm Hg, pulse is 38/min, and respirations are 6/min with brief episodes of apnea. A repeat noncontrast head CT scan reveals acute hemorrhage expansion with brain herniation. Which of the following findings is most likely to be observed on this patient's repeat neurologic examination?

A. Dilated pupil
B. Horner syndrome
C. Hyperreflexia
D. Nystagmus
E. Upward gaze palsy

Submit

A 65-year-old man comes to the emergency department due to sudden-onset headache. The patient has had no recent falls or head trauma. Medical history includes hypertension and lung adenocarcinoma with abdominal metastasis. Initial noncontrast head CT scan reveals a small temporal lobe hemorrhage. Over the next 24 hours, the patient becomes progressively obtunded and develops generalized tonic-clonic seizures. Blood pressure is 190/96 mm Hg, pulse is 38/min, and respirations are 6/min with brief episodes of apnea. A repeat noncontrast head CT scan reveals acute hemorrhage expansion with brain herniation. Which of the following findings is most likely to be observed on this patient's repeat neurologic examination?

- ✓ A. Dilated pupil (63%)
- B. Horner syndrome (8%)
- C. Hyperreflexia (12%)
- D. Nystagmus (6%)
- E. Upward gaze palsy (8%)

Omitted
Correct answer
A

63%
Answered correctly

02 secs
Time Spent

01/27/2020
Last Updated

Explanation

Left mesial temporal lobe intracerebral hemorrhage

10
11
12
13
14
15
16
17
18
19
20
21
22
23
24
25
26
27
28
29
30
31
32
33
34
35
36
37
38
39
40

Left mesial temporal lobe intracerebral hemorrhage

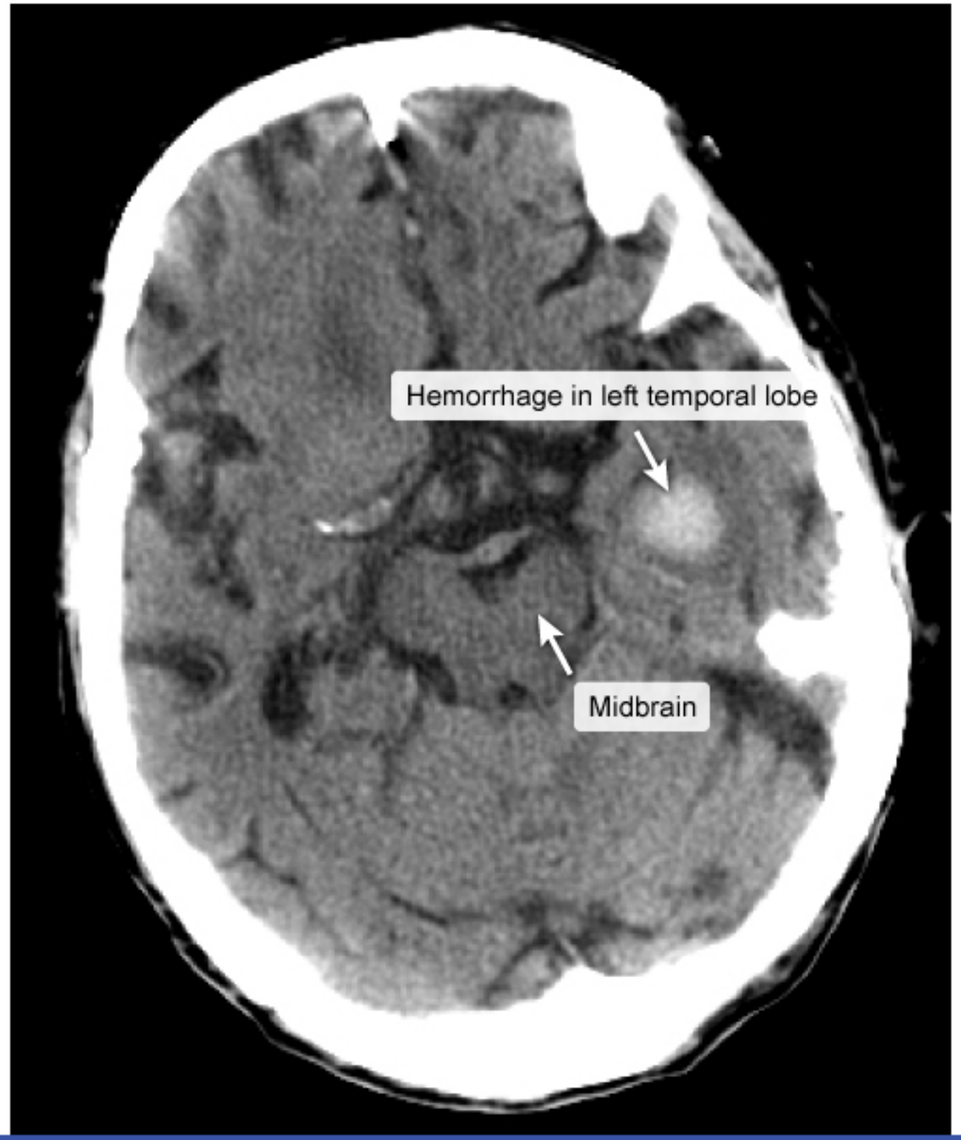

©UWorld

This patient developed a spontaneous **intracerebral hemorrhage** with subsequent clinical deterioration due to ongoing bleeding and hemorrhage expansion. Expanding space-occupying lesions (eg, hemorrhage, hematoma) **increase intracranial pressure**, which can manifest with headache, vomiting, impaired consciousness, and ultimately Cushing triad (eg, hypertension, bradycardia, bradypnea) when brain herniation is imminent.

Herniation can occur at different portions of the brain depending on the location of the initial lesion. Lesions in the temporal lobe tend to cause transtentorial herniation of the uncus, which can compress the ipsilateral oculomotor nerve (CN III) as it exits the midbrain at the same level. Patients often develop ipsilateral **oculomotor nerve palsy** with a fixed **dilated pupil** due to preganglionic parasympathetic nerve fiber damage.

If the intracranial pressure continues to increase, the herniation can progress to involve the uncus bilaterally and ultimately cause downward displacement of the brainstem (ie, central herniation). This results in continued clinical deterioration with irregular breathing (ie, Cheyne-Stokes respiration), abnormal posturing, and either small or mid-fixed pupils depending on the extent of the damage.

(Choice B) Horner syndrome (ie, ptosis, miosis, anhidrosis) is associated with lesions affecting the posterolateral hypothalamus or sympathetic tracts in the brainstem (eg, lateral medulla).

(Choice C) Uncal herniation can compress the cerebral peduncles, resulting in corticospinal tract injury with contralateral hemiparesis. However, patients initially have flaccid paralysis with hyporeflexia (ie, spinal shock); spasticity/hyperreflexia develops days to weeks following acute upper motor neuron injury and would not yet be present in this patient.

(Choice D) Nystagmus is generally seen with lesions to the pons, medulla, or cerebellum due to disruption of vestibular pathways.

(Choice E) Hydrocephalus can cause upward gaze palsy due to dilation of the third ventricle with compression of the dorsal midbrain (eg, superior colliculus, pretectal area).

Educational objective:
Expanding space-occupying lesions can increase intracranial pressure, causing transtentorial herniation of the uncus. Uncal herniation often compresses the ipsilateral oculomotor nerve (CN III) as it exits the midbrain, resulting in oculomotor nerve palsy with a fixed dilated pupil (due to preganglionic parasympathetic nerve fiber damage).

References

©UWorld

Exhibit Display

Types of brain herniations

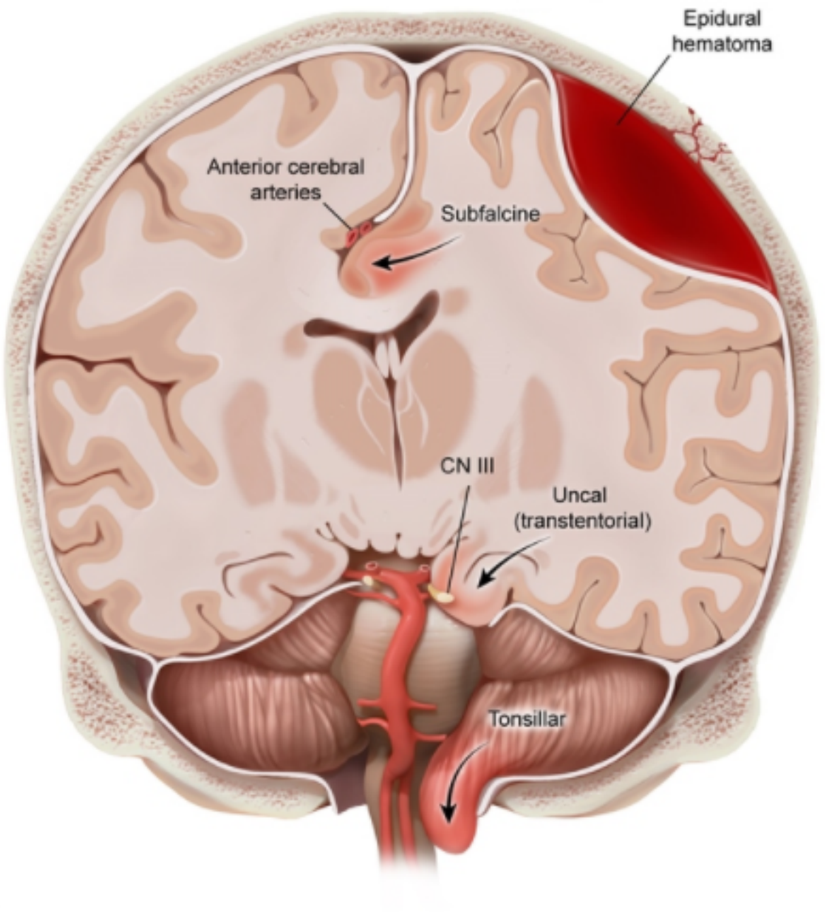

©UWorld

Zoom In | Zoom Out | Reset | Add To New Card | Existing Card

References

10
11
12
13
14
15
16
17
18
19
20
21
22
23
24
25
26
27
28
29
30
31
32
33
34
35
36
37
38
39
40

transtentorial herniation of the uncus, which can compress the ipsilateral oculomotor nerve (CN III) as it exits the midbrain at the same level. Patients often develop ipsilateral **oculomotor nerve palsy** with a fixed **dilated pupil** due to preganglionic parasympathetic nerve fiber damage.

If the intracranial pressure continues to increase, the herniation can progress to involve the uncus bilaterally and ultimately cause downward displacement of the brainstem (ie, central herniation). This results in continued clinical deterioration with irregular breathing (ie, Cheyne-Stokes respiration), abnormal posturing, and either small or mid-fixed pupils depending on the extent of the damage.

(Choice B) Horner syndrome (ie, ptosis, miosis, anhidrosis) is associated with lesions affecting the posterolateral hypothalamus or sympathetic tracts in the brainstem (eg, lateral medulla).

(Choice C) Uncal herniation can compress the cerebral peduncles, resulting in corticospinal tract injury with contralateral hemiparesis. However, patients initially have flaccid paralysis with hyporeflexia (ie, spinal shock); spasticity/hyperreflexia develops days to weeks following acute upper motor neuron injury and would not yet be present in this patient.

(Choice D) Nystagmus is generally seen with lesions to the pons, medulla, or cerebellum due to disruption of vestibular pathways.

(Choice E) Hydrocephalus can cause upward gaze palsy due to dilation of the third ventricle with compression of the dorsal midbrain (eg, superior colliculus, pretectal area).

Educational objective:
Expanding space-occupying lesions can increase intracranial pressure, causing transtentorial herniation of the uncus. Uncal herniation often compresses the ipsilateral oculomotor nerve (CN III) as it exits the midbrain, resulting in oculomotor nerve palsy with a fixed dilated pupil (due to preganglionic parasympathetic nerve fiber damage).

References

- Isolated oculomotor nerve palsy: an unusual presentation of temporal lobe tumor.

Anatomy	Nervous System	Brain herniation
Subject	System	Topic

Copyright © UWorld. All rights reserved.

10
11
12
13
14
15
16
17
18
19
20
21
22
23
24
25
26
27
28
29
30
31
32
33
34
35
36
37
38
39
40

A 34-year-old man is evaluated in the clinic due to persistent buzzing in his right ear for the past 6 months. The patient also has decreased hearing on the right side. He has had no fever, ear pain, runny nose, sore throat, or cough. The patient does not use cotton swabs and has not been exposed to loud noise. He tried using over-the-counter oral pseudoephedrine with no improvement in his symptoms. On physical examination, there is no sinus tenderness, and mucous membranes are moist without erythema or exudate. Otoscopic examination reveals normal-appearing external auditory canals bilaterally with pinkish-grey tympanic membranes. MRI of the brain reveals an intracranial tumor. This patient's lesion has most likely arisen from which of the following structures?

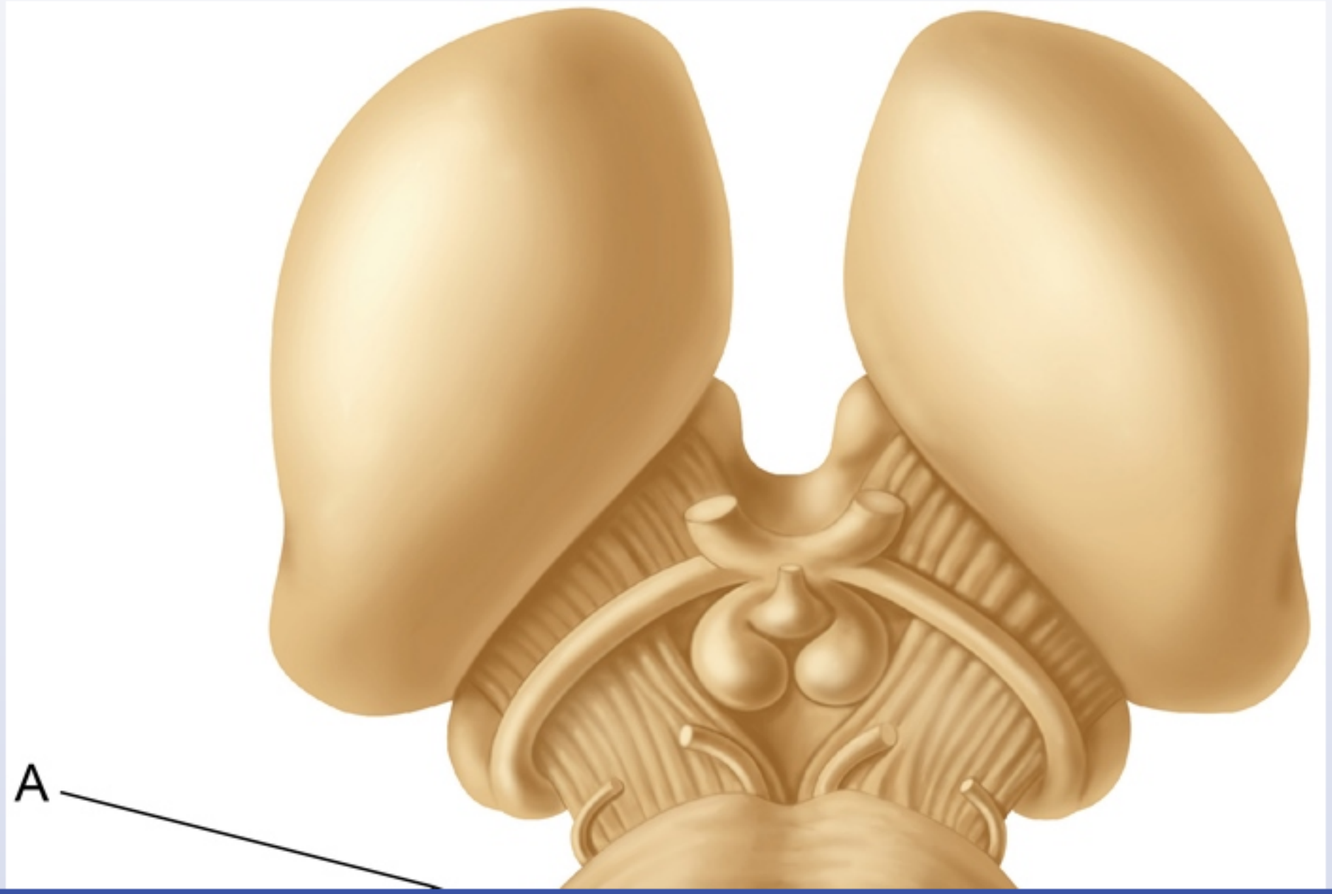

10
11
12
13
14
15
16
17
18
19
20
21
22
23
24
25
26
27
28
29
30
31
32
33
34
35
36
37
38
39
40

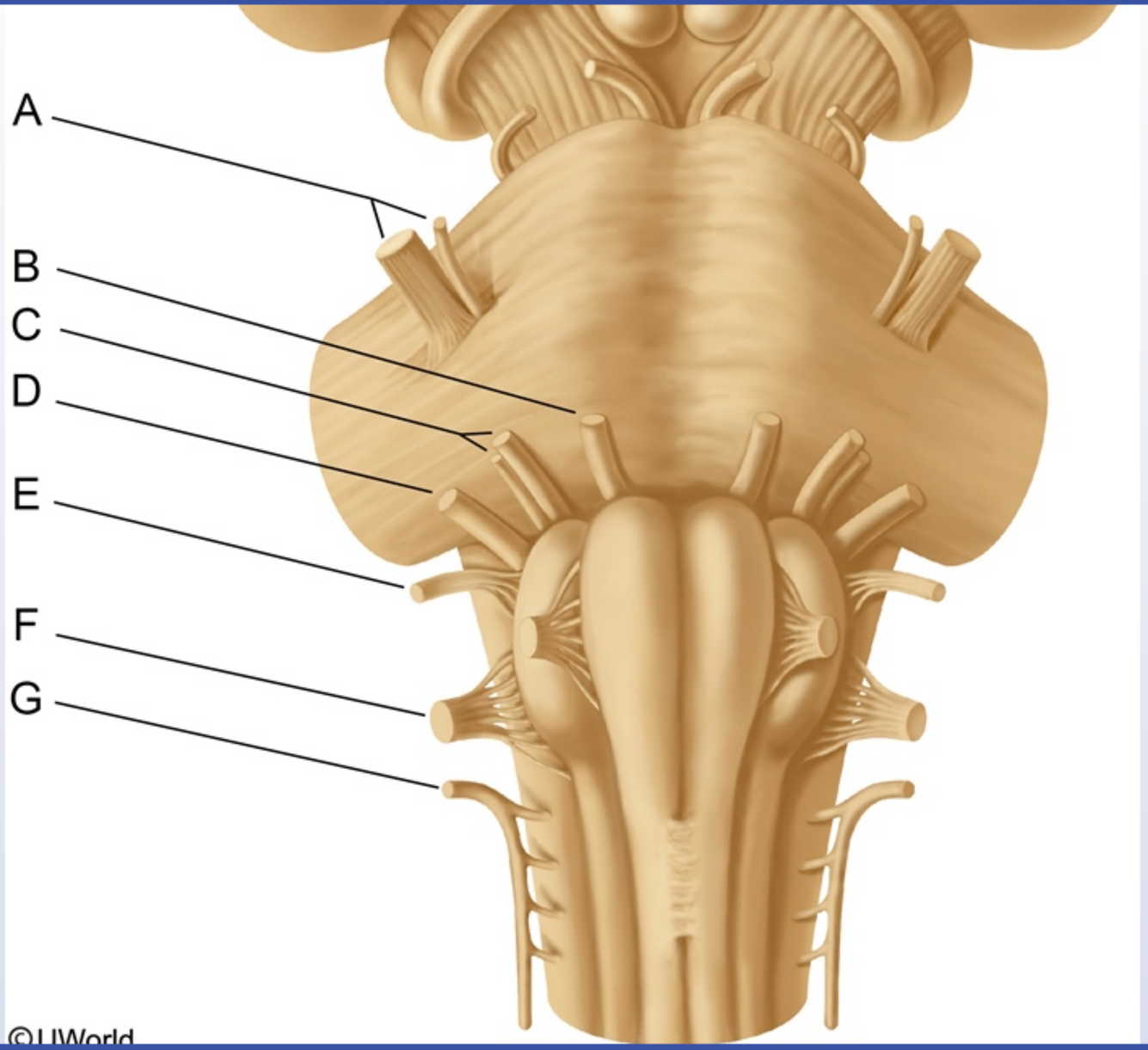

10
11
12
13
14
15
16
17
18
19
20
21
22
23
24
25
26
27
28
29
30
31
32
33
34
35
36
37
38
39
40

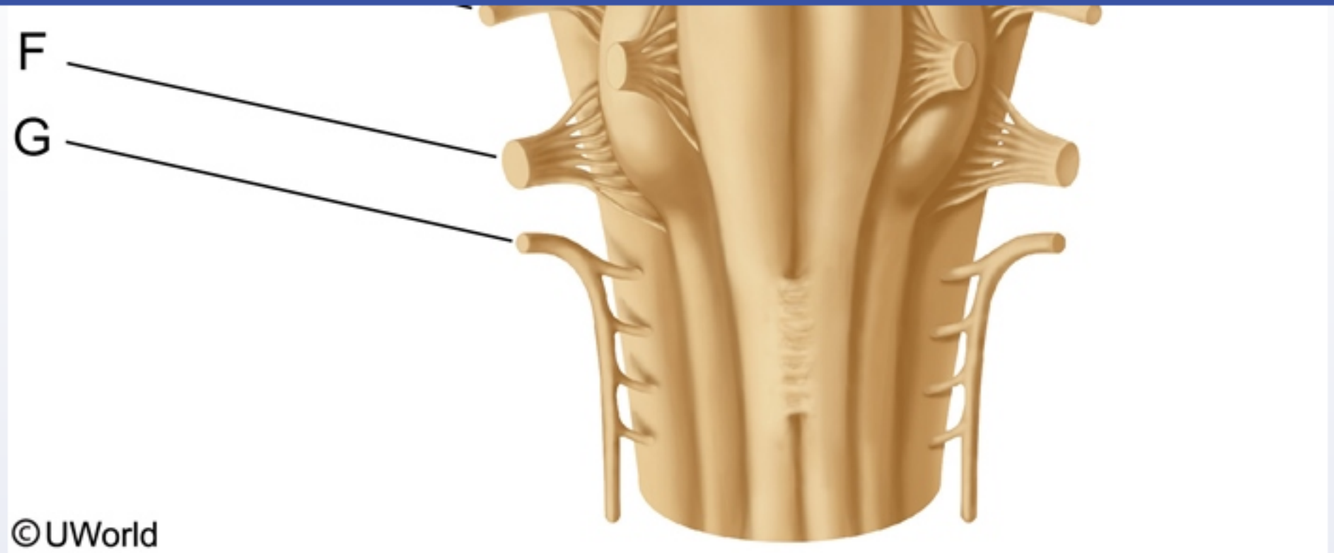

A. A
B. B
C. C
D. D
E. E
F. F
G. G

Submit

10
11
12
13
14
15
16
17
18
19
20
21
22
23
24
25
26
27
28
29
30
31
32
33
34
35
36
37
38
39
40

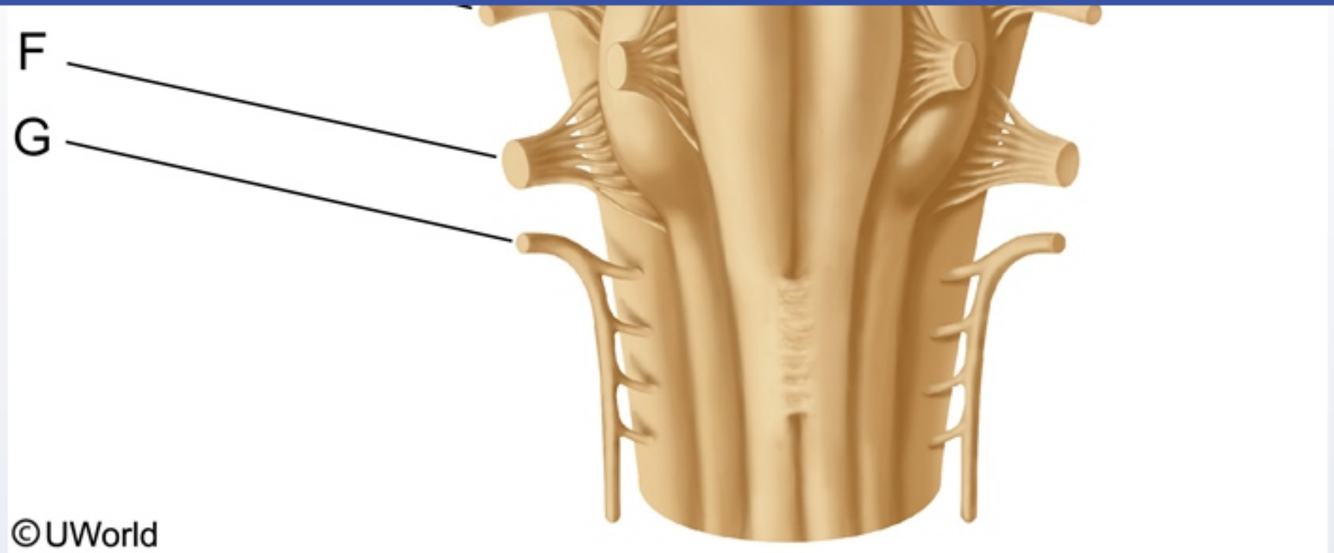

A. A (3%)
B. B (2%)
C. C (19%)
✓ D. D (62%)
E. E (9%)
F. F (2%)
G. G (0%)

Omitted
Correct answer

62%
Answered correctly

08 secs
Time Spent

02/18/2020
Last Updated

10
11
12
13
14
15
16
17
18
19
20
21
22
23
24
25
26
27
28
29
30
31
32
33
34
35
36
37
38
39
40

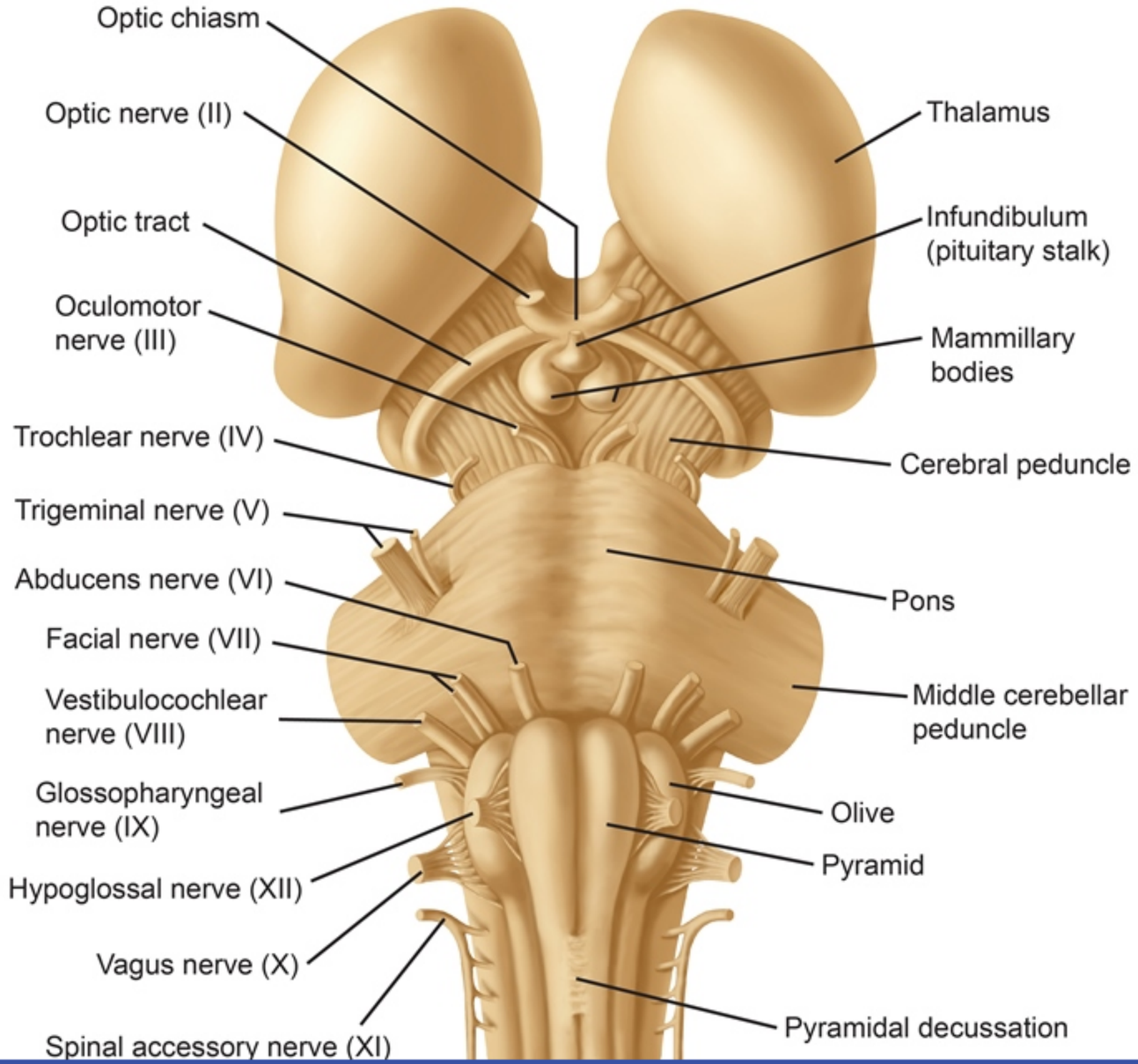

This patient's clinical presentation is suggestive of **acoustic neuroma**, a Schwann cell-derived tumor that typically arises from the vestibular portion of the **vestibulocochlear nerve** (CN VIII). The vestibulocochlear nerve exits the brainstem from the pontomedullary junction, lateral to the facial nerve, and enters the cerebellopontine angle (between the cerebellum and lateral pons). Patients with acoustic neuroma usually have ipsilateral sensorineural **hearing loss** and **tinnitus** (ear ringing/buzzing) due to impairment of the cochlear portion of the nerve. Damage to the vestibular component may also result in vertigo, dysequilibrium, and nystagmus. Most cases present unilaterally, but bilateral acoustic neuromas are frequently seen in patients with neurofibromatosis type 2.

(Choice A) The trigeminal nerve (CN V) exits the brainstem from the ventrolateral pons. Injury to CN V may cause ipsilateral loss of facial sensation and the corneal reflex (afferent limb) and paralysis of the muscles of mastication.

(Choice B) The abducens nerve (CN VI) exits the brainstem from the pontomedullary junction medial to the facial nerve. Injury to CN VI may result in the inability to abduct the ipsilateral eye and horizontal diplopia (lack of innervation to the lateral rectus).

(Choice C) The facial nerve (CN VII) exits the brainstem from the ventrolateral pontomedullary junction, just lateral to the abducens nerve. Damage to CN VII may result in ipsilateral facial muscle paralysis (upper and lower), loss of the corneal reflex (efferent limb), loss of taste in the anterior two-thirds of the tongue, and hyperacusis (lack of innervation to the stapedius).

(Choice E) The glossopharyngeal nerve (CN IX) exits the brainstem from the postolivary sulcus in the medulla just rostral to the vagus nerve. Injury to CN IX may result in loss of taste/sensation in the posterior one-third of the tongue and absent gag reflex (afferent limb).

(Choice F) The vagus nerve (CN X) exits the brainstem from the postolivary sulcus just caudal to the glossopharyngeal nerve. Damage to CN X may cause dysphonia (lack of innervation to the laryngeal muscles), impaired swallowing with inability to elevate the soft palate (lack of innervation to the pharyngeal muscles), and loss of the gag reflex (efferent limb).

(Choice G) Fibers of the spinal accessory nerve (CN XI) exit from the lateral medulla and upper segments of the cervical spinal cord. Injury to CN XI can cause weakness on head rotation away from the side of the lesion (lack of innervation to the sternocleidomastoid) and ipsilateral shoulder droop (lack of innervation to the trapezius).

Educational objective:
Acoustic neuromas are Schwann cell-derived tumors that typically arise from the vestibular portion of the vestibulocochlear nerve and are commonly located at the cerebellopontine angle (between the cerebellum and lateral pons). Patients usually present with unilateral

result in the inability to abduct the ipsilateral eye and horizontal diplopia (lack of innervation to the lateral rectus).

(Choice C) The facial nerve (CN VII) exits the brainstem from the ventrolateral pontomedullary junction, just lateral to the abducens nerve. Damage to CN VII may result in ipsilateral facial muscle paralysis (upper and lower), loss of the corneal reflex (efferent limb), loss of taste in the anterior two-thirds of the tongue, and hyperacusis (lack of innervation to the stapedius).

(Choice E) The glossopharyngeal nerve (CN IX) exits the brainstem from the postolivary sulcus in the medulla just rostral to the vagus nerve. Injury to CN IX may result in loss of taste/sensation in the posterior one-third of the tongue and absent gag reflex (afferent limb).

(Choice F) The vagus nerve (CN X) exits the brainstem from the postolivary sulcus just caudal to the glossopharyngeal nerve. Damage to CN X may cause dysphonia (lack of innervation to the laryngeal muscles), impaired swallowing with inability to elevate the soft palate (lack of innervation to the pharyngeal muscles), and loss of the gag reflex (efferent limb).

(Choice G) Fibers of the spinal accessory nerve (CN XI) exit from the lateral medulla and upper segments of the cervical spinal cord. Injury to CN XI can cause weakness on head rotation away from the side of the lesion (lack of innervation to the sternocleidomastoid) and ipsilateral shoulder droop (lack of innervation to the trapezius).

Educational objective:
Acoustic neuromas are Schwann cell-derived tumors that typically arise from the vestibular portion of the vestibulocochlear nerve and are commonly located at the cerebellopontine angle (between the cerebellum and lateral pons). Patients usually present with unilateral **sensorineural hearing loss** and **tinnitus.**

References

- Management of sporadic vestibular schwannoma.
- Otologic manifestations of acoustic neuroma.

Anatomy	Nervous System	Vestibular schwannoma
Subject	System	Topic

Copyright © UWorld. All rights reserved.

10
11
12
13
14
15
16
17
18
19
20
21
22
23
24
25
26
27
28
29
30
31
32
33
34
35
36
37
38
39
40

Exhibit Display

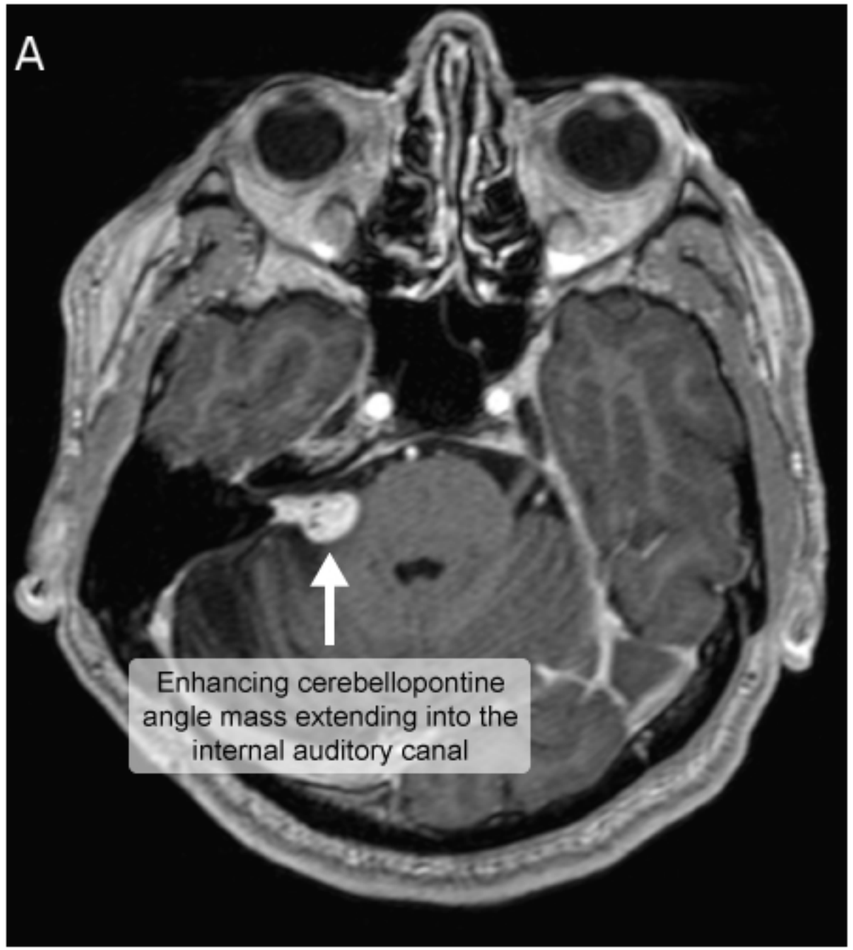

Zoom In | Zoom Out | Reset | Add To New Card | Existing Card

shoulder droop (lack of innervation to the trapezius).

10
11
12
13
14
15
16
17
18
19
20
21
22
23
24
25
26
27
28
29
30
31
32
33
34
35
36
37
38
39
40

A 67-year-old woman with a known history of lung cancer comes to the office due to hoarseness and difficulty swallowing. She has no disturbances in vision or hearing. On examination, there is loss of the gag reflex on the left side; when the patient is prompted to say "ah," the uvula deviates to the right side. Her left shoulder is drooped and strength is reduced during left shoulder shrug testing. Chest x-ray shows a right lower lobe lung mass and several osteolytic rib lesions. MRI of the head also demonstrates multiple lesions consistent with metastasis. A lesion involving which of the following anatomical structures is most likely responsible for this patient's symptoms?

- A. Cerebellopontine angle
- B. Foramen magnum
- C. Foramen ovale
- D. Foramen rotundum
- E. Hypoglossal canal
- F. Jugular foramen

Submit

A 67-year-old woman with a known history of lung cancer comes to the office due to hoarseness and difficulty swallowing. She has no disturbances in vision or hearing. On examination, there is loss of the gag reflex on the left side; when the patient is prompted to say "ah," the uvula deviates to the right side. Her left shoulder is drooped and strength is reduced during left shoulder shrug testing. Chest x-ray shows a right lower lobe lung mass and several osteolytic rib lesions. MRI of the head also demonstrates multiple lesions consistent with metastasis. A lesion involving which of the following anatomical structures is most likely responsible for this patient's symptoms?

- A. Cerebellopontine angle (4%)
- B. Foramen magnum (11%)
- C. Foramen ovale (2%)
- D. Foramen rotundum (2%)
- E. Hypoglossal canal (8%)
- ✓ F. Jugular foramen (69%)

Omitted
Correct answer
F

69%
Answered correctly

02 secs
Time Spent

04/27/2020
Last Updated

Explanation

	Skull foramen	Traversing structures
Anterior		

	Skull foramen	Traversing structures
Anterior cranial fossa	Cribriform plate	CN I olfactory bundles
Middle cranial fossa	Optic canal	CN II, ophthalmic artery, central retinal vein
	Superior orbital fissure	CN III, IV, V_1, VI, ophthalmic vein, sympathetic fibers
	Foramen rotundum	CN V_2 (maxillary)
	Foramen ovale	CN V_3 (mandibular)
	Foramen spinosum	Middle meningeal artery & vein
Posterior cranial fossa	Internal acoustic meatus	CN VII, VIII
	Jugular foramen	CN IX, X, XI, jugular vein
	Hypoglossal canal	CN XII
	Foramen magnum	Spinal roots of CN XI, brain stem, vertebral arteries

CN = cranial nerve.

10
11
12
13
14
15
16
17
18
19
20
21
22
23
24
25
26
27
28
29
30
31
32
33
34
35
36
37
38
39
40

		vertebral arteries

CN = cranial nerve.

©UWorld

This patient's symptoms are consistent with a lesion involving the jugular foramen , a large aperture located in the base of the skull behind the carotid canal. It is formed by the petrous portion of the temporal bone and the occipital bone. Passing through the jugular foramen are cranial nerves (CN) IX, X, and XI. Lesions of the jugular foramen (eg, due to tumors, trauma, or infection) can result in **jugular foramen (Vernet) syndrome**, which is characterized by **CN IX**, **X**, and **XI dysfunction**. Symptoms are related to the nerve affected:

- Loss of taste from the posterior 1/3 of the tongue (CN IX)
- Loss of gag reflex (CN IX, X)
- Dysphagia (CN IX, X)
- Dysphonia/hoarseness (CN X)
- Soft palate drop with deviation of the uvula toward the normal side (CN X)
- Sternocleidomastoid and trapezius muscle paresis (CN XI)

(Choice A) Lesions at the cerebellopontine angle (eg, vestibular schwannoma) typically cause sensorineural hearing loss and tinnitus due to dysfunction of CN VIII.

Educational objective:
Lesions of the jugular foramen can result in jugular foramen (Vernet) syndrome, which is characterized by the dysfunction of cranial nerves IX, X, and XI. Symptoms include dysphagia, hoarseness, loss of gag reflex on the ipsilateral side, and deviation of the uvula toward the normal side.

References

- Jugular foramen syndrome as initial presentation of metastatic lung cancer.

Anatomy	Nervous System	Cranial nerve palsy
Subject	System	Topic

Copyright © UWorld. All rights reserved.

vertebral arteries

Exhibit Display

Foramina of the cranial base

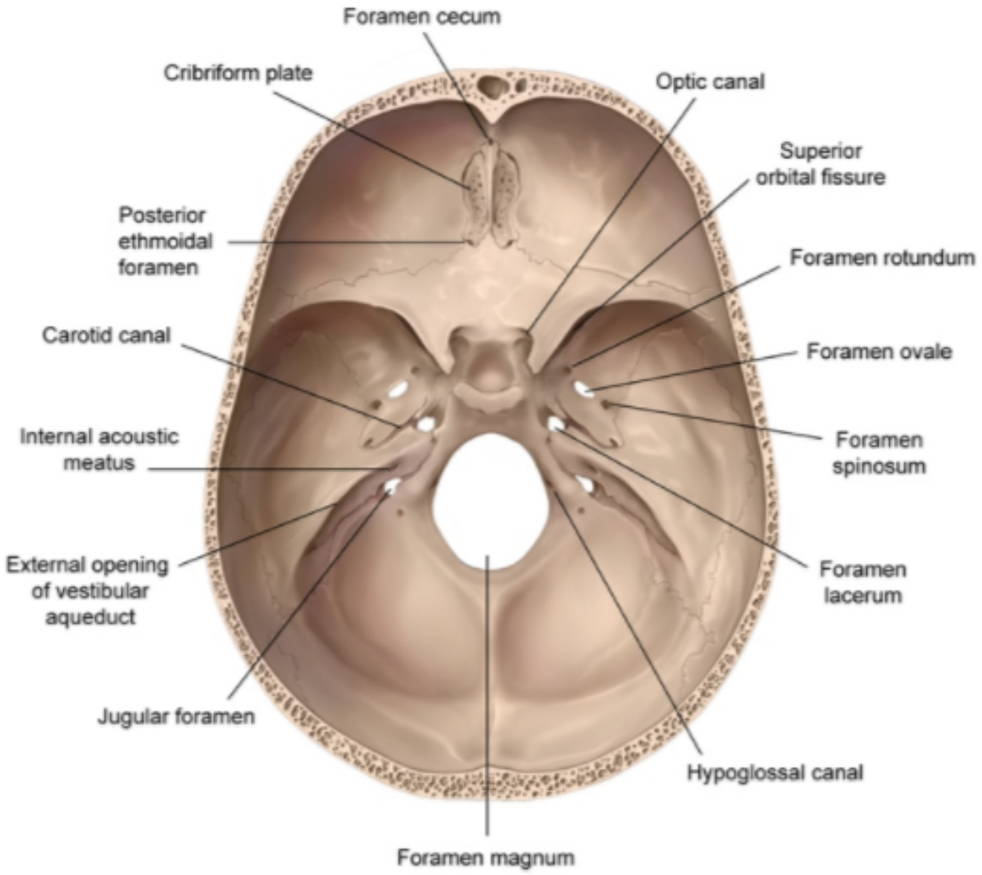

©UWorld

Zoom In | Zoom Out | Reset | Add To New Card | Existing Card

A 65-year-old man is brought to the emergency department after he suddenly became unresponsive at home. On arrival, paramedics found him pulseless with ventricular fibrillation. After 10 minutes of cardiopulmonary resuscitation, the patient regains spontaneous circulation. In the hospital, he is intubated and placed on mechanical ventilation. His vitals remain stable. A therapeutic hypothermia protocol is initiated. After 72 hours following rewarming, he remains comatose with fixed and dilated pupils. There is no direct or consensual pupillary response to light. MRI of the brain reveals diffuse loss of grey-white matter differentiation with sulcal effacement. Damage to which of the following areas of the brain is the most likely cause of this patient's pupillary findings?

- A. Medulla
- B. Midbrain
- C. Occipital lobe
- D. Parietal lobe
- E. Pons
- F. Temporal lobe
- G. Thalamus

Submit

A 65-year-old man is brought to the emergency department after he suddenly became unresponsive at home. On arrival, paramedics found him pulseless with ventricular fibrillation. After 10 minutes of cardiopulmonary resuscitation, the patient regains spontaneous circulation. In the hospital, he is intubated and placed on mechanical ventilation. His vitals remain stable. A therapeutic hypothermia protocol is initiated. After 72 hours following rewarming, he remains comatose with fixed and dilated pupils. There is no direct or consensual pupillary response to light. MRI of the brain reveals diffuse loss of grey-white matter differentiation with sulcal effacement. Damage to which of the following areas of the brain is the most likely cause of this patient's pupillary findings?

- A. Medulla (5%)
- ✓ B. Midbrain (58%)
- C. Occipital lobe (12%)
- D. Parietal lobe (1%)
- E. Pons (14%)
- F. Temporal lobe (3%)
- G. Thalamus (3%)

Omitted
Correct answer
B

58%
Answered correctly

02 secs
Time Spent

07/05/2020
Last Updated

Explanation

Pupillary light reflex

10
11
12
13
14
15
16
17
18
19
20
21
22
23
24
25
26
27
28
29
30
31
32
33
34
35
36
37
38
39
40

Pupillary light reflex

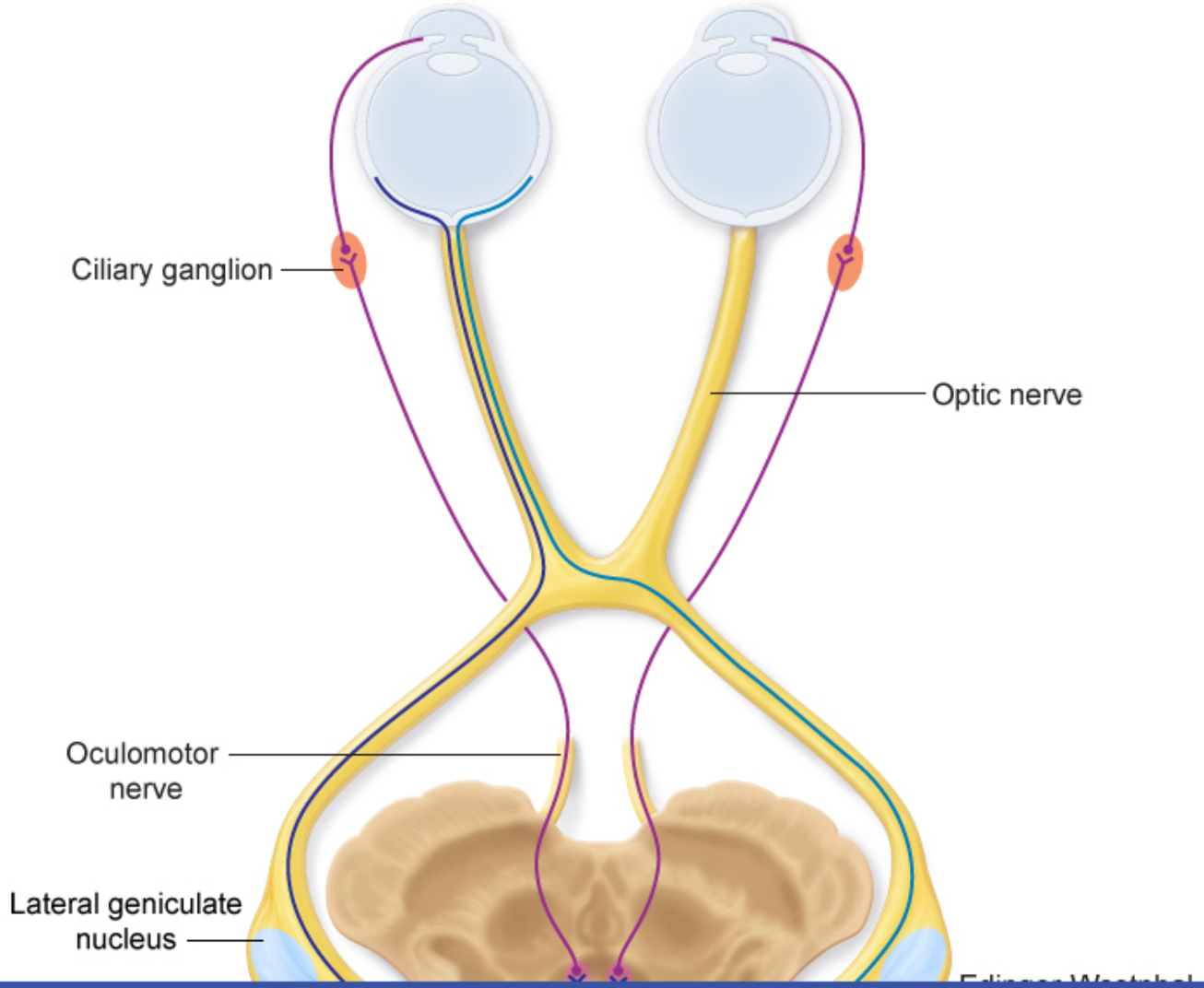

10
11
12
13
14
15
16
17
18
19
20
21
22
23
24
25
26
27
28
29
30
31
32
33
34
35
36
37
38
39
40

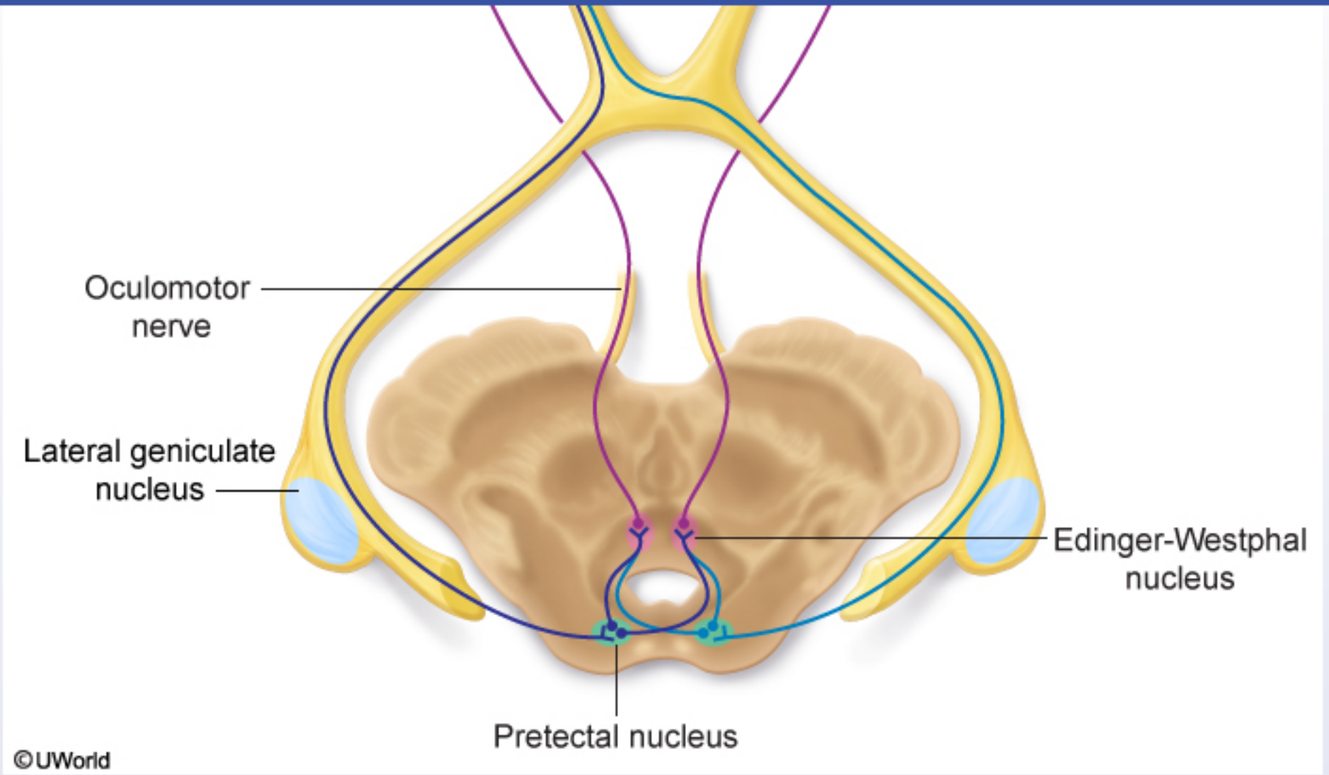

This patient's presentation and MRI findings (eg, loss of grey-white matter differentiation with sulcal effacement) are consistent with anoxic brain injury due to cardiac arrest. The presence of nonreactive pupils to light stimulation following cardiac arrest carries a poor prognosis and indicates anoxic damage to the brainstem at the level of the **upper midbrain**.

During the normal **pupillary reflex**, the retina as well as the **optic nerve** and tract transmit the light stimulus to the midbrain at the level of the superior colliculus where it is received by the **pretectal nucleus** and subsequently relayed to the bilateral **Edinger-Westphal nuclei**. These nuclei subsequently project preganglionic parasympathetic fibers through the **oculomotor nerve** (CN III) to the ciliary ganglion, which then projects postganglionic fibers that innervate the sphincter pupillae muscle (constricts the pupil). When light is shone in one eye, both the ipsilateral pupil (direct response) and contralateral pupil (consensual response) constrict.

(Choice A) The medulla contains the glossopharyngeal (CN IX) and vagus (CN X) nerves, which provide the afferent and efferent limbs of the

pupil (direct response) and contralateral pupil (consensual response) constrict.

(Choice A) The medulla contains the glossopharyngeal (CN IX) and vagus (CN X) nerves, which provide the afferent and efferent limbs of the gag reflex, respectively.

(Choice C) The occipital lobe contains the primary visual cortex. Unilateral occipital lobe damage can cause contralateral homonymous hemianopia, whereas bilateral occipital lesions may result in cortical blindness.

(Choice D) The parietal lobes process and interpret visual, auditory, and motor signals received from other brain areas. Parietal lobe damage results in difficulties with spatial and visual perception. Nondominant (eg, right-sided) lesions result in hemi-neglect and constructional apraxia, whereas dominant (eg, left-sided) lesions result in Gerstmann syndrome (eg, right-left confusion, agraphia, acalculia).

(Choice E) The pons contains the horizontal gaze center, which helps mediate the oculocephalic (doll's eye) reflex. It also contains the trigeminal (CN V) and facial (CN VII) nerves, which mediate the afferent and efferent limb of the corneal reflex, respectively. Bilateral pontine injury is associated with pinpoint pupils due to damage of the descending sympathetic fibers.

(Choice F) Temporal lobe injury can cause disturbances in memory (eg, hippocampus), speech (eg, Wernicke area in dominant hemisphere), vision (eg, Meyer loop), and hearing (eg, primary auditory cortex). Bilateral damage to the amygdala results in Klüver-Bucy syndrome (eg, hyperphagia, hyperorality, hypersexuality).

(Choice G) The thalamus is a major sensory relay station. The ventral posterolateral nucleus mediates somatic sensation of the body, the ventral posteromedial nucleus mediates facial sensation and taste, the lateral geniculate nucleus mediates vision, and the medial geniculate nucleus mediates hearing.

Educational objective:
The upper midbrain contains neural structures (eg, optic nerve, pretectal nuclei, Edinger-Westphal nuclei, oculomotor nerve) that mediate the direct and consensual pupillary light reflex.

References

- The pupils.

Anatomy	Nervous System	Anoxic brain injury
Subject	System	Topic